

# Neurosurgery in Cushing's disease: indications, modalities, evaluation of results

***Prof. Diego Mazzatenta***


Director

Pituitary Unit and Center of endoscopic skull base surgery

IRCCS Institute of Neurological Sciences of Bologna

Department of Biomedical and Neuromotor Sciences


University of Bologna



# Background

- **Rare**
- **Severe**
- **Impacting on patient QoL,**
- **Complications: infectious, cardiovascular complications, hypertension, myocardial infarction and thromboembolism**
- **Mortality**
- ***Gold of treatment:***
  - *normalizing cortisol levels,*
  - *reversing/reducing clinical features and comorbidities;*
  - *preserving pituitary function*
  - *avoiding recurrences*
- **Multidisciplinary and experienced team**

Biller et al. *JCEM* 2008; 93:2454:2462 - Nieman et al. *JCEM* 2015; 100(8):2807-2831



# Clinical history: C.G. man, 57 years old

- Bilateral iliac stenting
  - PTA coronaric
  - Depression and anxiety in the past two years
  - Smoker
  - Body weight 90Kg
- 
- July 2016: posterior MI → drug eluting stent in CDx → double antiplatelet therapy
  - Edema of lower limbs
  - DM tipe II (in therapy with: fast-acting insulin 14UI+25UI+25UI; long-acting insulin Lantus 20UI+48UI)
  - Dyslipidemia
  - Hypokalaemia
  - HBP unresponsive to triple antihypertensive drug therapy
  - Worsening back pain → MRI: D7 pathological fracture
  - Moon face, truncal obesity, hirsutism, muscle atrophy, teleangectasia, purple striae

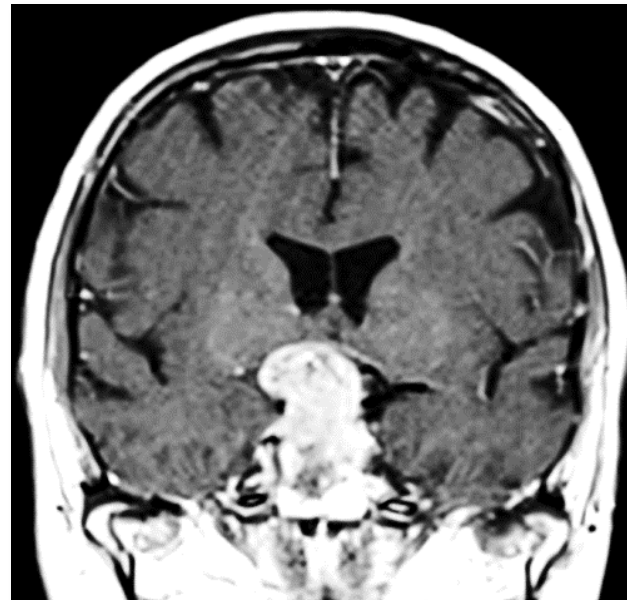
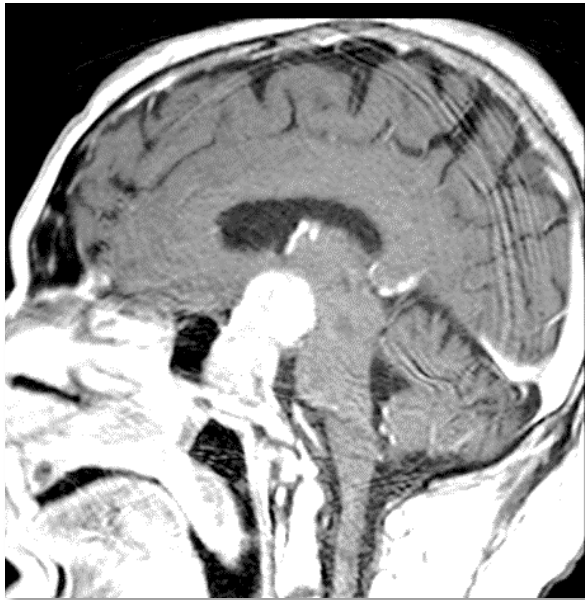# Clinical history


## LABORATORY EXAMS:

- P-Cortisol 409 ng/ml
- ACTH 376 pg/ml
- U-Cortisol 1480 mcg/24 h

## RMN:

- Pituitary macroadenoma with suprasellar extension and third ventricle compression
- Knosp 3B → invasion of inferior part of cavernous sinus





# Clinical history:

## Admitted in Pituitary Unit 28.10.16

**ANESTHESIOLOGICAL COUNSELING:** painkiller therapy due to back pain →  
Durogesic 50 mcg

**ENDOCRINOLOGICAL COUNSELING:** drug therapy with Metyrapone 250 mg x 3 →  
after 10 days improved glycemic control and normalization of serum cortisol (203 ng/ml)

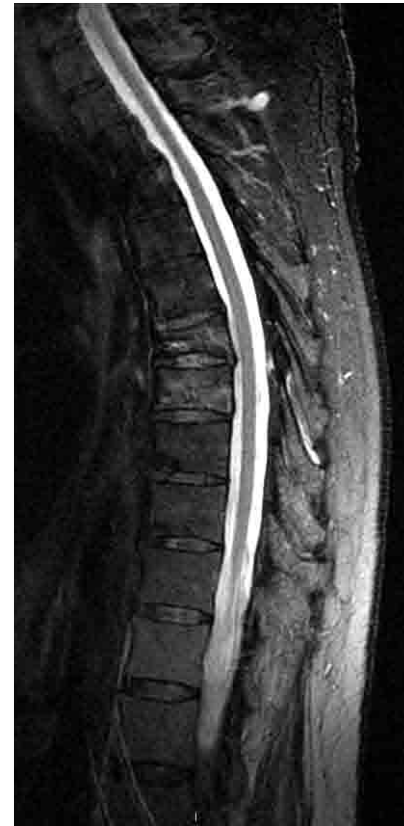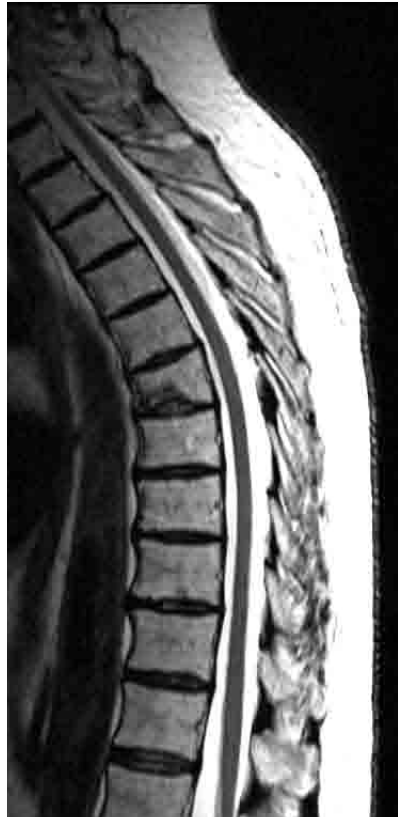**CARDIOLOGIC COUNSELING:** surgical treatment need to suspend ASA and  
Clopidogrel (Plavix): high risk for intracoronary stent thrombosis; advice of procrastinating  
surgical treatment. **High cardiological risk**

**PNEUMOLOGICAL COUNSELING + PFT:** mixed obstructive and restrictive deficit;  
COPD stage II; medium-high surgical risk, with probable hard weanign.

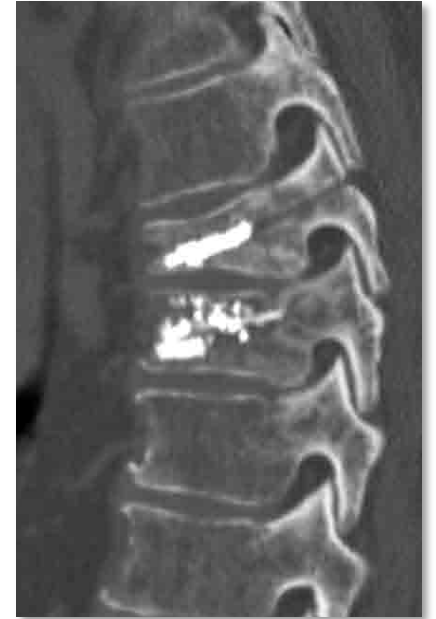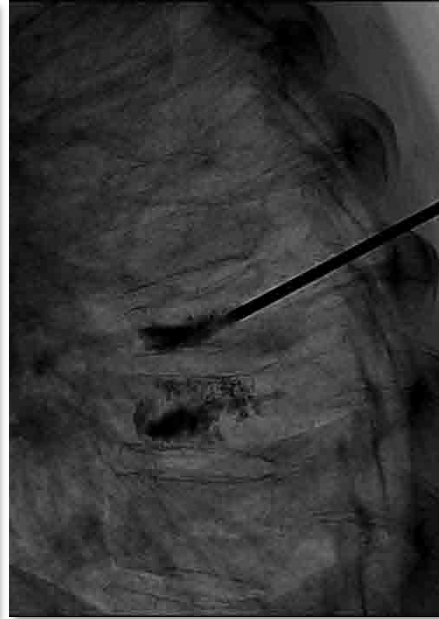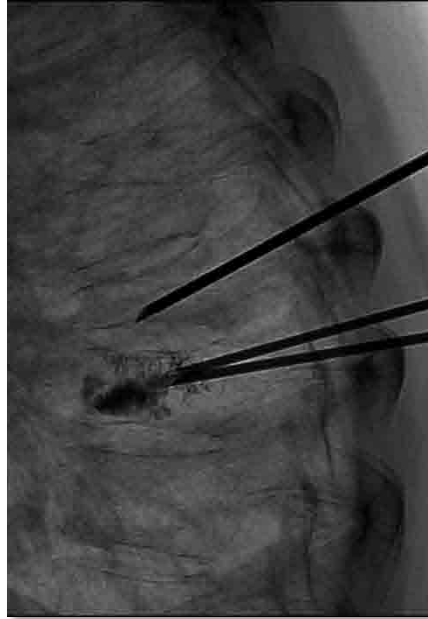
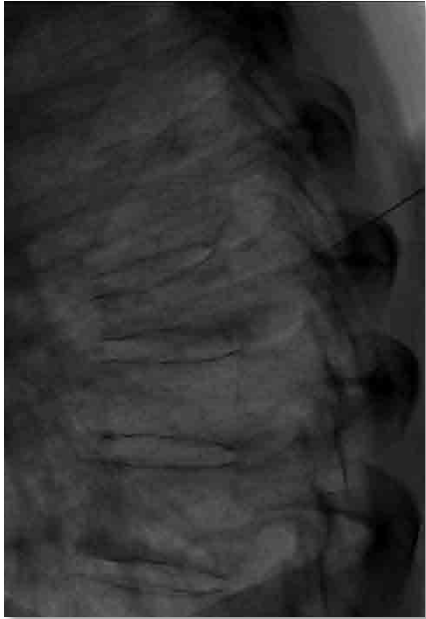# Clinical history

## NEURORADIOLOGICAL COUNSELING:

RM D/L: stable D6 collapse + other progressive collapses

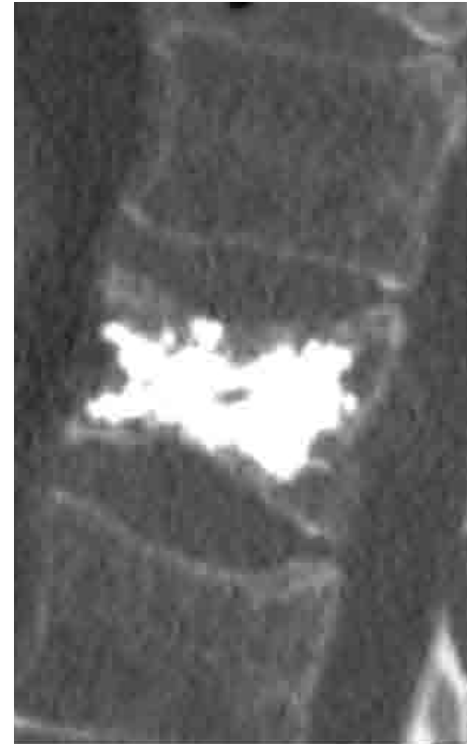
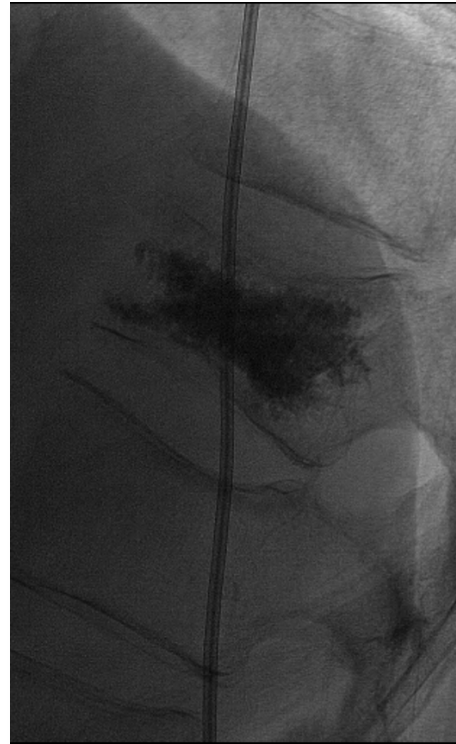
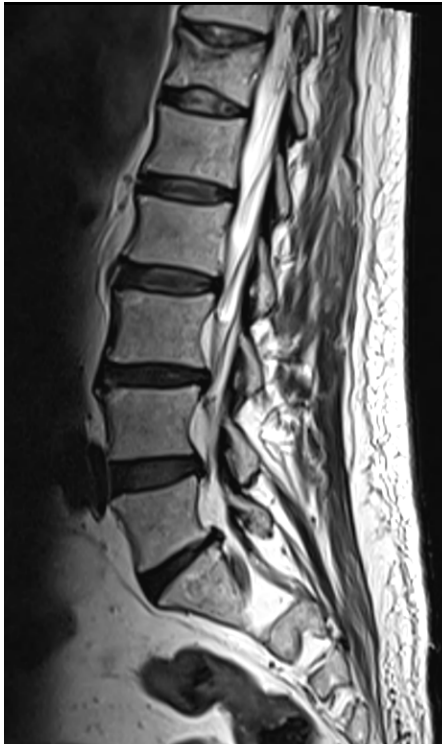

# VERTEBROPLASTY D7-D8 (9/11/16)



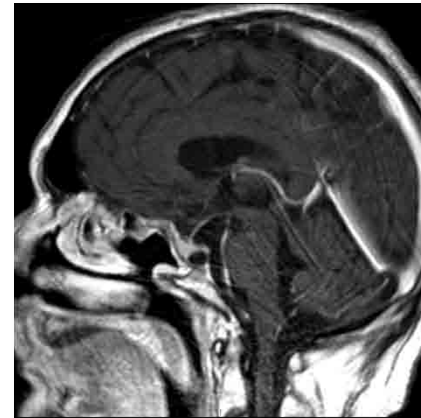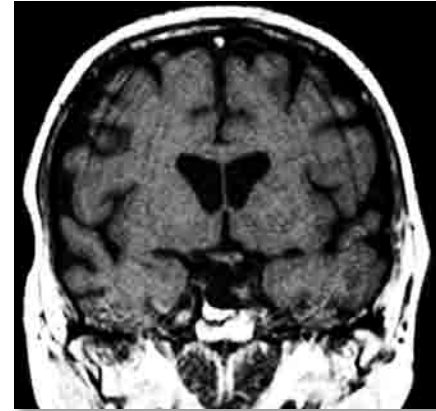
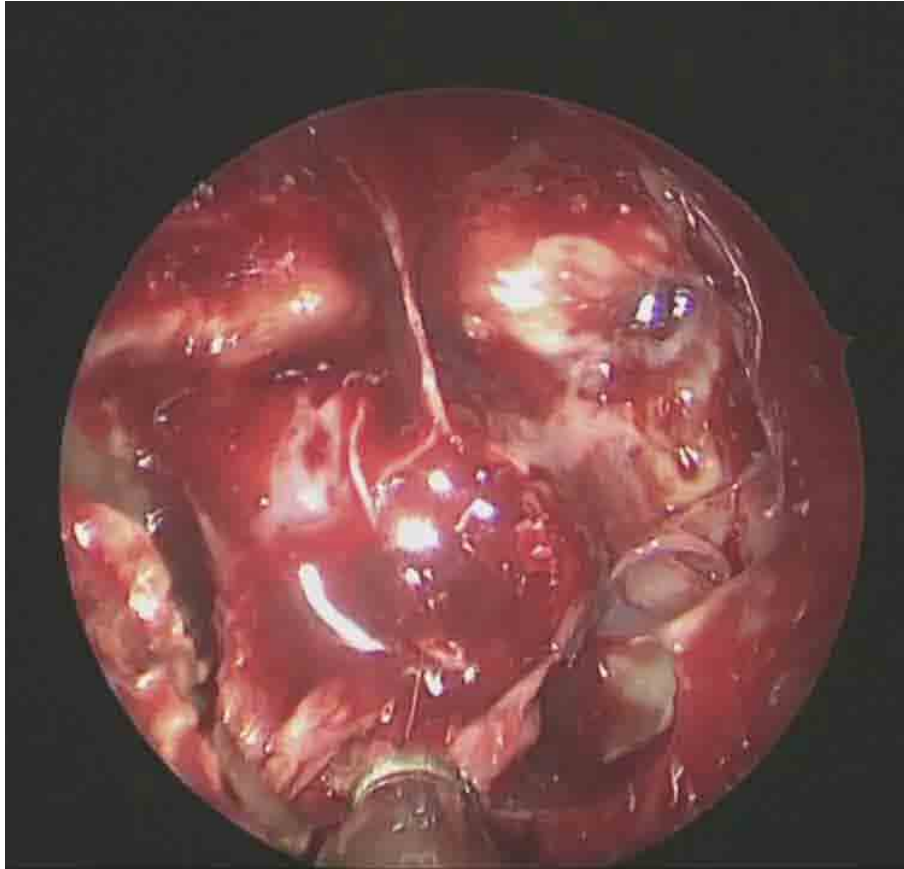
## Clinical history:

- Low back pain not responsive to drug therapy
- RM D/L collapse D12
- Second vertebroplasty

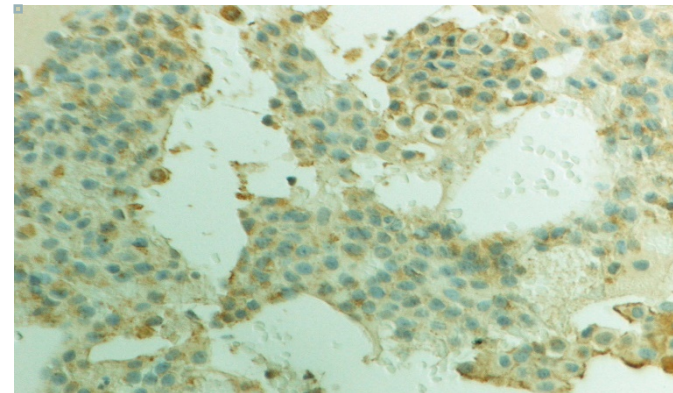
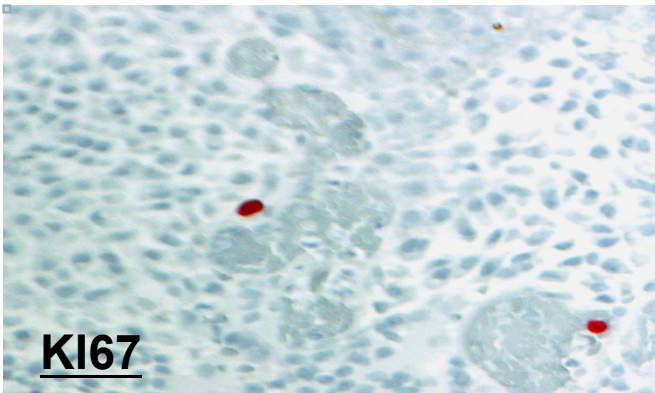
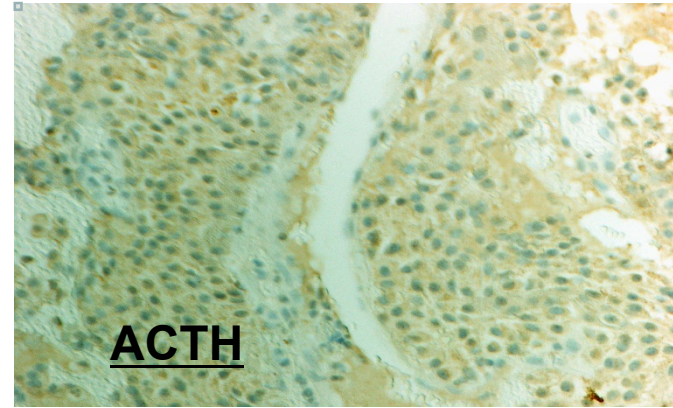
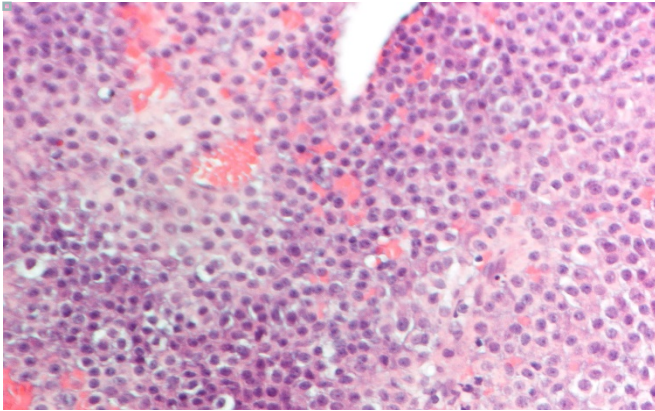





After two weeks  
Surgical procedure (11/11/16)  
Extended endoscopic transphenoidal approach



# Pathology






## POST-OPERATIVE

- 1° postoperative day (RU): P-Cortisol 175 ng/ml ACTH 106 pg/ml
- 5° postoperative day: P-Cortisol <44 ng/ml ACTH 28 pg/ml


Early substitutive therapy

- Surgical complications: none.
- Medical complications: fever, pleural effusion, persistent edema of lower limbs, venous thrombosis:
  - Transferred to internal medicine department, resigned to domicile (29.11.16)



## 5 MONTHS FOLLOW-UP

- RM: radical removal without any complications
  - Pituitary function preserved
  - Absence of neurological or hypothalamic deficit
- Great control of back pain (without any drug therapy)

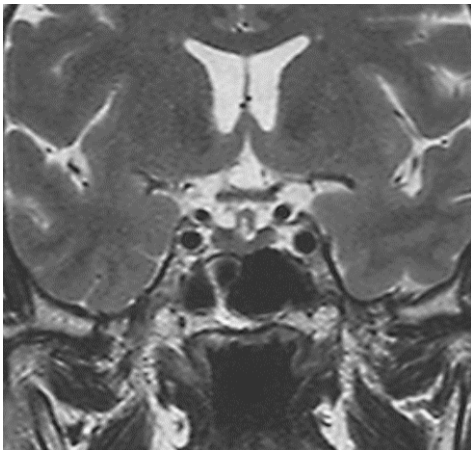
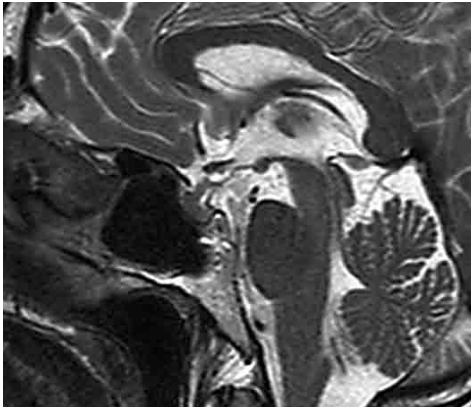


# I. Surgery: indications for first treatment and recurrence

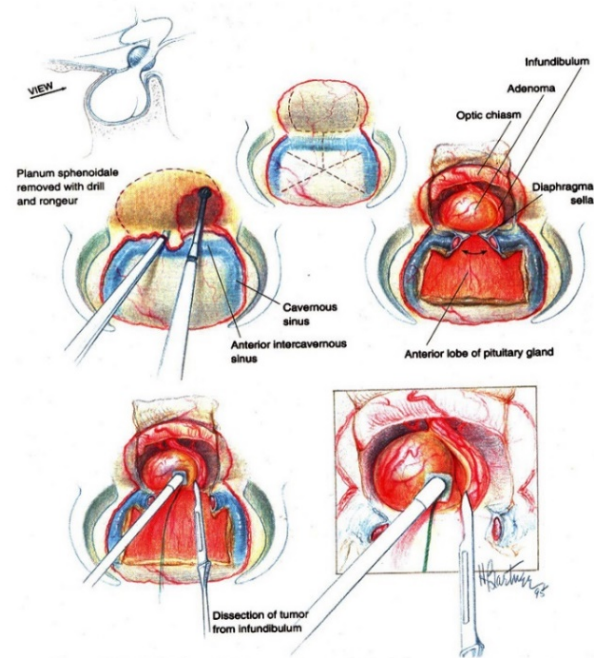
- ❑ **Resection of the pituitary lesion** through **transsphenoidal selective adenectomy** by an **experienced pituitary surgeon** is recommended as **initial treatment** in pediatric and adult patients, unless surgery is not possible or is unlikely to significantly reduce GC excess (1 | ⊕⊕⊕⊕).
- ❑ It has to be remarked that, despite the significant improvement in diagnostic techniques (sensitivity and specificity of MRI and assays for cortisol and ACTH measurement after sinus sampling), an important percentage of pituitary lesions remain **undetectable, thus making surgical approach** (i.e. decision on the side and extension of excision) and **follow-up** (MRI cannot be used to assess the extension of surgical excision) **very challenging**, and **reducing the rate of surgical remission**
- ❑ Transsphenoidal surgery (**TSS**) should be considered as **second-line treatment**:
  - a) in patients in whom the anesthesiology risk was too high because of associated comorbidities at the initial evaluation and have then been treated with medical therapy;
  - b) in case of **persistent or recurrent** disease, especially when there is evidence of **incomplete resection** or a **pituitary lesion on imaging** (2 | ⊕⊕○○)
- ❑ The **ideal time** for repeating TSS for residual disease is as soon as active, persistent disease is evident. A 4-6 week delay may be required to confirm disease persistence and indication to second surgery
- ❑ It is important to underline that **reoperation significantly increases risk of pituitary insufficiency**, since hypophysectomy has to be performed instead of selective adenectomy

Biller et al. *JCEM* 2008; 93:2454:2462 - Nieman et al. *JCEM* 2015; 100(8):2807-2831

## II. Modalities: microscopic 1997




### *Journal of Neurosurgery*



SEPTEMBER 1997 Volume 87, Number 3

Selective excision of adenomas originating in or extending into the pituitary stalk with preservation of pituitary function

R. BRYAN MASON, M.D., LYNNETTE K. NIEMAN, M.D., JOHN L. DOPPMAN, M.D., AND EDWARD H. OLDFIELD, M.D.



## II. Modalities

Neuro  
-endocrinology

Neuroendocrinology 2006;83:240–248  
DOI: [10.1159/000095534](https://doi.org/10.1159/000095534)

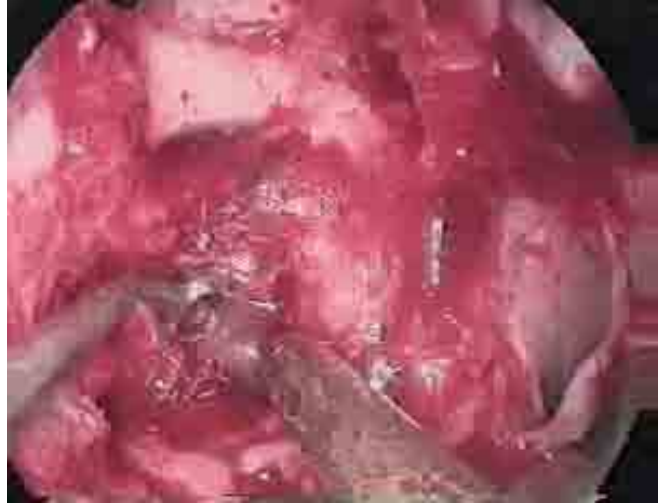Published online: October 13, 2006

# The Endoscopic versus the Traditional Approach in Pituitary Surgery

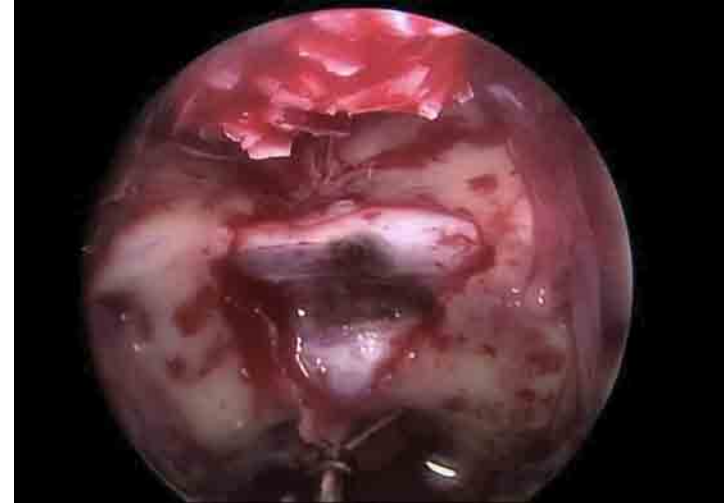Giorgio Frank Ernesto Pasquini Giovanni Farneti Diego Mazzatenta  
Vittorio Sciarretta Vincenzo Grasso Marco Faustini Fustini

Center of Surgery for Pituitary Tumors, Department of Neuroscience, Bellaria Hospital, Bologna, Italy

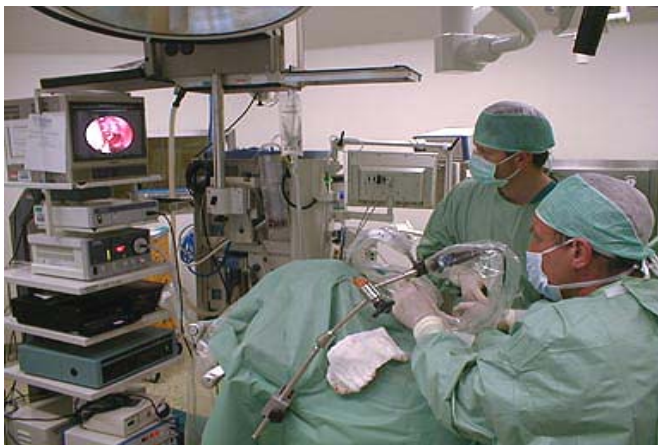## II. Modalities: technological evolution



1998



2015





# Pituitary adenomas

British Journal of Neurosurgery, June 2015; 27(5): 574-582  
 © 2015 The Neurological Foundation  
 ISSN: 0268-0987 print / ISSN 1360-0469 online  
 DOI: 10.1093/bjns/27.5.574

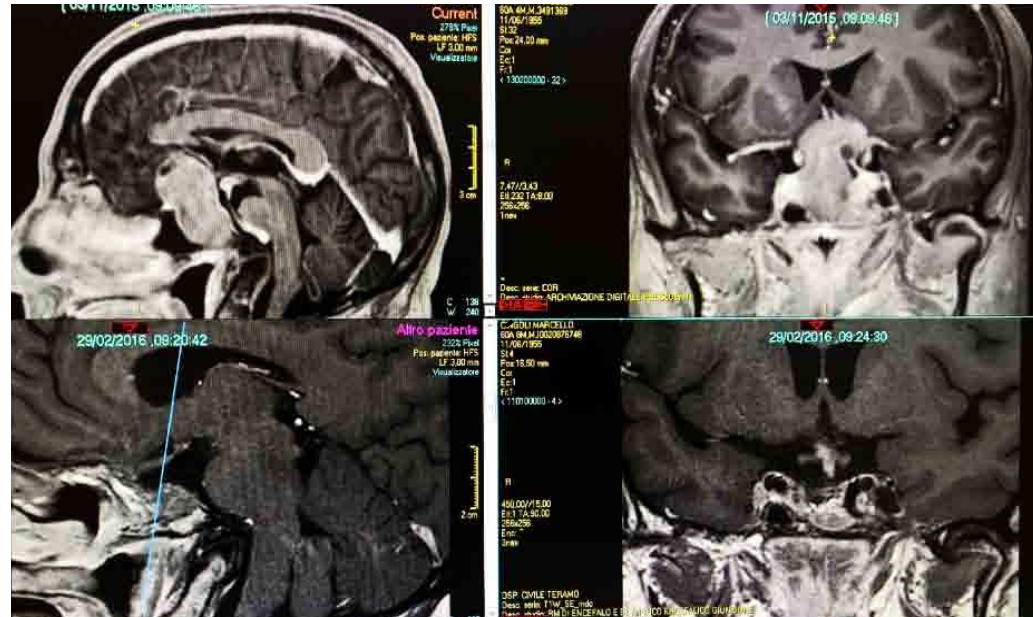
informa  
healthcare

ORIGINAL ARTICLE

## Extended endoscopic transplanum–transtuberculum approach for pituitary adenomas

S. A. Barzani<sup>1</sup>, E. Pasquin<sup>1</sup>, Pietro L’Urso<sup>2</sup>, M. Zoli<sup>1</sup>, D. Mazzatenta<sup>1</sup>, V. Sciarretta<sup>3</sup> & G. Frank<sup>1</sup>

<sup>1</sup>Department of Neurosurgery Bellaria Hospital, Bologna, Italy; <sup>2</sup>Department of Neurosurgery, King’s College Hospital, London, UK; and <sup>3</sup>ENT Department, Sant’OrsolaMalpighi Hospital, Bologna, Italy



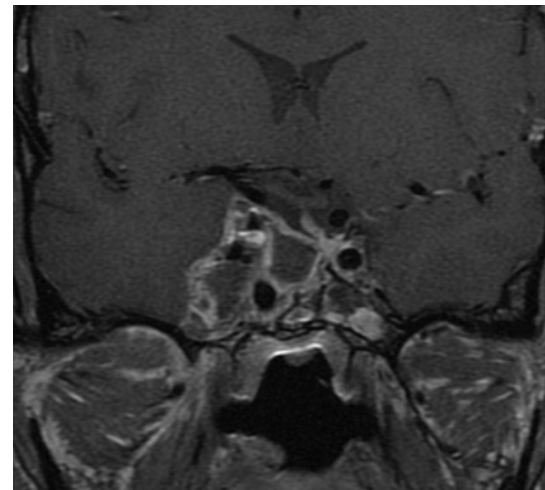
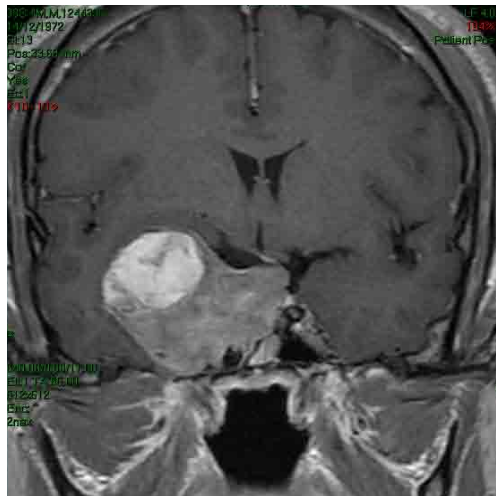
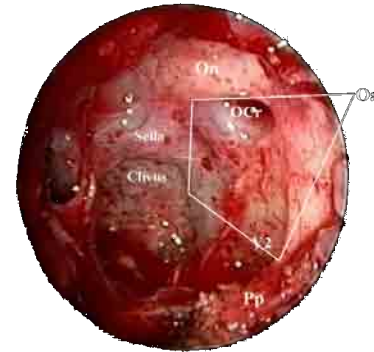
# Cavernous sinus


Laws ER Jr, Sheehan JP (eds): Pituitary Surgery – A Modern Approach.  
Front Horm Res. Basel, Karger, 2006, vol 34, pp 64–82

## Endoscopic Endonasal Cavernous Sinus Surgery, with Special Reference to Pituitary Adenomas

*Giorgio Frank, Ernesto Pasquini*

Centre of Surgery for Pituitary Tumours, Department of Neuroscience, Bellaria Hospital, Bologna, Italy






### III. Evaluation of results of TSS: diagnostic criteria and implications of *post-surgical remission*

- I. **Basal serum cortisol** in the early post-surgery and persisting up to 6 weeks
  - <2 µg/dl (<50 nmol/l) → remission and low recurrence rate (≈10% at 10 yr)
  - 2-5 µg/dl (50-140 nmol/l) → remission and low recurrence rate (similar to cortisol <2 µg/dl)
  - >5 µg/dl (>140 nmol/l) → need of patient monitoring for the higher risk of recurrence

Occasionally, the serum cortisol levels fall more gradually, possibly reflecting transient adrenal autonomy, and it is fundamental to ensure that cortisol has reached a nadir before considering further treatment. The following tests can help in the diagnostic process:

- II. **Serum cortisol after Nugent (DEX 1 mg)**
  - <2 µg/dl (<50 nmol/l) in the 1st month after surgery and <3 µg/dl (85 nmol/l) in the long term → remission
  - >5 µg/dl (>140 nmol/l) → relapse

Billir et al. *JCEM* 2008 – Raff et al. *JCEM* 2009 – Carrasco et al. *JCEM* 2008




### III. Evaluation of results of TSS: diagnostic criteria and implications of *post-surgical remission*

Cortisol serum levels below 1.8 mcg/dl (50 nmol/liter) within 2 weeks after surgery

(JCEM 2003, Consensus Conference)


Cortisol serum levels below 5 mcg/dl (140 nmol/liter) on postoperative day 1 or 2

(Esposito F. et al. JCEM 2006)



# Early postoperative predictors of long-term remission for Cushing's disease – Successful transsphenoidal surgery?

- *In order to avoid any interference in the assay of serum cortisol after surgery, **we prefer to steer clear of giving corticosteroids in the perioperative period.***
- *Of course, this choice might have unpleased consequences in the management of patients with CD in the postoperative period if you don't put so much work into it!*
- ***Please pay attention to this point!***
- *A collaboration with both endocrinologist and nurse is mandatory, because the **adrenal crisis** (vomiting, hypotension, abdominal pain...) may occur some days after surgery in the case of successful surgery!*
- *Venous samples for the measurement of serum cortisol should be obtained twice daily in the postoperative period.*
- *Corticosteroids (hydrocortisone 100 mg i.v.) immediately must be given the patient who develops signs/symptoms of adrenal insufficiency!*



### III. Evaluation of results of TSS

## Recurrence rates of Cushing's disease

- Despite surgeon's ability, CD recurrence is frequent (5-10% at 5 years, 10-20% at 10 years)

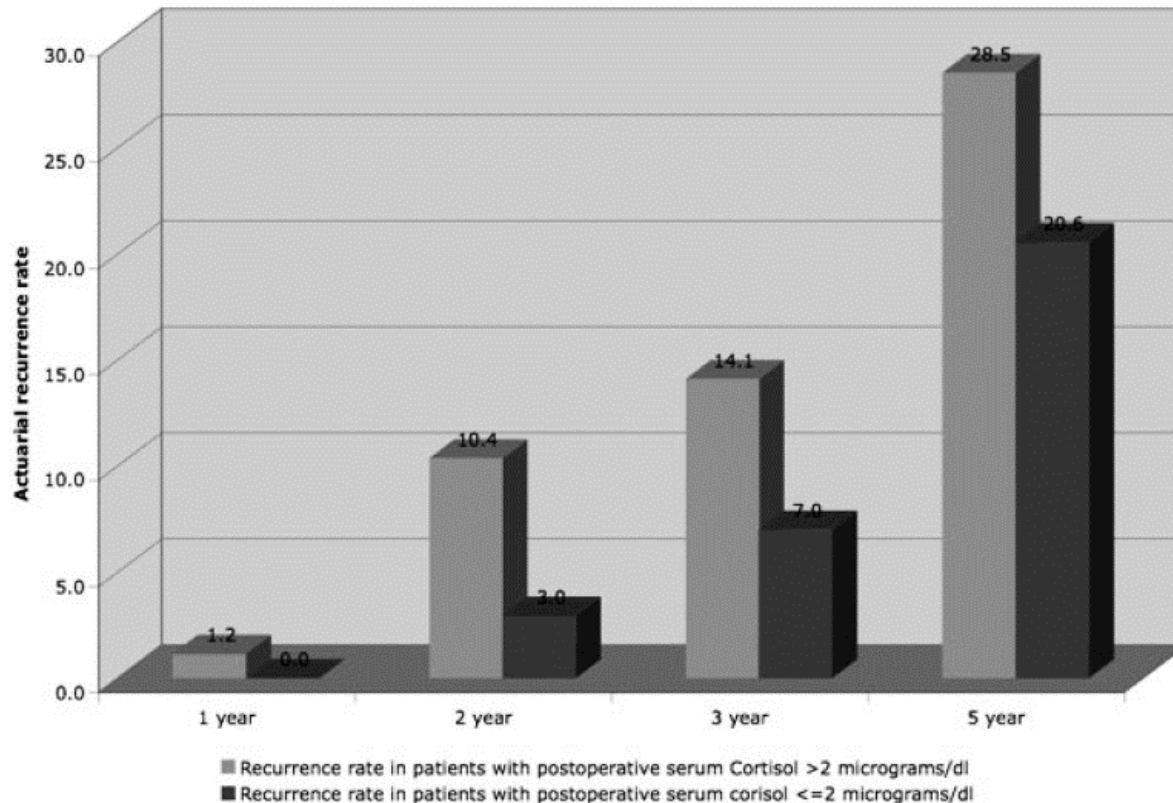



Fig. 4. Comparison of actuarial recurrence rates of patients with postoperative cortisol more than 2  $\mu\text{g}/\text{dl}$  and less than or equal to 2  $\mu\text{g}/\text{dl}$ .


Patil CG, Prevedello DM...and E. Laws jr. *JCEM* 2008



### III. Evaluation of results of *endoscopic TSS* from literature

Study	N	Mean age (y)	F (%)	Micro PAs (%)	Macro PAs (%)	CS invasion (%)	FU (m)	Remission rate (%)			Recurrence		
								Overall	MRI negative	Micro PAs	Macro PAs	Proportion (%)	Rate/person year (%)
Frank 2006	56	41	32 (57.1)	25 (44.6)	31 (55.4)	3 (5.4)	N/A	38 (67.9)	N/A	21 (84.0)	17 (54.8)	N/A	N/A
Derdashti 2007	25	42	19 (76.0)	15 (60.0)	5 (20.0)	7 (28.0)	17	20 (80.0)	2 (40.0)	13 (86.7)	4 (80.0)	0 (0.0)	0
Wagenmakers 2013	86	42.3	62 (72.1)	35 (40.7)	31 (36.0)	15 (17.4)	71	62 (72.1)	12 (60.0)	29 (82.9)	21 (67.7)	10 (16.1)	2.7
Starke 2013	61	49	52 (85.2)	30 (49.2)	15 (24.6)	6 (9.8)	28	58 (95.1)	16 (100)	29 (96.7)	13 (86.7)	6 (12.0)	5.1
Berker 2014	90	38.7	79 (87.8)	57 (63.3)	29 (32.2)	N/A	32	81 (90.0)	0 (0.0)	53 (93.0)	28 (96.6)	4 (4.9)	1.9
Kuo 2015	40	41	38 (95.0)	22 (55.0)	18 (45.0)	9 (22.5)	40.2	29 (72.5)	N/A	18 (81.8)	11 (61.1)	3 (10.3)	3.1
Sarkar 2016	64	31.9	51 (79.7)	45 (70.3)	11 (17.2)	N/A	29	47 (79.7)	4 (66.7)	39 (86.7)	5 (55.6)	4 (8.5)	3.5
Shin 2017	50	44	39 (78.0)	27 (54.0)	13 (26.0)	6 (12)	50	39 (78.0)	8 (80.0)	21 (77.8)	10 (76.9)	9 (23.1)	5.5
Cebula 2017	230	42	188 (81.7)	106 (46.1)	54 (23.5)	59 (25.7)	21	182 (79.1)	50 (71.4)	97 (91.5)	35 (64.8)	18 (9.9)	5.7
<b>Average on total sample</b>	-	41.3	79.5	53.1				79.7				11	4

**Inclusion criteria:** studies published in the last 10 years evaluating >20 patients and reporting sufficient details to define surgical outcome




### III. Evaluation of results of TSS (endo- and microscopic) from literature: *outcome predictors*

- ❑ Some predictors of outcome have been proposed although variably confirmed by subsequent ones likely because of the different criteria used to assess “remission” as well as the high heterogeneity of sample and methodological (i.e. surgical techniques, surgeon’s experience) features, and time of follow-up
  
- ❑ **Success factors**
  - **surgeon’s experience**
  - **MRI detectable adenoma**
  - **microadenoma** (65-90% vs. <65% of macroadenoma) since success depends on complete tumor exeresis
  - **pathological identification of ACTH-secreting adenoma at initial surgery**
  - **post-surgery hypocortisolism (cortisol <2 µg/dl)**: tumor resection leads to corticosteroid deficiency because the remaining normal corticotroph cells have been suppressed by longstanding hypercortisolism. As a result, hypocortisolism provides an index of surgical success
  - **long-lasting** (up to 6 weeks after surgery) **adrenal insufficiency** (serum cortisol <2/5 µg/dl)
  - **long term surveillance**

Billir et al. *JCEM* 2008 - Colao et al. *Endocrine* 2014 – Dallapiazza et al. *Pituitary* 2015






### III. Evaluation of results of TSS (endo- and microscopic) from literature: *outcome predictors*

#### ❑ Failure factors

- young age (<25 years)
- **adenoma not located:** for patients in whom adenoma cannot be located by sellar exploration, total or partial hypophysectomy may be indicated with lower rates of remission (approximately 70% of patients) and higher rate of complications and hypopituitarism than selective adenomectomy
- **macroadenoma:** the risk of complete resection is lower, thus the recurrence is higher (12-45%) and typically occurs sooner than in micros (16 vs. 49 months); however, some macros are not so aggressive either tend to switch toward silent forms
- dural/cavernous sinus invasion
- repeated surgery (remission rate 37-73% vs. 65-90%)
- confirmed remaining pituitary adenoma after initial surgery


Billir et al. *JCEM* 2008 - Colao et al. *Endocrine* 2014 – Dallapiazza et al. *Pituitary* 2015



### III. Complications of endoscopic TSS and indications for post-operative patient follow-up

- ❑ The most common complications associated with CD TSS surgery are:
  1. **hypopituitarism** (anterior/posterior)
  2. **neurological** and **visual** problems
  
- ❑ The **risk** of complications is higher in patients with macroadenomas, especially with **cavernous sinus invasion**, and after **repeated surgeries**
  
- ❑ Therefore, the **re-evaluation of anterior and posterior pituitary function** (other than HPA axis) in the **early post-surgery** and in the **subsequent weeks** is recommended (1 | ⊕⊕⊕○)
  
- ❑ A **post-operative MRI** after 1-3 months from TSS is also recommended (1 | ⊕⊕⊕○), especially in patients with normal-high levels of cortisol to early identify tumor remnants

Biller et al. *JCEM* 2008; 93:2454:2462 - Nieman et al. *JCEM* 2015; 100(8):2807-2831



### III. Evaluation of results of endoscopic TSS: Pituitary Unit and center of endoscopic skull base surgery IRCCS Institute of Neurological Sciences of Bologna

**Inclusion criteria:** patients with CD treated in our Center from 1998 to 2017 by endoscopic TSS by the same team made of two expert surgeons and an otolaryngologist, with complete pre- and post-surgical clinical and endocrinological data, and at least 3 month-follow-up were evaluated

**151 patients (119 single surgery; 32 multiple surgeries)**

- 107 (78.9%) Female
- 44 (29.1%) Male

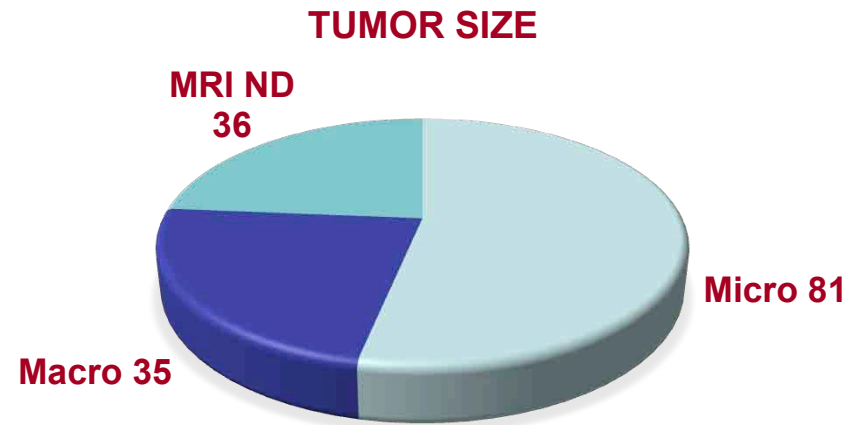
**Mean age  $\pm$  SD at 1 st surgery: 41.1  $\pm$ 2.6**


**Female: 42.1  $\pm$  2.9**

**Male: 38.5  $\pm$ 5.5**


**167 procedures**

- **135 First surgery at IRCCS ISNB**
- **32 Subsequent surgeries at IRCCS ISNB**






<b>Feature</b>	<b>Total sample</b>
<b>Hypopituitarism before 1 st surgery at IRCCS ISNB</b>	<b>26</b>
<b>Neurological alterations before 1 st surgery at IRCCS</b>	<b>7</b>
<b>Visual alterations before 1 st surgery at IRCCS</b>	<b>7</b>



# Results: surgery


Study	N	FU (m)	Remission rate (%)			Recurrence		
			Overall	MRI negative	Micro PAs	Macro PAs	Proportion (%)	Rate/person year (%)
Frank 2006	56	N/A	38 (67.9)	N/A	21 (84)	17 (54.8)	N/A	N/A
Current serie 2017	151	94	122 (80.7)	26 (72.2)	68 (84)	28 (80)	24 (15)	0



## Results: overall


Feature	Total sample
Remission at last follow up (RTX;surrenectomy)	134
Active disease controlled by medical therapy at last follow-up	13
Active disease NOT controlled by medical therapy at last follow-up	4

**Follow-up (mean  $\pm$ SD)      94 $\pm$ 11.7**



# Complications

<b>Endocrinological</b>	<b>Total sample</b>
Hypopituitarism after 1st surgery at IRCCS	47/135 (34%)
Hypopituitarism after subsequent surgeries at IRCCS	17/32 (53%)
<b>Neurological</b>	
III° cn palsy	2
<b>Visual</b>	
BTH	1
<b>Surgical</b>	
Epistaxis	2/167* (1,19%)
CSF leak	2/167* (1,19%)
<b>Medical</b>	
Polmonary embolism	2
Pneumonia	3
NSTEMI	1



# **Outcome predictors**

## **(results of multivariate logistic regression analysis)**

- 1. The absence of visible adenoma at MRI did not impact on surgical outcome (similar rate of remission in patients with micro/macroadenomas and patients in whom adenoma was not detectable)**
- 2. The presence of cortisol drop  $<5$  mcg/dl do not predict a better outcome**
- 3. The number of surgeries (single vs multiple) did not predict the outcome (the chance of remission was similar between patients treated with one or multiple surgeries)**
- 4. The risk of developing hypopituitarism was significantly higher in patients who underwent multiple surgeries vs. single surgery (almost doubled)**



## V. Conclusions

- ❑ Endoscopic TSS is the **gold standard treatment for CD**
- ❑ Surgical **chances of success** mainly depends on the **Pituitary team expertise**
- ❑ Not only surgeon's expertise
- ❑ Multidisciplinary management is required to **diagnose CD** and **prepare the patient to undergo**, then to **manage alterations of anterior and posterior pituitary induced by surgery**
- ❑ In our experience, repeated surgery is associated with a significantly higher risk of hypopituitarism, but not of neurological or visual defects, nor predicts a worse outcome

