



Roma, 9-12 novembre 2017



ITALIAN CHAPTER



US-guided FNA and CNB



Salvatore Monti

UOC Endocrinologia Ospedale Sant'Andrea

Roma



Roma, 9-12 novembre 2017

Conflitti di interesse



ITALIAN CHAPTER



Ai sensi dell'art. 3.3 sul conflitto di interessi, pag 17 del Regolamento Applicativo Stato-Regioni del 5/11/2009, dichiaro che negli ultimi 2 anni ho avuto rapporti diretti di finanziamento con i seguenti soggetti portatori di interessi commerciali in campo sanitario:

NESSUNO



Roma, 9-12 novembre 2017

Thyroid nodules



ITALIAN CHAPTER



- ✓ Thyroid nodules are detected in up to 60% of healthy subjects
- ✓ Most patients with thyroid nodules are asymptomatic, but the absence of symptoms does not rule out malignancy
- ✓ The main challenge in their management is to rule out malignancy



Roma, 9-12 novembre 2017

Thyroid nodules: diagnosis of malignancy



Tissue for diagnosis examination may be obtained from the thyroid nodule by several different techniques:

- fine-needle aspiration (FNA), using a syringe
- fine-needle capillary sampling (FNC), without aspiration
- large-needle aspiration (LNA), using a syringe
- core needle biopsy (CNB), using cutting needle

The biopsy techniques can be guided by palpation only or, preferably, by ultrasound



Fine-needle aspiration (FNA)



ITALIAN CHAPTER

Roma, 9-12 novembre 2017

- FNA is the procedure of choice in the evaluation of malignancy in thyroid nodules
- FNA is a simple and safe office procedure in which tissue samples are obtained for cytologic examination
- Ultrasound guidance is preferred (US-FNA)
- Ultrasound guidance makes the procedure safer, more reliable, and more accurate

GUIDELINES

Ultrasound vs Palpation guided FNA



ITALIAN CHAPTER



Roma, 9-12 novembre 2017

Compared with palpation-guided FNA, the use of ultrasound (US-FNA) improves the cytologic diagnostic accuracy rate and reduces the nondiagnostic rate

Evidence-Based Assessment of the Role of Ultrasonography in the Management of Benign Thyroid Nodules

Level of evidence	Reference	Study design	Sensitivity (%)		Specificity(%)		Accuracy (%)		Unsuccessful aspiration (%)		False negative (%)	
			Palpation-guided FNA	US-guided FNA	Palpation-guided FNA	US-guided FNA	Palpation-guided FNA	US-guided FNA	Palpation-guided FNA	US-guided FNA	Palpation-guided FNA	US-guided FNA
III	Cesur [33]	285 Palpable thyroid nodules 1.0-2.5 cm diameter examined with palpation, then US-guided FNA. Operating characteristics determined from review of histology vs. cytology in 26 nodules.	57	86	84	90	77	89	32*	21*	16	6
III	Koike [25]	329 US-guided FNA specimens vs. surgical pathology	—	84	—	87	—	85	—	5	—	6
IV	Danese [32]	1075 Patients with FNA vs. surgical pathology	92	97	69	71	73	76	9	4	2*	1*
IV	Hatada [31]	166 Palpable nodules (72 with US guidance) FNA vs. surgical pathology	45	62	51	74	48*	68*	30	17	20*	15*
IV	Takashima [34]	268 Thyroid nodules examined by US-guided FNA; 62 also examined with palpation-guided FNA. Operating characteristics determined from review of histology vs. cytology in 34 nodules (palpation-guided FNA) and 99 nodules (US-guided FNA).	88	96	90	91	88	94	19*	4*	9	3



Fine-needle aspiration (FNA)



Roma, 9-12 novembre 2017

- FNA is the procedure of choice in the evaluation of malignancy in thyroid nodules
- FNA is a simple and safe office procedure in which tissue samples are obtained for cytologic examination
- Ultrasound guidance is preferred (US-FNA)
- Ultrasound guidance makes the procedure safer, more reliable, and more accurate
- The current guidelines recommend performing ultrasound guided FNA biopsy (US-FNAB) with 23- to 27-gauge needles, with or without aspiration.

GUIDELINES

Assessment of thyroid nodule malignancy



Roma, 9-12 novembre 2017



- ✓ History and physical examination
- ✓ Measurement of serum TSH and Calcitonin (???)
- ✓ Ultrasonographic features



Assessment of thyroid nodule malignancy

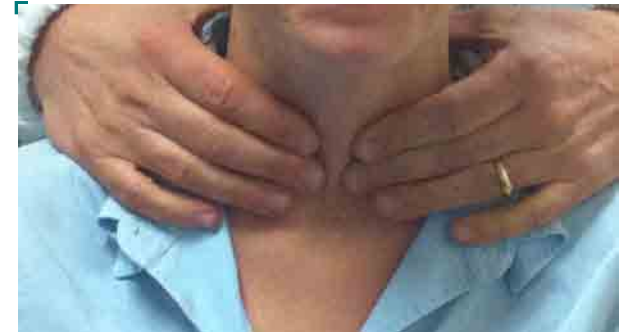


ITALIAN CHAPTER

Roma, 9-12 novembre 2017

History and physical examination

- History of head and neck irradiation
- Family history of medullary thyroid carcinoma,
- Family history of multiple endocrine neoplasia type 2
- Family history of papillary thyroid carcinoma
- Age <14 or >70 years
- Male sex
- Growth of the nodule
- Firm or hard nodule consistency
- Fixed nodule
- Cervical adenopathy
- Persistent dysphonia, dysphagia, or dyspnea
- 18FDG-PET positive thyroid nodules





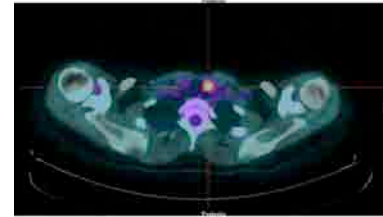
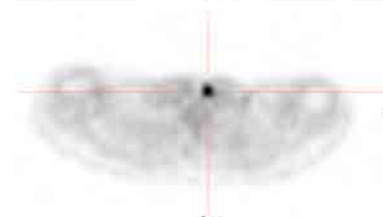
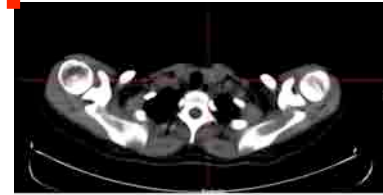
^{18}F FDG-PET



ITALIAN CHAPTER

Roma, 9-12 novembre 2017

- Thyroid incidentalomas detected by positron emission tomography (PET) with ^{18}F -fluoro-deoxyglucose (focal uptake) should undergo US evaluation and FNA because of the high risk of malignancy.
- Approximately 35% ^{18}F FDG-PET positive thyroid nodules are cancer.
- Diffuse ^{18}F FDG-PET uptake, in conjunction with sonographic and clinical evidence of chronic lymphocytic thyroiditis, does not require further imaging or FNA.





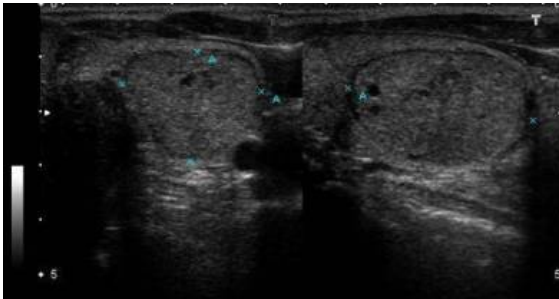
Hormonal status



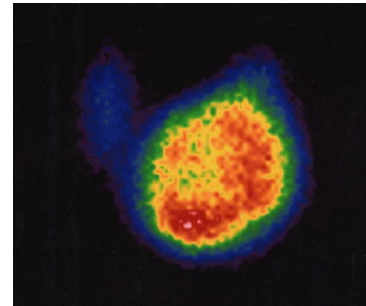
ITALIAN CHAPTER

Roma, 9-12 novembre 2017

- TSH should be assessed in all patients with thyroid nodules.
- If the serum **TSH is subnormal**, a radionuclide (preferably ¹²³I) thyroid scan should be performed.
- **US-FNAB is not recommended** for nodules that are functional on scintigraphy (hot nodules)



➤ TSH 0.17 μ IU/ml
➤ FT4/FT3 normal





Hormonal status



ITALIAN CHAPTER

Roma, 9-12 novembre 2017

- TSH should be assessed in all patients with thyroid nodules.
- If the serum **TSH is subnormal**, a radionuclide (preferably ¹²³I) thyroid scan should be performed.
- FNA is not recommended for nodules that are functional on scintigraphy (hot nodules)
- If the serum TSH concentration **is normal or elevated** and the nodule meets sonographic criteria for sampling, then FNA biopsy is indicated



Calcitonin



- The routine measurement of serum calcitonin in patients with nodular thyroid disease is controversial.
- There was agreement that serum calcitonin may be considered in:
 - patients with a family history or clinical suspicion of familial MTC or MEN2
 - thyroid nodules with US findings or indeterminate cytologic findings suggestive of MTC
 - patients with a nodular goiter undergoing thyroid surgery to avoid the risk of incomplete surgery
- There is emerging evidence that a calcitonin measurement from a thyroid nodule fine-needle aspiration (FNA) washout may be helpful in the preoperative evaluation of patients with a modestly elevated basal serum calcitonin

Assessment of thyroid nodule malignancy



Roma, 9-12 novembre 2017



- History and physical examination
- Measurement of serum TSH and Calcitonin (???)
- **Ultrasonographic features**



Roma, 9-12 novembre 2017

Thyroid Nodule Ultrasound Classification Systems

AACE/ACE-AME	ATA	BTA
<p>1 Low-risk lesion</p> <ul style="list-style-type: none"> Cysts (fluid component >80%) Mostly cystic nodules with reverberating artifacts and not associated with suspicious US signs Isoechoic spongiform nodules, either confluent or with regular halo 	<p>Benign</p> <p>Purely cystic nodules (no solid component)</p> <p>Very low suspicion</p> <p>Spongiform or partially cystic nodules without any of the US features described in low-, intermediate- or high-suspicion patterns</p> <p>Low suspicion</p> <p>Isoechoic or hyperechoic solid nodule, or partially cystic nodule with eccentric solid area <u>without</u>:</p> <ul style="list-style-type: none"> Microcalcifications Irregular margin Extrathyroidal extension Taller than wide shape 	<p>U1 Normal</p> <p>U2 Benign</p> <ol style="list-style-type: none"> Halo, isoechoic, mildly hyperechoic Cystic change ± ring-down sign (colloid) Microcystic/spongiform D-E. Peripheral eggshell calcification Peripheral vascularity
<p>2 Intermediate-risk thyroid lesion</p> <p>Slightly hypoechoic (vs. thyroid tissue) or isoechoic nodules, with ovoid-to-round shape, smooth or ill-defined margins</p> <p>May be present:</p> <ul style="list-style-type: none"> Intranodular vascularization Elevated stiffness at elastography, Macro or continuous rim calcifications Indeterminate hyperechoic spots 	<p>Intermediate suspicion</p> <p>Hypoechoic solid nodule with smooth margins <u>without</u>:</p> <ul style="list-style-type: none"> Microcalcifications Extrathyroidal extension Or taller than wide shape 	<p>U3 Indeterminate/equivocal</p> <ol style="list-style-type: none"> Homogeneous, markedly hyperechoic, solid, halo (follicular lesion) Hypoechoic (?), equivocal echogenic foci, cystic change (irregular) Mixed/central vascularity
<p>3 High-risk thyroid lesion (50-90%)</p> <p>Nodules <u>with at least 1</u> of the following features:</p> <ul style="list-style-type: none"> Marked hypoechoogenicity (vs. prethyroid muscles) Spiculated or lobulated margins Microcalcifications Taller-than-wide shape (AP>TR) Extrathyroidal growth Pathologic adenopathy <p>Expected risk of malignancy in accordance with the presence of 1 or more suspicious findings.</p>	<p>High suspicion</p> <p>Solid hypoechoic nodule or solid hypoechoic component of partially cystic nodule <u>with 1 or more</u> of the following features:</p> <ul style="list-style-type: none"> Irregular margins (infiltrative, microlobulated) Microcalcifications Taller than wide shape Rim calcifications with small extrusive soft tissue component Evidence of extrathyroidal extension 	<p>U4 suspicious</p> <ol style="list-style-type: none"> Solid, hypoechoic (cf. thyroid) Solid, very hypoechoic (cf. strap muscle) Disrupted peripheral calcification, hypoechoic Lobulated outline <p>U5 Malignant</p> <ol style="list-style-type: none"> Solid, hypoechoic, lobulated/irregular outline, microcalcification (papillary carcinoma?) Solid, hypoechoic, lobulated/irregular outline, globular calcification (medullary carcinoma?) Intranodular vascularity Shape tall>wide (AP>TR) Characteristic associated lymphadenopathy

Abbreviations: AACE/ACE/AME = American Association of Clinical Endocrinologists/American College of Endocrinology/ Associazione Medici Endocrinologi; AP = anteroposterior; ATA = American Thyroid Association; BTA = British Thyroid Association; TR = transverse; US = ultrasonography.

^a Adapted from: 2015 ATA Management Guidelines for Adult Patients with Thyroid Nodules and Differentiated Thyroid Carcinoma. *Thyroid*. 2016;26:1-133; British Thyroid Association Guidelines for the Management of Thyroid Carcinoma. *Clin Endocrinol*. 2014;81 Suppl 1:1-122; 2016 AACE/ACE-AME Clinical Practice Guidelines for the Diagnosis and Management of Thyroid Nodules. *Endocr Pract*. 2016;22 Suppl 1:1-59.



ITALIAN CHAPTER



2016 AACE-AME Thyroid US classification



- ✓ US class 1: Low-risk thyroid lesion
- ✓ US class 2: Intermediate-risk thyroid lesion
- ✓ US class 3: High-risk thyroid lesion



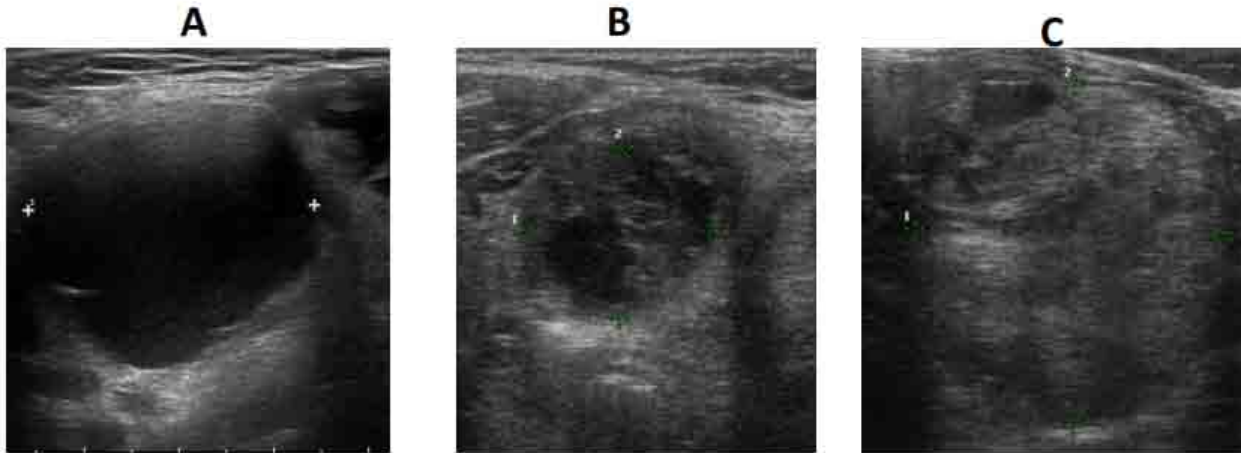


Roma, 9-12 novembre 201

US class 1. Low-Risk nodules



ITALIAN CHAPTER



- A. Thyroid cyst (fluid component > 80% , regular margins)
- B. Mostly cystic nodule with reverberating artifacts, no suspicious signs
- C: Iso-echoic spongiform nodule , regular margins.

Risk of malignancy 1%

2016 AACE/AME/ETA Guidelines



Indication for FNA



ITALIAN CHAPTER

Roma, 9-12 novembre 2017

Class 1: Low-risk lesions

FNA is recommended **only** when nodules are >20 mm and are

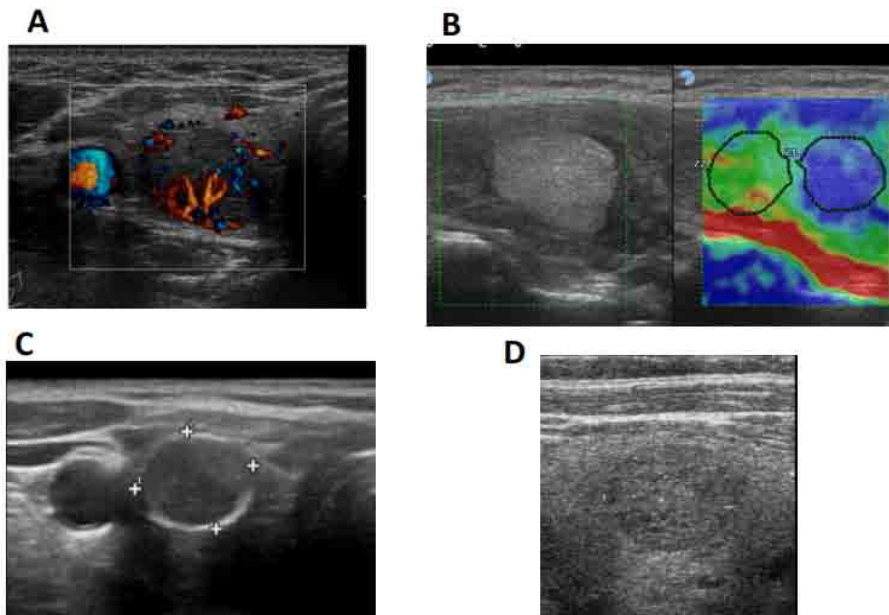
- ✓ Increasing in size
- ✓ or associated with a high-risk history
- ✓ or before thyroid surgery
- ✓ or before minimally invasive ablation therapy

Class 2. Intermediate-risk thyroid lesion



ITALIAN CHAPTER

Roma, 9-12 novembre 2017



Slightly hypo- or iso-echoic nodules with smooth margins or halo. May be present:
A. intranodular vascularization; B. elevated stiffness at elastography;
C. coarse or rim calcifications; D. indeterminate hyperechoic spots.

Risk of malignancy 5-15%

2016 AAACE/AME/ETA Guidelines



Roma, 9-12 novembre 2017

Indication for FNA



ITALIAN CHAPTER



Class 2. Intermediate-risk thyroid lesion

FNA is recommended when nodules are > 20 mm

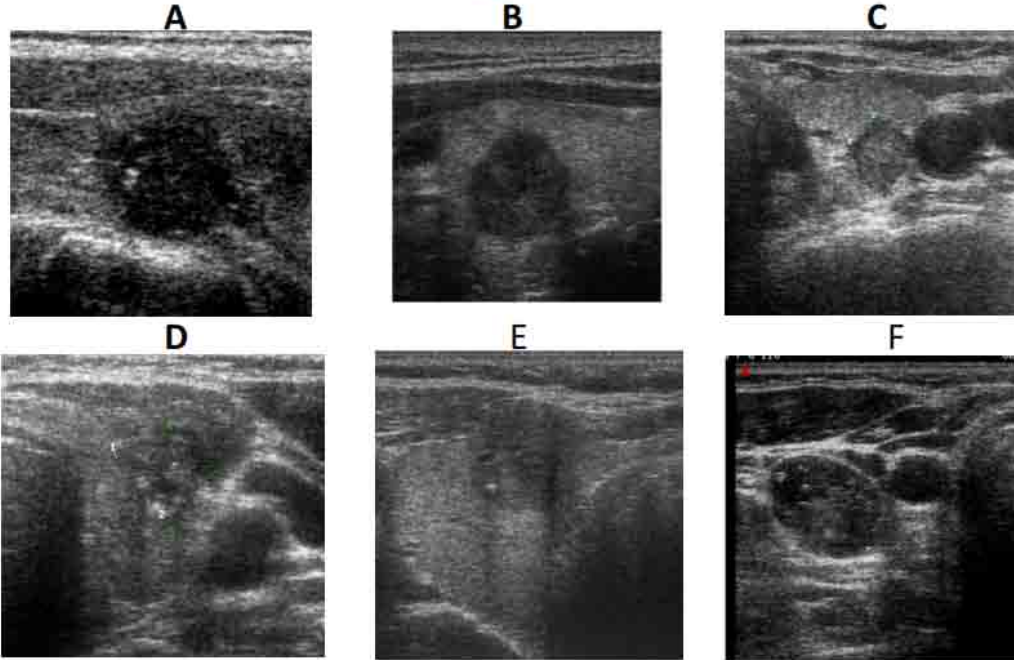


Roma, 9-12 novembre 2017

Class 3. High-risk thyroid lesion



ITALIAN CHAPTER



A. Marked hypoechoogenicity; B. Spiculated or lobulated margins; C. More tall than wide shape; D. Microcalcifications; E. Extracapsular growth; F. Pathologic adenopathy.

Risk of malignancy 50-90% 2016 AACE/AME/ETA Guidelines



Roma, 9-12 novembre 2017

Indication for FNA



Class 3. High-risk thyroid lesion

FNA is always recommended when nodules are > 10 mm



Indications for FNA

Class 3. High-risk thyroid lesion

In nodules with a major diameter of 5 to 10 mm consider either FNA sampling or watchful waiting on the basis of the clinical setting and patient preference

Specifically, FNA is recommended for the following nodules:

- Subcapsular or paratracheal lesions
- Suspicious lymph nodes or extrathyroid spread
- Positive personal or family history of thyroid cancer
 - History of head and neck irradiation
 - Coexistent suspicious clinical findings (e.g., dysphonia)



Roma, 9-12 novembre 2017

Nodules <5 mm



ITALIAN CHAPTER



In light of the low clinical risk, nodules with a major diameter <5 mm should be monitored, rather than biopsied, with US, irrespective of their sonographic appearance.

Thyroid cytologic results



ITALIAN CHAPTER



Roma, 9-12 novembre 2017

Table 2
Comparison of the Italian AME Consensus, BSRTC, and UK-RCPATH Systems for
Classification and Reporting of Thyroid Cytologic Results

Italian Consensus, 2014	BSRTC	UK-RCPATH
TIR 1. Nondiagnostic	I. Nondiagnostic	Thy 1. Nondiagnostic
TIR 1c. Nondiagnostic cystic	I. Cystic fluid only	Thy 1c. Unsatisfactory, consistent with cyst
TIR 2. Nonmalignant	II. Benign	Thy 2/Thy 2c. Nonneoplastic
TIR 3A. Low-risk indeterminate lesion	III. AUS/FLUS atypia or follicular lesion of undetermined significance	Thy 3a. Neoplasm possible: atypia/nondiagnostic
TIR 3B. High-risk indeterminate lesion	IV. Follicular neoplasm or suspicious for follicular neoplasm	Thy 3f. Neoplasm possible: suggestive of follicular neoplasm
TIR 4. Suspicious for malignancy	V. Suspicious for malignancy	Thy 4. Suspicious for malignancy
TIR 5. Malignant	VI. Malignant	Thy 5. Malignant

Abbreviations: AME = Associazione Medici Endocrinologi; AUS/FLUS = follicular lesion/atypia of undetermined significance; BSRTC = Bethesda System for Reporting Thyroid Cytopathology; TIR = Thyroid Imaging Reporting; Thy = thyroid; UK-RCPATH = UK Royal College of Pathologists.



2014 Italian Consensus



ITALIAN CHAPTER

Roma, 9-12 novembre 2017

CONSENSUS STATEMENT

Italian consensus for the classification and reporting of thyroid cytology

Table 1 2013 Italian thyroid cytology classification system

Code	Diagnostic category	Expected risk of malignancy (%)	Suggested actions
TIR1	Non-diagnostic	Not defined	Repeat US-guided FNA after at least 1 month
TIR1C	Non-diagnostic-cystic	Low (variable on the basis of clinical findings)	Evaluate the clinical setting and/or repeat FNA
TIR2	Non-malignant/benign	<3	Follow-up
TIR3A	Low-risk indeterminate lesion (LRL)	<10 ^a	Repeat FNA/clinical follow-up
TIR3B	High-risk indeterminate lesion (HRL)	15–30 ^a	Surgery
TIR4	Suspicious of malignancy	60–80	Surgery (consider frozen section)
TIR5	Malignant	>95	Surgery

8-15%

54-74%

7-10%

7-10%

2,5-5%

4-5,4%

^a Expected rate of malignancy for the TIR3 subcategories is mainly found on clinical experience and is only partially based on the evidence of the published data



CORE NEEDLE BIOPSY (CNB)



- ✓ Core Needle Biopsy (CNB) has been proposed as an additional diagnostic method to US-FNA, mainly to overcome the limitations of inconclusive cytologic diagnosis.
- ✓ CNB provides a large amount of tissue which enables histologic diagnosis and the potential application of ancillary techniques.
- ✓ Modern CNB devices, particularly 18–21-gauge, spring-activated, core needles, are recommended for procedure





CNB IN THYROID NODULES WITH PREVIOUS

NOT ADEQUATE CYTOLOGY (THY 1/CLASS 1/CATEGORY I)



ITALIAN CHAPTER



- ✓ Inadequate cytology occurs in 5-15 % of cases
- ✓ **After repetition, 20-40% of these FNABs remain non-diagnostic**
- ✓ Surgery is recommended for solid nodules with repeated inadequate results
- ✓ The malignancy rate is relatively low (5%–30%) in non diagnostic cytology

Thyroid nodules with initially non-diagnostic, fine-needle aspiration results: comparison of core-needle biopsy and repeated fine-needle aspiration

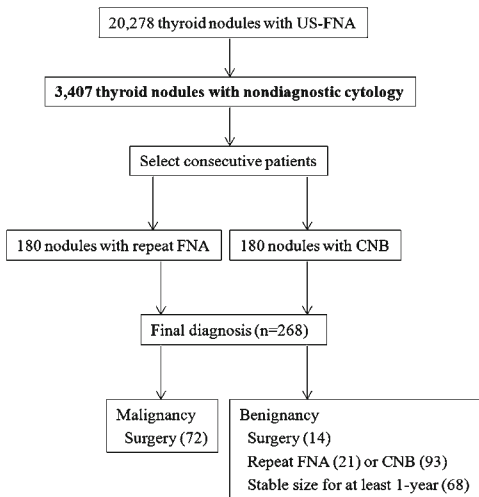


Fig. 1 Diagram of the study population and the final diagnosis

Table 1 Comparison of the repeated FNA and CNB diagnosis in thyroid nodules with initially non-diagnostic FNA results

Diagnosis	Repeated FNA (n=180)	Final diagnosis (n=140)		CNB (n=180)	Final diagnosis (n=128)		P-value
		Benign (n=115)	Malignancy (n=25)		Benign (n=81)	Malignancy (n=47)	
Non-diagnostic	72 (40.0 %)	51 (44.3 %)	5 (20.0 %)	2 (1.1 %)	1 (1.2 %)	1 (2.1 %)	<0.001
Benign	30 (16.7 %)	23 (20.0 %)	1 (4.0 %)	106 (58.9 %)	71 (87.7 %)	1 (2.1 %)	<0.001
AUS or FLUS	58 (32.2 %)	38 (33.0 %)	6 (24.0 %)	11 (6.1 %)	6 (7.4 %)	0 (0.0 %)	<0.001
FN or SFN	1 (0.6 %)	1 (0.9 %)	0 (0.0 %)	3 (1.7 %)	3 (3.7 %)	0 (0.0 %)	1.0
Suspicious for malignancy	4 (2.2 %)	1 (0.9 %)	3 (12.0 %)	5 (2.8 %)	0 (0.0 %)	4 (8.5 %)	1.0
Malignancy	15 (8.3 %)	1 (0.9 %)	10 (40.0 %)	53 (29.4 %)	0 (0.0 %)	41 (87.2 %)	<0.001

AUS/FLUS, atypia of undetermined significance or a follicular lesion of undetermined significance; CNB, core-needle biopsy; FN/SFN, follicular neoplasm or suspicious for follicular neoplasm; rFNA, repeated fine-needle aspiration

Table 2 Diagnostic performance of repeated FNA and CNB in thyroid nodules with initially non-diagnostic results

	Repeated FNA	CNB
Diagnostic accuracy	60.0 %	98.4 %
Sensitivity	52.0 %	95.7 %
Specificity	98.3 %	100.0 %
Positive predictive value	86.7 %	100.0 %
Negative predictive value	90.4 %	97.6 %

Comparison of diagnostic yield of core-needle and fine-needle aspiration biopsies of thyroid lesions: Systematic review and meta-analysis

Table 1 Studies comparing the diagnostic efficacy of core-needle biopsy (CNB) and fine-needle aspiration biopsy (FNAB) in lesions with a previous non-diagnostic FNAB result

Author	Year	Country	Design	Needles	FNAB – diagn.	FNAB – ndg.	CNB – diagn.	CNB – ndg.
Chen et al. [16]	2014	USA	Retrospective; no specific selection criteria – FNAB and CNB interchangeably dependent on the preference of the radiologist	FN: 25–27 G; CN: 20 G, semi-automatic biopsy device	70	26	359	6
Choi et al. [17]	2014	South Korea	Retrospective; lesions with previous ndg.	FNA: 21–23 G; CN: 18 G; automatic biopsy gun used	108	72	178	2
Lee et al. [18]	2014	South Korea	Retrospective; lesions with previous ndg.	FN: no data; CN: 18 G; automatic biopsy gun used	260	129	122	3
Stangierski et al. [19]	2013	Poland	Prospective; lesions with previous ndg.	FN: 25 G; CN: 22 G	30	29	17	13
Na et al. [20]	2012	South Korea	Prospective; FNAB and CNB simultaneously; lesions with previous ndg.	FN: 25, 23 and 21 G; CN: 18 G; automatic biopsy gun used	46	18	63	1
Samir et al. [21]	2012	USA	Retrospective; FNAB and CNB simultaneously; lesions with previous ndg.	CB: 20 G; FN: 25 G;	42 (3)			
Sung et al. [22]	2012	South Korea	Retrospective; FNAB and CNB simultaneously	CN: 18 G; FN: 21, 23 and 25 G; automatic biopsy gun used	521	34	547	8
Park et al. [23]	2011	South Korea	Retrospective; lesions with previous ndg. FNAB	CN: 18 G, FN: no data; automatic biopsy gun used	73	69	53	1
Renshaw et al. [6]	2007	USA	Retrospective; CNB and FNAB simultaneously – lesions with previous ndg. FNAB and also as first choice	FN: 25, 23 and 21 G; CN: 18, 20, 21 G	265	112	310	67
Strauss et al. [24]	2007	USA	CNB and FNAB – lesions with previous ndg. FNAB	CN: 20 G; FN: 22, 25 G	22	59	43	38
Karstrup et al. [25]	2001	Denmark	Palpable lesions only; FNAB and CNB simultaneously;	CN: 18 G, automatic biopsy gun used; FN: 21 G	75	2	68	9

*Results for lesions with only one prior non-diagnostic biopsy were included

FN – fine needle, CN core needle, *diagn.* diagnostic results, *ndg.* non-diagnostic results

Critical issues:

- number of low studies
- most studies are retrospective
- studies are heterogeneous:
 - ✓ diameter of needles
 - ✓ design of the study

FURTHER STUDIES ARE REQUIRED



**AMERICAN ASSOCIATION OF CLINICAL ENDOCRINOLOGISTS,
AMERICAN COLLEGE OF ENDOCRINOLOGY, AND
ASSOCIAZIONE MEDICI ENDOCRINOLOGI MEDICAL GUIDELINES FOR
CLINICAL PRACTICE FOR THE DIAGNOSIS AND MANAGEMENT OF
THYROID NODULES – 2016 UPDATE
*EXECUTIVE SUMMARY OF RECOMMENDATIONS***

4.4. Core-Needle Biopsy

- Consider the use of US-guided core-needle biopsy (CNB) in solid thyroid nodules with persistently inadequate FNA cytologic findings [BEL 3, GRADE C].
- Because of the limited evidence and lack of established reporting systems, we do not recommend either in favor of or against the use of CNB in nodules with indeterminate cytologic results [BEL 4, GRADE D].

Solid, persistently nondiagnostic nodules should be considered for US-guided CNB (198 [EL 3]) because microhistologic assessment may offer additional information to FNA in these cases (197 [EL 2], 253 [EL 3]).

CNB has been proposed in the management of the AUS/FLUS subcategory because the architectural findings and comparison with the surrounding normal thyroid tissue may provide further information (335 [EL 2]). However, the role of CNB in indeterminate lesions requires confirmation.



USE OF CNB IN INDETERMINATE CYTOLOGY (THY 3/CLASS 3/CATEGORY III–IV)

CNB have possible advantages over FNA cytology:

- ✓ visualizes the microscopic monotonous follicular proliferation and the presence of fibrous capsules
- ✓ enables the potential application of ancillary techniques (as immunohistochemical staining)



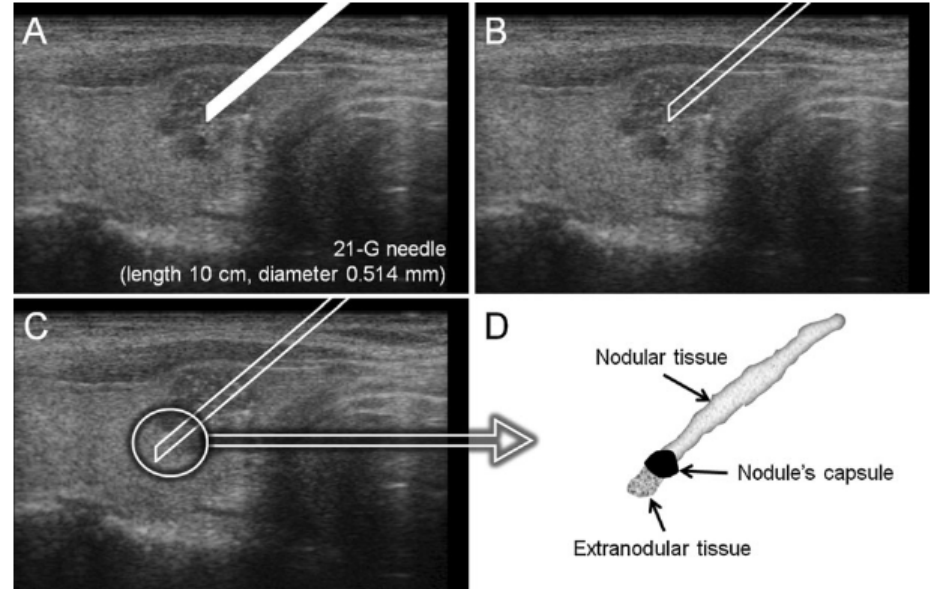
Thin core biopsy should help to discriminate thyroid nodules cytologically classified as indeterminate. A new sampling technique



ITALIAN CHAPTER

Roma, 9-12 novembre 2017

- A) The 21-G Menghini cutting needle is inserted into the nodule;
- B) Mandrel is removed;
- C) Needle is advanced within the nodule and moved ahead across the nodule's margin reaching extranodular tissue;
- D) Needle is removed, and the obtained core sample consists of nodular tissue, extranodular parenchyma, and nodule's capsule when present.





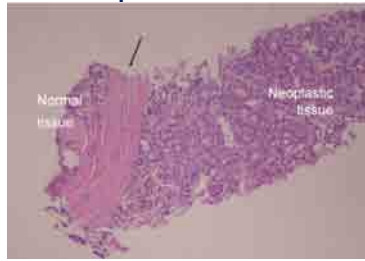
Thin core biopsy should help to discriminate thyroid nodules cytologically classified as indeterminate. A new sampling technique



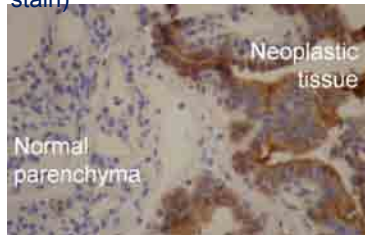ITALIAN CHAPTER

Roma, 9-12 novembre 2017

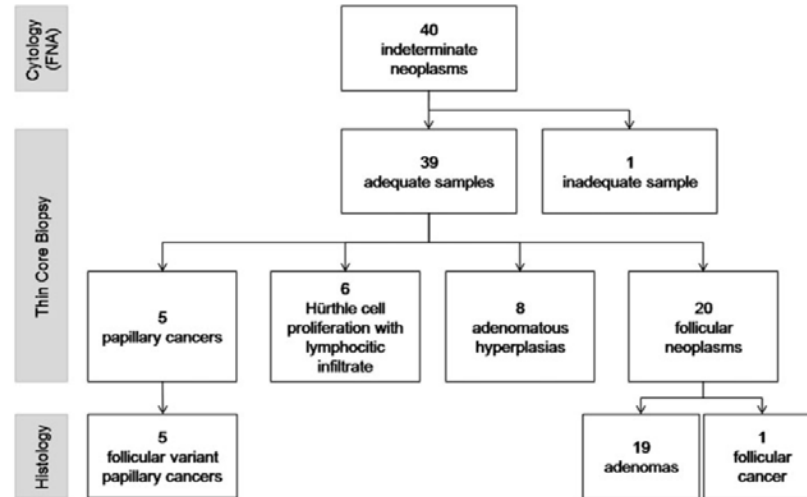
The examination of this sample allowed to discriminate encapsulated from non-encapsulated nodules, distinguishing between adenomatous hyperplasia, and truly encapsulated follicular



Core biopsy from an encapsulated nodule. The fibrous capsule (arrow) separates the neoplastic microfollicular proliferation from normal surrounding parenchyma (HE stain)



Same case tested with immunohistochemistry. The three markers of the panel resulted positive (galectin-3 immunohistochemistry)

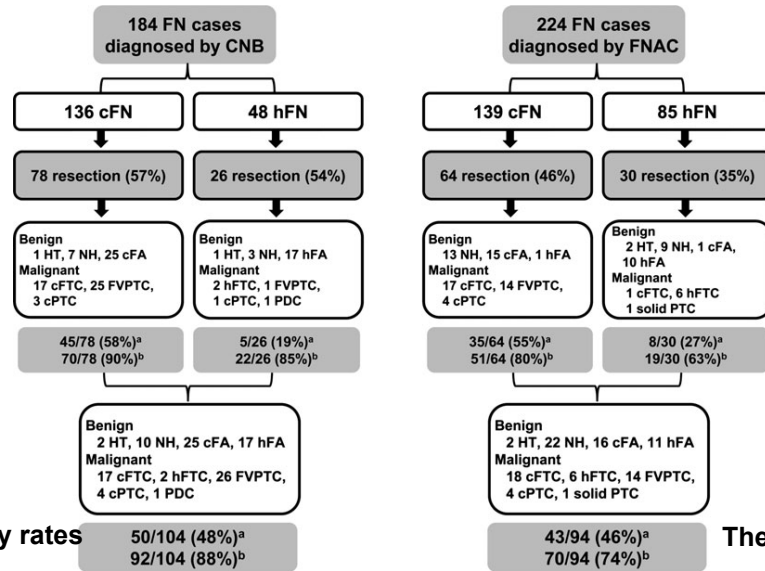




The role of core needle biopsy in the preoperative diagnosis of follicular neoplasm of the thyroid



□



The malignancy rates

The malignancy rates

Rates of malignancy and neoplasm in 184 CNB cases and 224 FNAC cases. cFN, conventional follicular neoplasm; hFN, Hurthle cell type of follicular neoplasm; HT, Hashimoto's thyroiditis; NH, nodular hyperplasia; cFA, conventional follicular adenoma; hFA, Hurthle cell type of follicular adenoma; cFTC, conventional follicular thyroid carcinoma; hFTC, Hurthle cell type of follicular thyroid carcinoma; cPTC, classic papillary thyroid carcinoma; FVPTC, follicular variant of papillary thyroid carcinoma; PDC, poorly differentiated carcinoma. A Rate of malignancy; b Rate of neoplasm.



**AMERICAN ASSOCIATION OF CLINICAL ENDOCRINOLOGISTS,
AMERICAN COLLEGE OF ENDOCRINOLOGY, AND
ASSOCIAZIONE MEDICI ENDOCRINOLOGI MEDICAL GUIDELINES FOR
CLINICAL PRACTICE FOR THE DIAGNOSIS AND MANAGEMENT OF
THYROID NODULES – 2016 UPDATE
*EXECUTIVE SUMMARY OF RECOMMENDATIONS***

4.4. Core-Needle Biopsy

- Consider the use of US-guided core-needle biopsy (CNB) in solid thyroid nodules with persistently inadequate FNA cytologic findings [BEL 3, GRADE C].
- Because of the limited evidence and lack of established reporting systems, we do not recommend either in favor of or against the use of CNB in nodules with indeterminate cytologic results [BEL 4, GRADE D].

Solid, persistently nondiagnostic nodules should be considered for US-guided CNB (198 [EL 3]) because microhistologic assessment may offer additional information to FNA in these cases (197 [EL 2], 253 [EL 3]).

CNB has been proposed in the management of the AUS/FLUS subcategory because the architectural findings and comparison with the surrounding normal thyroid tissue may provide further information (335 [EL 2]). However, the role of CNB in indeterminate lesions requires confirmation.



Core Needle Biopsy of the Thyroid: 2016 Consensus Statement and Recommendations from Korean Society of Thyroid Radiology



Table 4. Summary of Consensus Statement and Recommendations

Category	Consensus Statement and Recommendations
Indication	1. CNB could be alternative to FNA in evaluation of thyroid nodules in selected cases
Device and procedure	2. Modern CNB devices, particularly 18–21-gauge, spring-activated, core needles, are recommended for procedure
	3. Patients with bleeding tendency, such as those taking anticoagulation medications or with disorders affecting coagulation cascade, should be thoroughly evaluated and any problems corrected before CNB
	4A. CNB should be performed by experienced operators under US guidance
	4B. Manual compression of biopsy site should be performed immediately after procedure for 20 to 30 minutes
	5. CNB can be used as alternative to FNA for thyroid nodules with non-diagnostic cytology in previous FNA
	6. CNB may be used as alternative to FNA for thyroid nodules with atypia (follicular lesion) of undetermined significance in previous FNA
	7A. CNB has advantages to differentiate encapsulated follicular neoplasm from non-neoplastic nodule
Clinical outcomes	7B. CNB cannot differentiate follicular thyroid carcinoma from follicular adenoma
	8. CNB may be used as alternative to FNA for calcified thyroid nodules
	9. CNB may achieve low rates of non-diagnostic and inconclusive results for initially detected thyroid nodules. However, utility of CNB as first-line diagnostic tool for these nodules is uncertain based on current evidence
	10A. CNB can be used as alternative to FNA in patients with clinical and radiological features of uncommon malignancies (anaplastic carcinoma, lymphoma, or medullary carcinoma)
	10B. CNB can be used as alternative to FNA for thyroid nodules with US–cytology discordance in previous FNA
Complications	11. CNB is safe, well-tolerated, and associated with low incidence of complications when performed by experienced operators

CNB = core needle biopsy, FNA = fine-needle aspiration, US = ultrasound



Conclusions 1



Roma, 9-12 novembre 2017

- FNA is the procedure of choice in the evaluation of malignancy in thyroid nodules.
- The current guidelines recommend performing ultrasound guided FNA biopsy (US-FNAB) with 23- to 27-gauge needles, with or without aspiration.
- The decision to biopsy a thyroid nodule should be based upon a combination of history, physical examination, hormonal status, ultrasound (US) features.
- Ultrasound classification system should be used for assessing risk of malignancy and guiding the actions.
- At least 20% of FNA cytology are inconclusive.



Conclusions 2



- CNB is still a complementary diagnostic tool to FNA and not an alternative.
- The use of CNB may be considered in selected cases of solid thyroid nodule with persistently nondiagnostic cytology, according to the AAACE/ACE/AME Guidelines.
- CNB may have a role in AUS/FLUS (atypia or follicular lesion of undetermined significance, III BSRTC), but further studies are required.
- CNB cannot differentiate follicular carcinoma from follicular adenoma.



Thank you for your attention