


Thyroid Surgery update
AACE-17th Annual AME meeting
Rome

Sareh Parangi, M.D., FACS
Professor of Surgery
Massachusetts General Hospital
Endocrine Surgery Unit
Division of General and Gastrointestinal Surgery

sparangi@partners.org

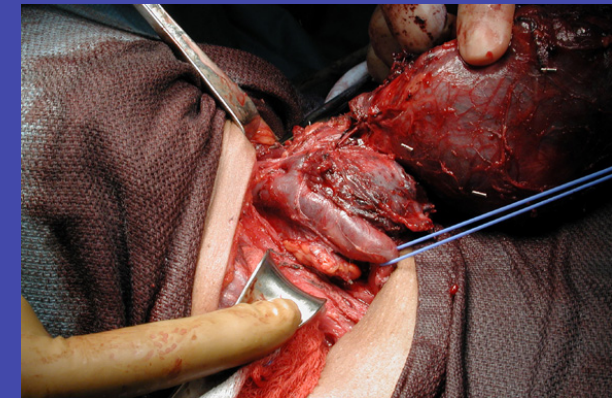
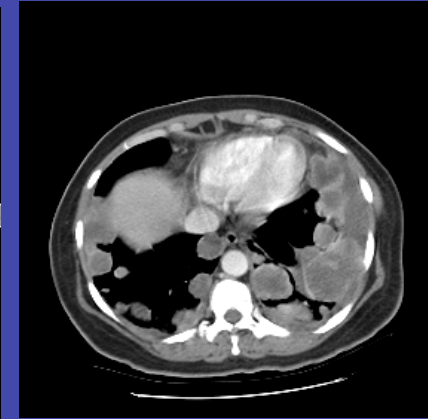
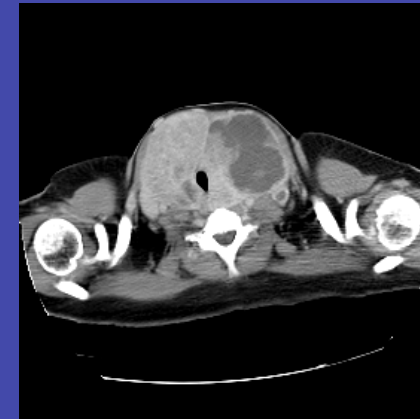
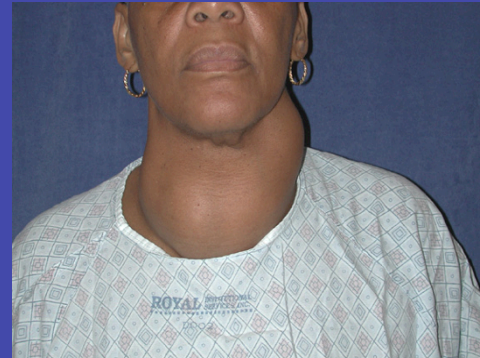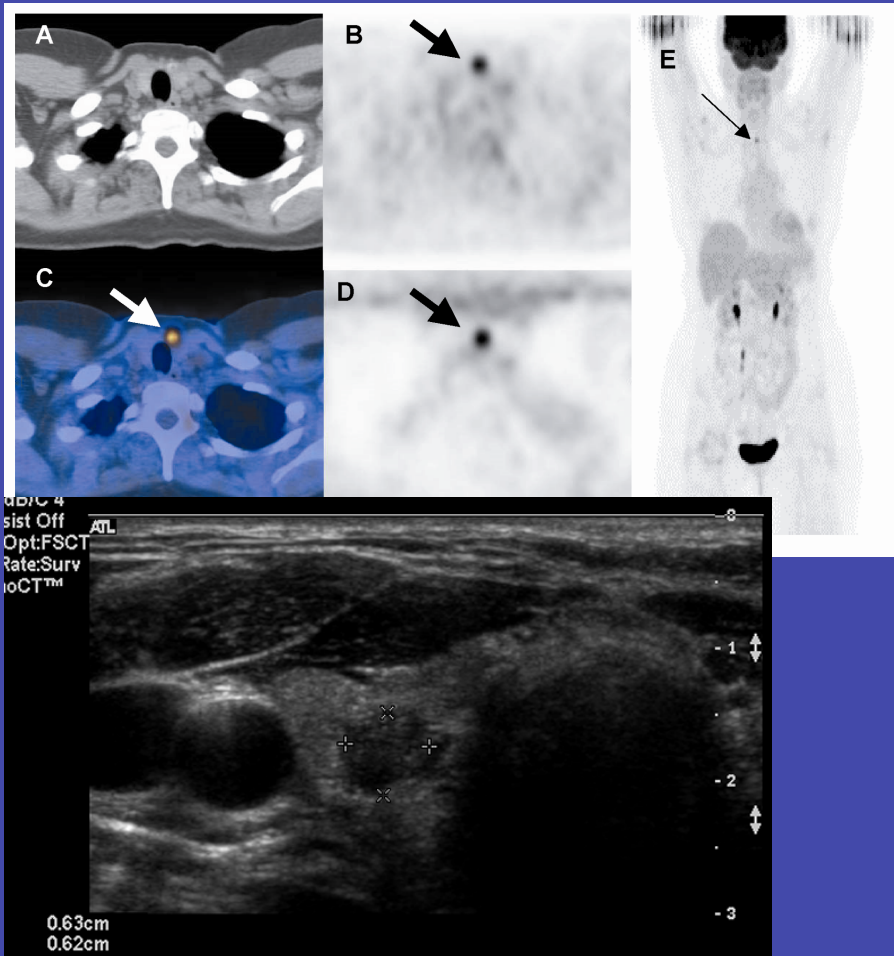
No disclosures



Overview

- Spectrum of thyroid cancers treated by surgeons
 - Non medullary thyroid cancers
- Basic cases presented focusing on
 - **Doing the right operation the first time**
 - What about using molecular tests to decide on extent of surgery
 - Mindset and tools help you do the right operation
 - Where does nerve monitoring really help?
 - **What to do when recurrences happen**
 - Spectrum of treatments for thyroid cancer recurrences
 - Monitoring/Ablation/RAI treatments
 - Surgical intervention
 - Oncology/XRT
 - Could the recurrence have been predicted?
 - **Where are we with very advanced thyroid cancers**
 - Neoadjuvant therapy?
- Summary

Spectrum of thyroid cancer treated by surgeons



Most of these patients are going to do great 😊
Should they even have surgery??
Perhaps observation or ablative techniques

Most of these patients are going to do badly
Should they ever have surgery?
Maybe after neoadjuvant treatment- Not really covered here

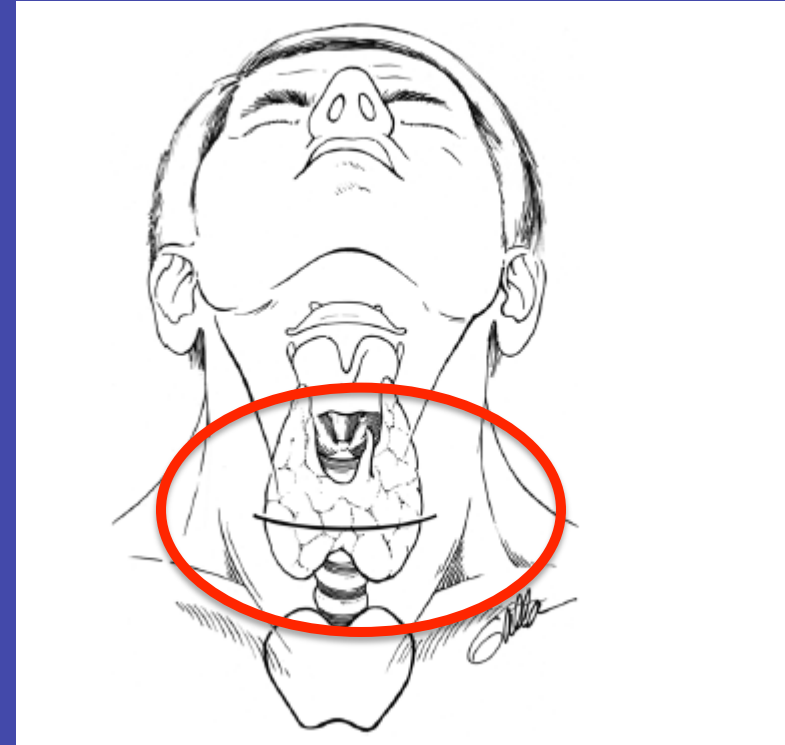
Basic principles I follow

- **Make the patient happy**
 - Does not want to die of thyroid cancer
 - Does not want a complication
 - Does not want a recurrence
 - Does not like surprises
 - Wants a straightforward smooth recovery
- **Make the referring endocrinologist happy**
 - Does not want a complication
 - Does not want a recurrence
 - Wants you to operate within your safety zone
 - Be Brave- sometimes that means referring out
 - Keep open lines of communication
- **Follow guidelines/study patients/keep up on literature**
 - Do not become a technician or RVU driven
 - Don't make things too complicated

Doing it right the first time- do the right operation on thyroid

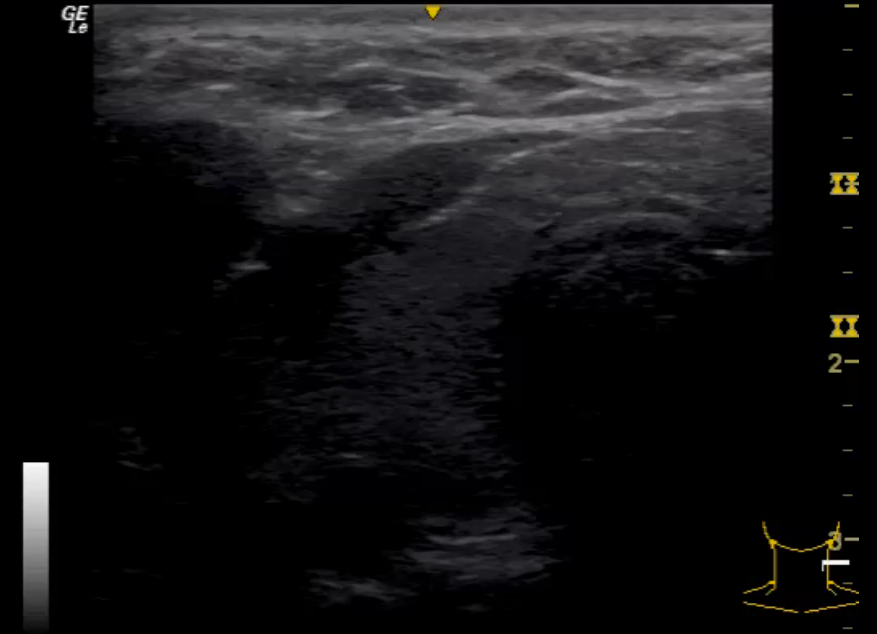
Male 6 cm PTC on FNA

- Can I do a total thyroidectomy safely?
 - Is tumor fixed?
 - Is patient hoarse?
- Did I do the US myself?
 - Does it look terrible on US?
 - Are there positive lateral nodes?
 - TG on nodes
- Have I looked at any other imaging carefully?
- Do I have help if I need it?
- Did I talk to the patient?



How can we do it right the first time?

- 40 yo female with one left sided 2 cm suspicious nodule on FNA
- BRAF positive (Afirma/Thyroseq)
- **Surgical options discussion:**
 - Left hemithyroidectomy
 - Total thyroidectomy
 - What to do with central nodes?



VIDEO

Basic principles I follow-

Do it right the first time with excellent cosmesis

Recurrence rates will be lower if done right the 1st time

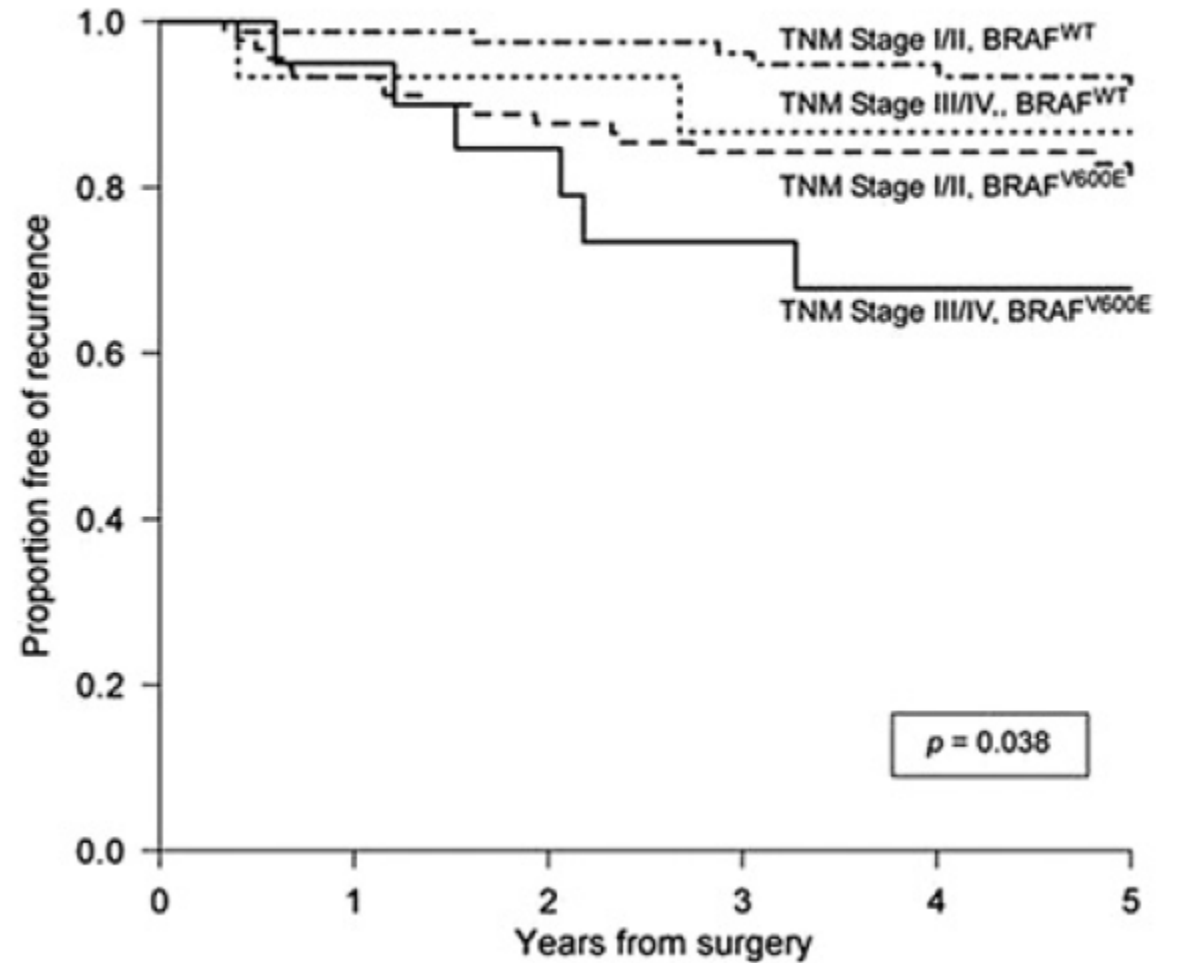
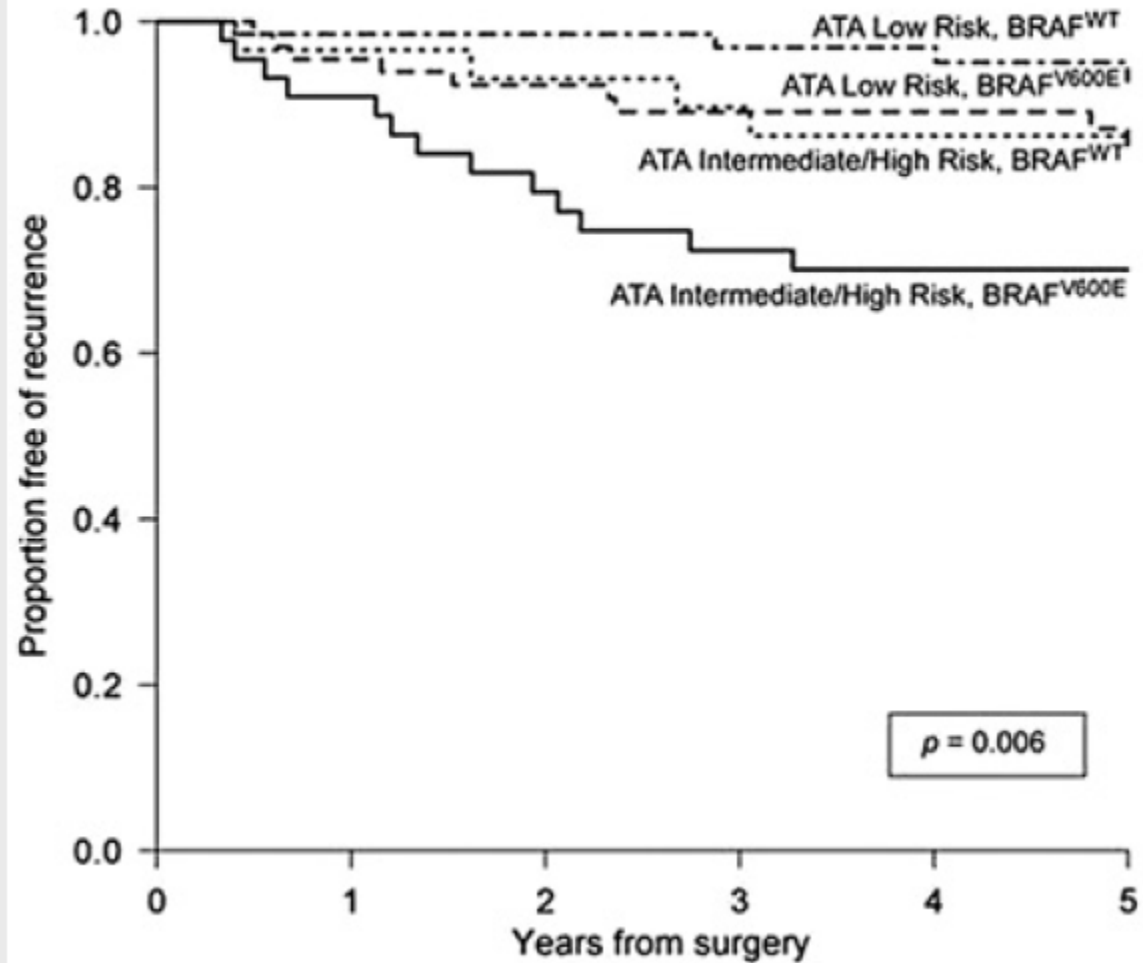
Careful preoperative workup & preparation is very important

- Identify high risk patients upfront using all available tools
 - Molecular tools ? Do I understand these?
 - US as a tool of the surgeon? Did I look myself?
- Did I map the nodal disease?
 - Do I have a plan in place if I find nodes during surgery
- Be kind to your patients
- Talk about risks
- Ask your patients what they prefer
- Ask your endocrinologist what they prefer
- Be prepared, have help



First operation- Surgeons should pay attention to mutation status

Recurrence of PTC higher in BRAF^{V600E}



First operation- Surgeons should pay attention to mutation status

Recurrence of PTC higher in BRAF^{V600E} +TERT

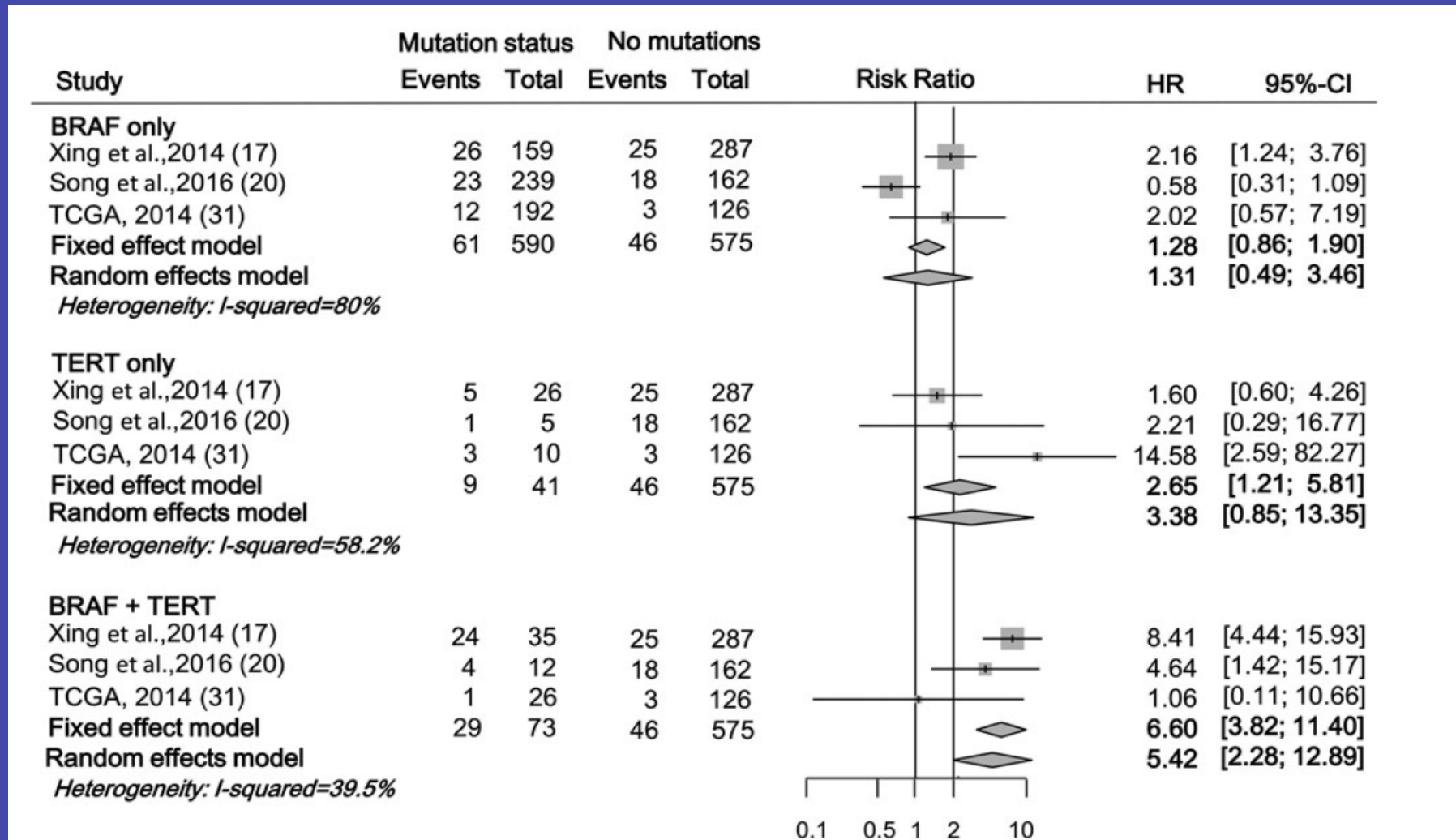


FIG. 4. Forest plot showing individual and pooled hazard ratios of the recurrence of papillary thyroid carcinoma (PTC) in *BRAF^{V600E}* or *TERT* promoter mutation or their coexistence in comparison to no mutations with the adjustment for age at diagnosis and sex.

First operation- pay attention to combinations of mutations

Mortality of PTC higher in BRAF^{V600E} +TERT

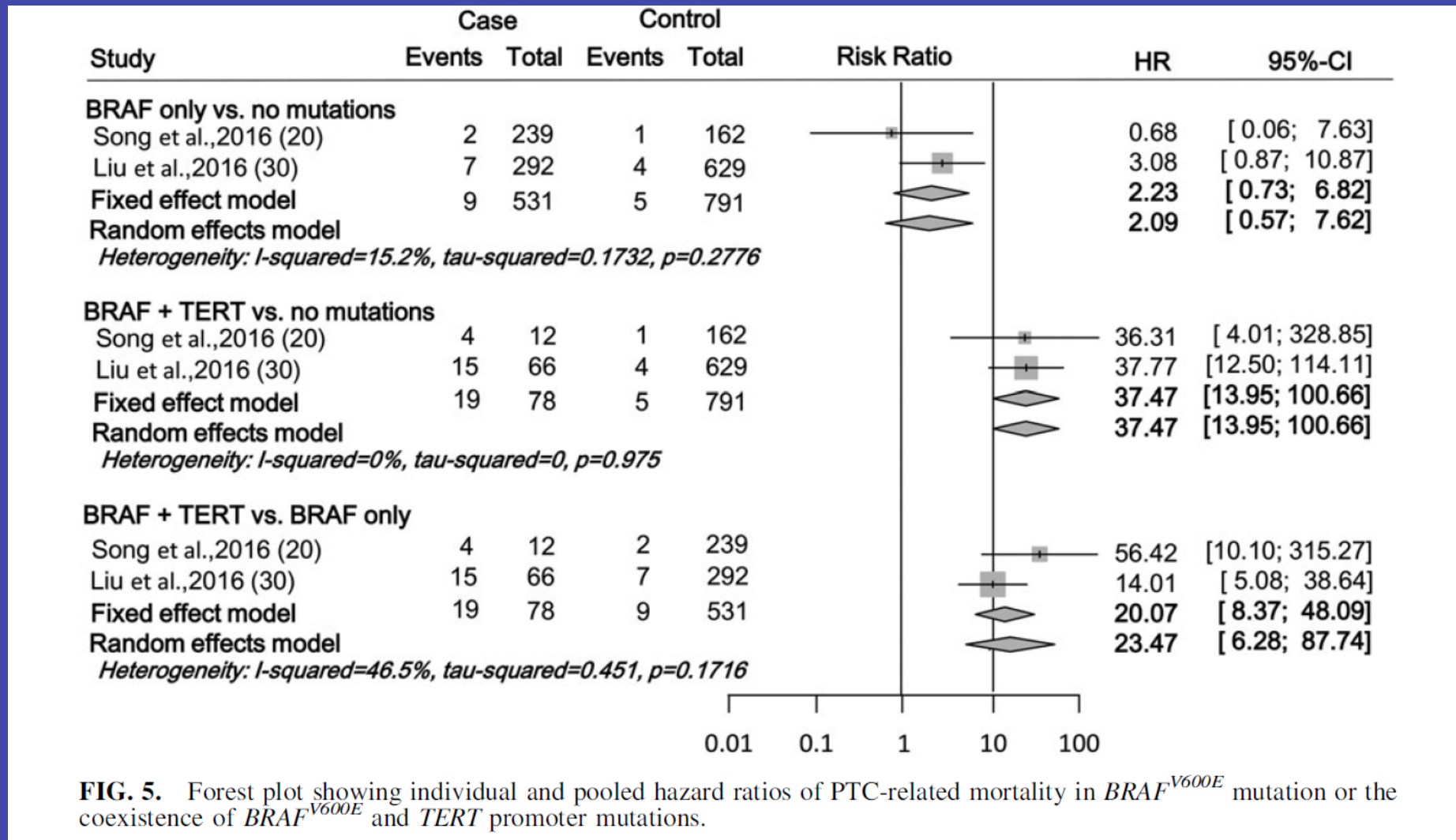
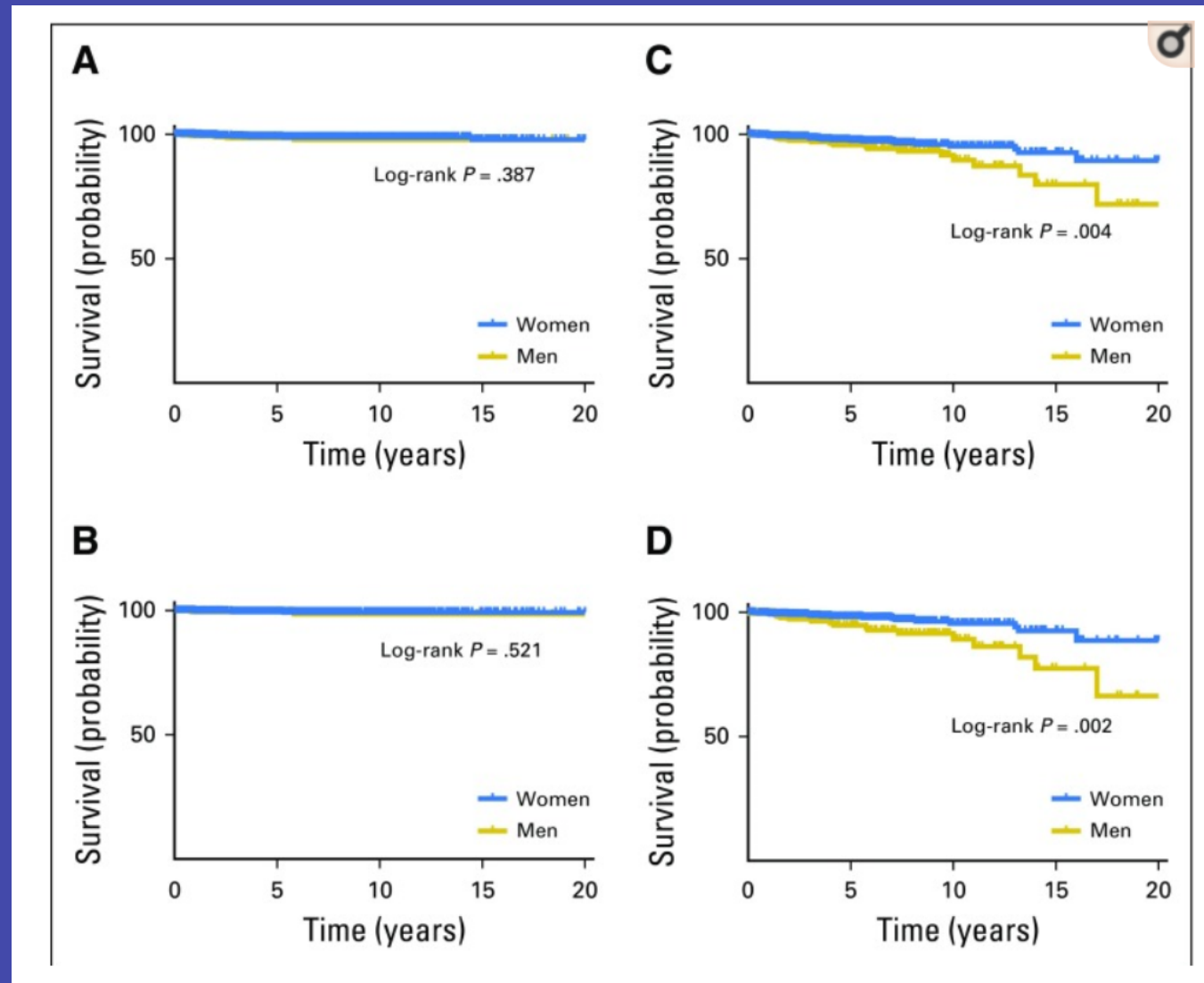


FIG. 5. Forest plot showing individual and pooled hazard ratios of PTC-related mortality in BRAF^{V600E} mutation or the coexistence of BRAF^{V600E} and TERT promoter mutations.

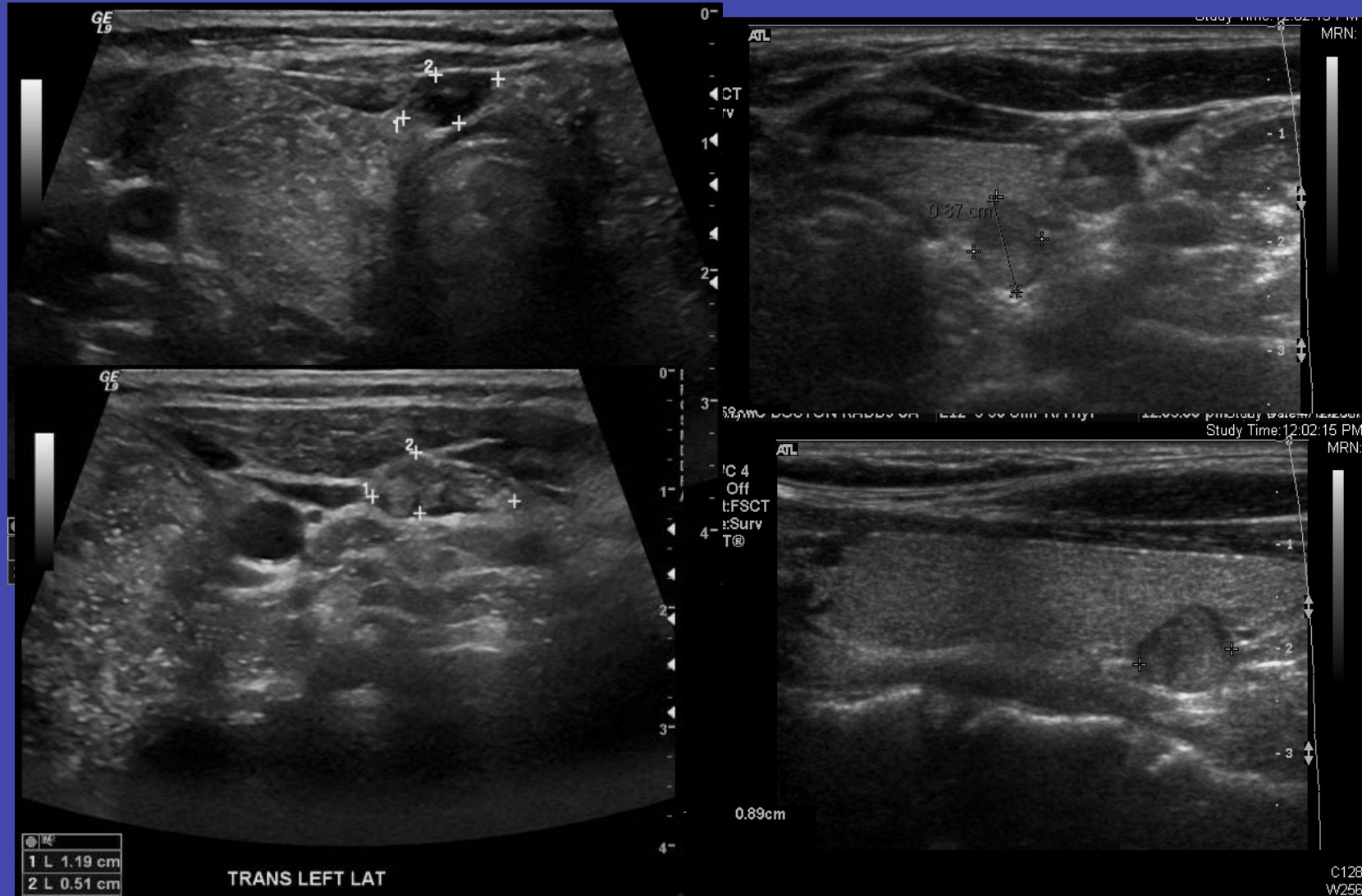
First operation- Surgeons pay attention to mutation status & age

Survival of PTC lower in men with BRAF^{V600E}



First operation- Surgeons pay attention to the details of the ultrasound

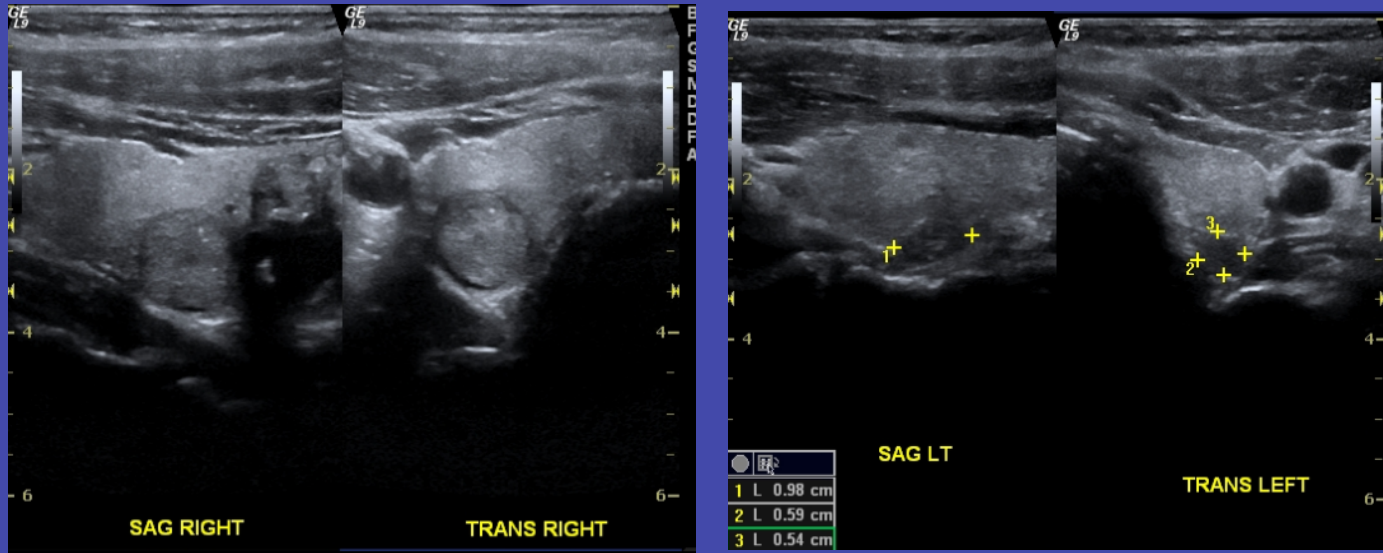
Tissue invasion by tumor cells- extrathyroidal extension



Posterior lesion or disrupting thyroid fascial planes on thyroid at insertion of nerve- Use US

First operation: Recognize abnormal nodes!!

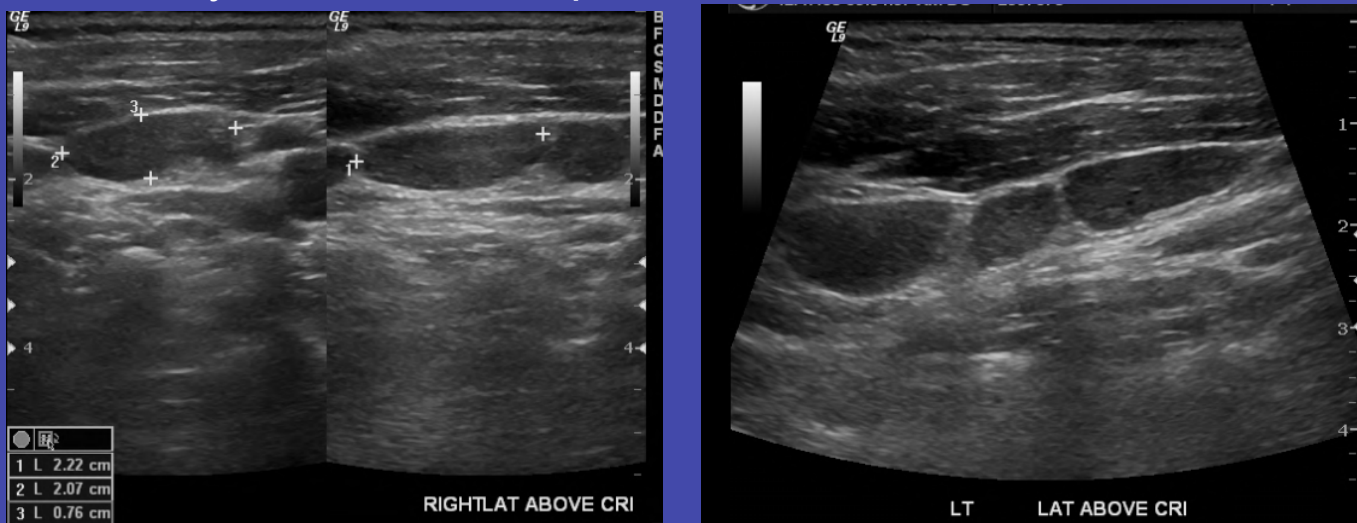
Use US and TG testing to recognize involve lateral nodes (and recognize if not thyroid cancer)



Next step ?

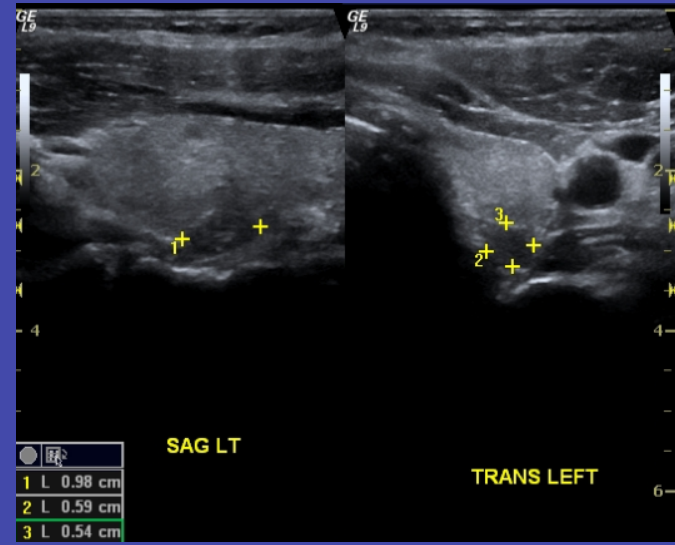
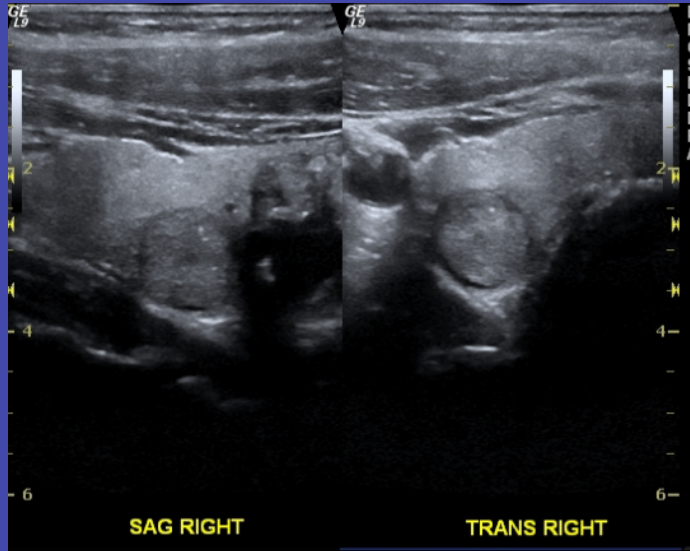
- Total thyroidectomy
- Central node dissection
- ? What to do with lateral nodes

FNA R. thyroid nodule: susp for PTC



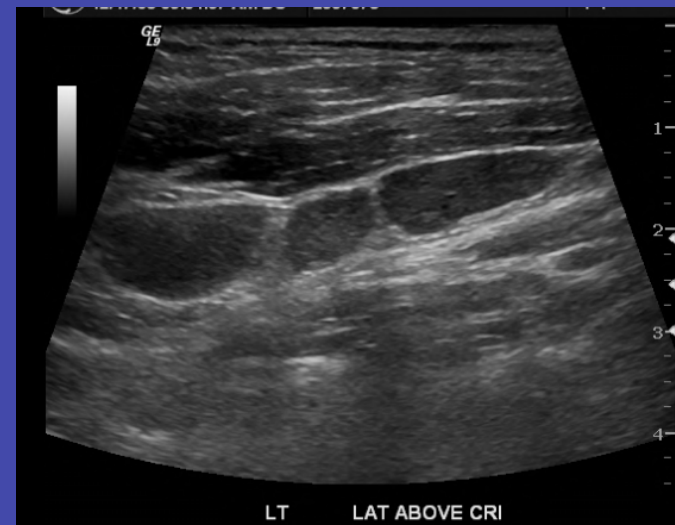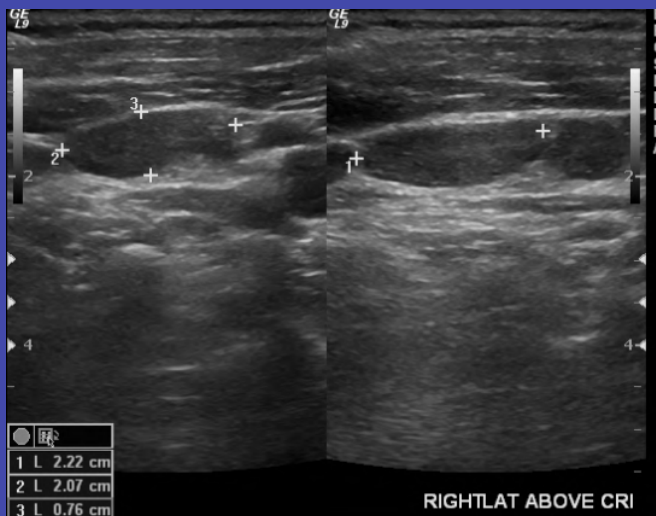
Nodes tested FNA negative, TG negative

First operation: Recognize abnormal nodes!!



Right thyroid 3 cm follicular adenoma with fibrosis and hyalinization, 1 mm PTC

Left thyroid, 1.1 cm PTC, tumor infiltrates into surrounding tissue with satellite lesions



Central nodes: 2/14 positive for PTC

IJ nodes 17 nodes negative for PTC, involved with B-cell chronic lymphocytic leukemia / small lymphocytic lymphoma

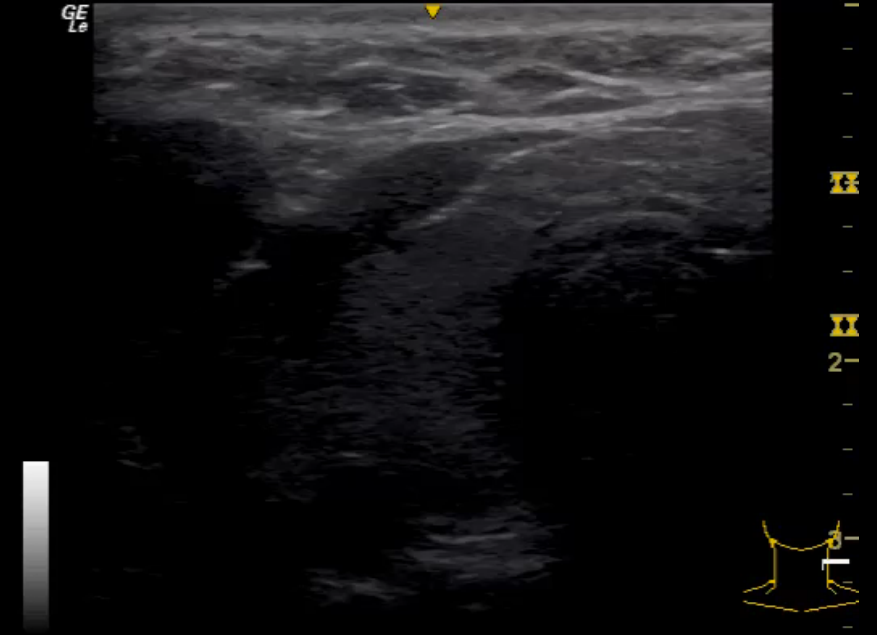
Why?

- Keeps everyone happy
- Both malignancies recognized, treatment choices affected as well

Back to our patient

How can we do it right the first time?

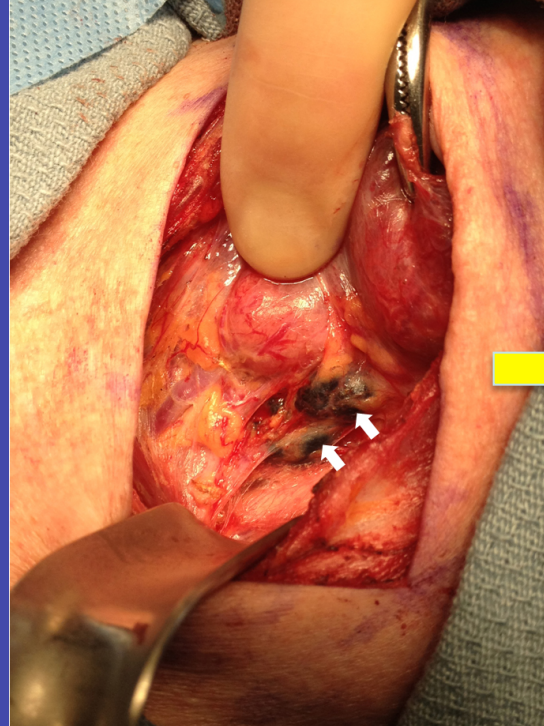
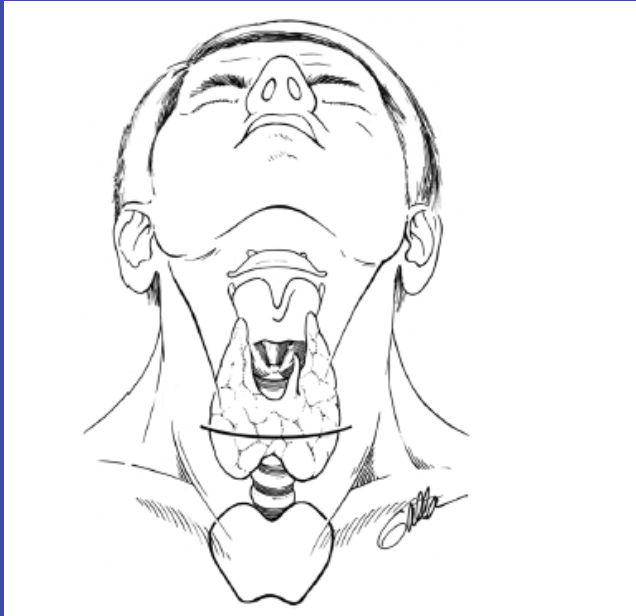
- 40 yo female with one left sided 2 cm suspicious nodule on FNA
- BRAF positive (Afirma/Thyroseq)
- Re US by surgeon:
 - No central nodes
 - Nodule not in a bad place by US
- **Surgical options discussion:**
 - Left hemithyroidectomy
 - Total thyroidectomy
 - What to do with central nodes?



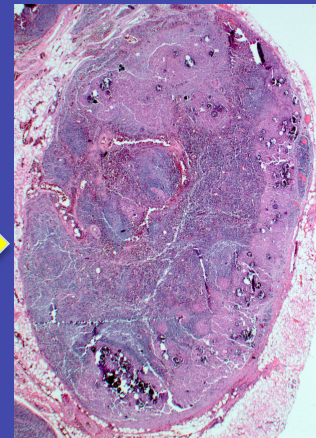
VIDEO

First operation- do a complete job and pay attention to NODES

- Hemithyroidectomy
 - +/- central node dissection
 - +/- Nerve monitoring- SLN and RLN monitoring



Left lobectomy near complete
Multiple green nodes found
posterior to nerve



Frozen section
positive for PTC

- Do a complete central node dissection
- Finish left lobectomy, vagal signal of nerve intact
- Consider a total thyroidectomy
 - Preop discussion so important

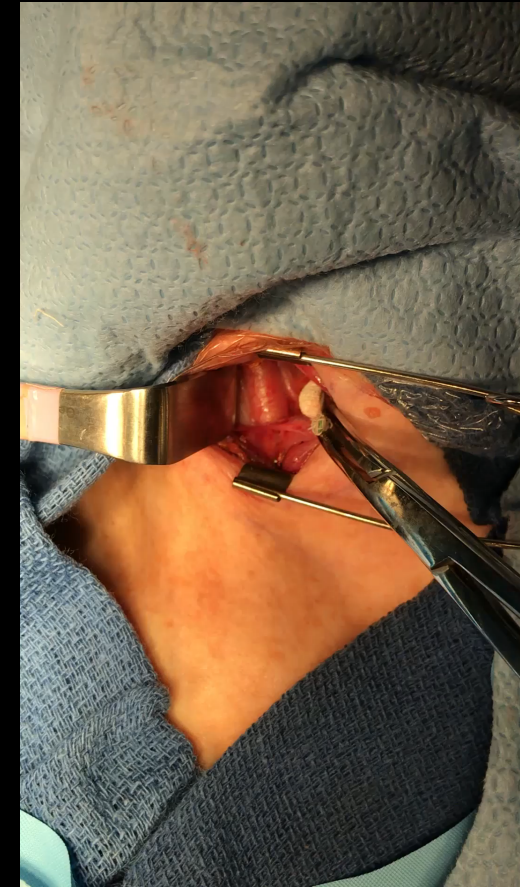
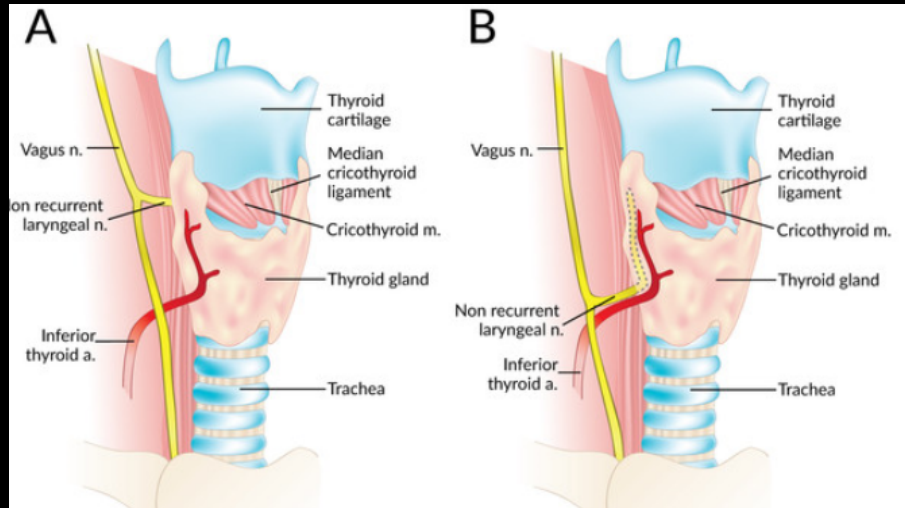
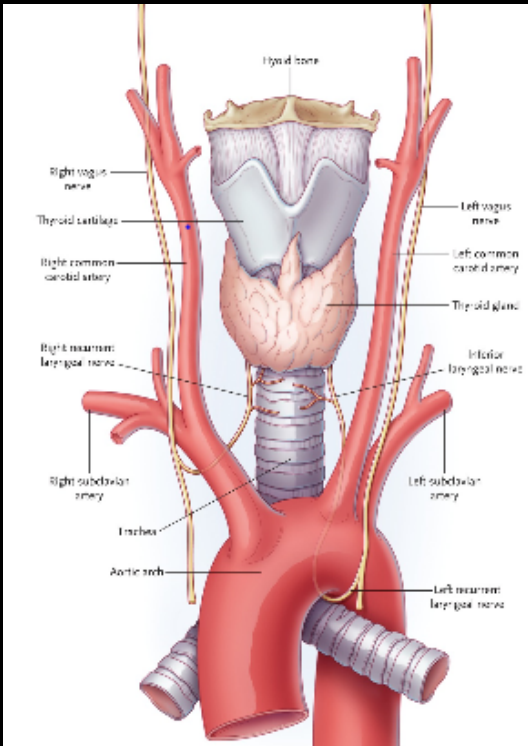
Why? Patients don't like surprises or need for more surgery

First operation- good voice = happy patient

Surgeons should recognize aberrant anatomy

Nerve monitoring

- Recognition of non recurrent RLN on right (US can be used too)



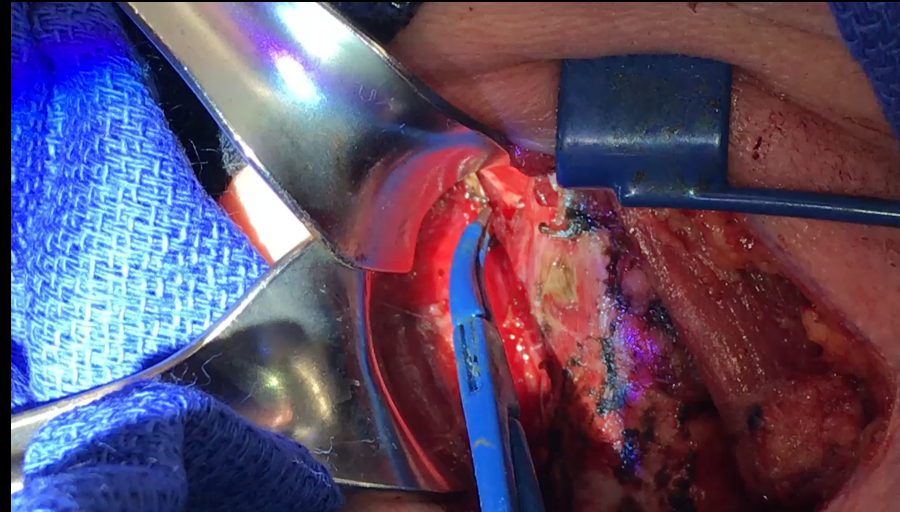
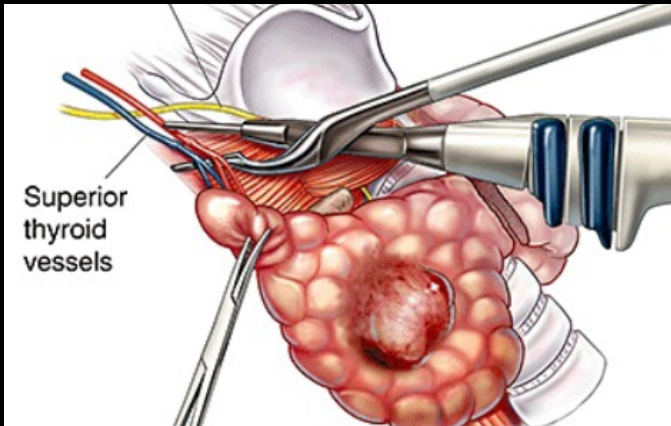
VIDEO

Why? Normal voice keeps everyone happy

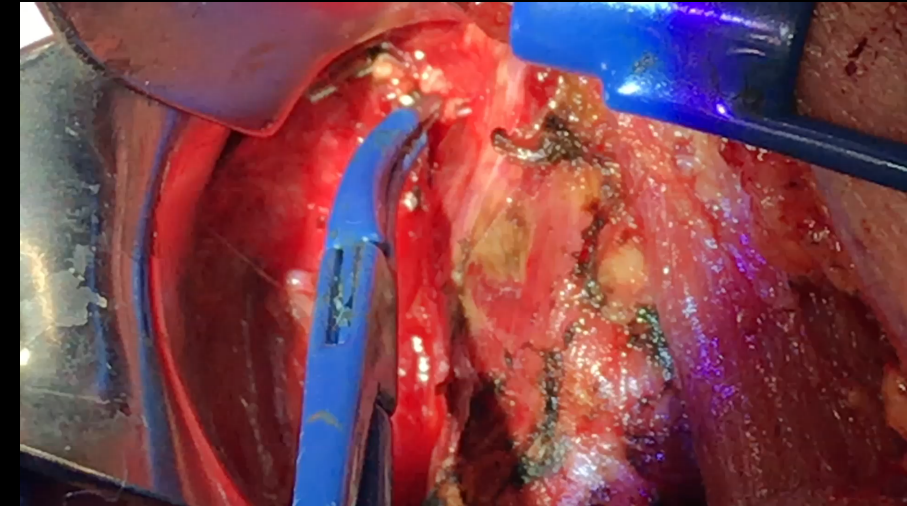
First operation- great voice = VERY happy patient

Nerve monitoring

- Superior laryngeal nerve- External branch



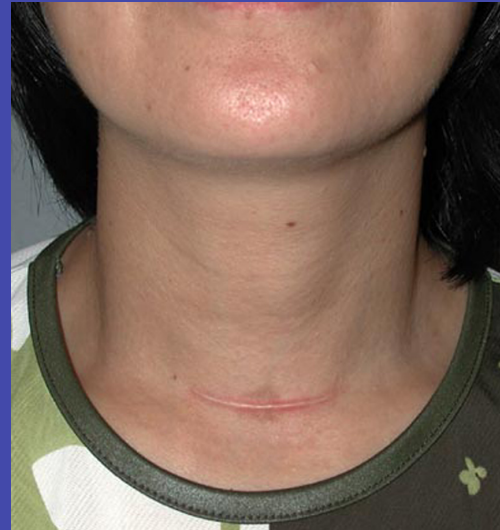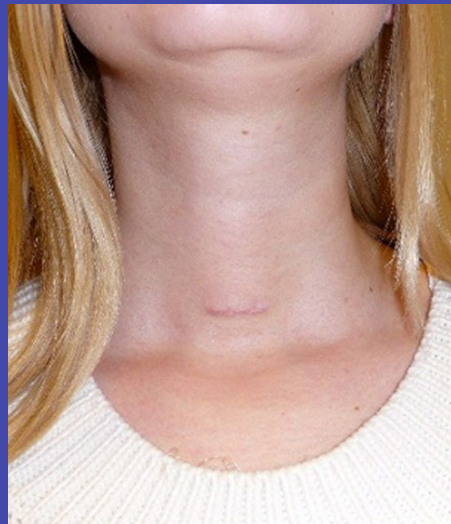
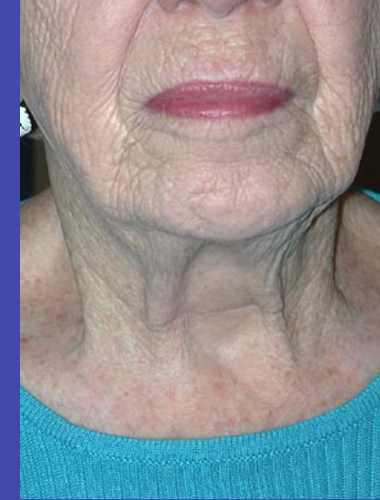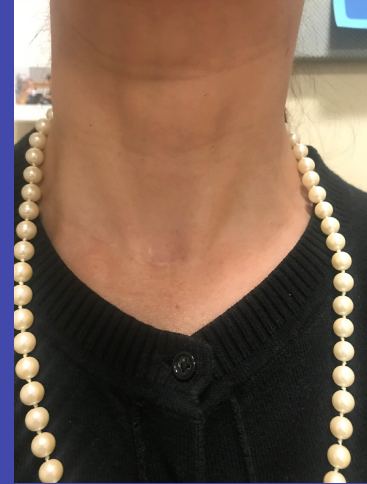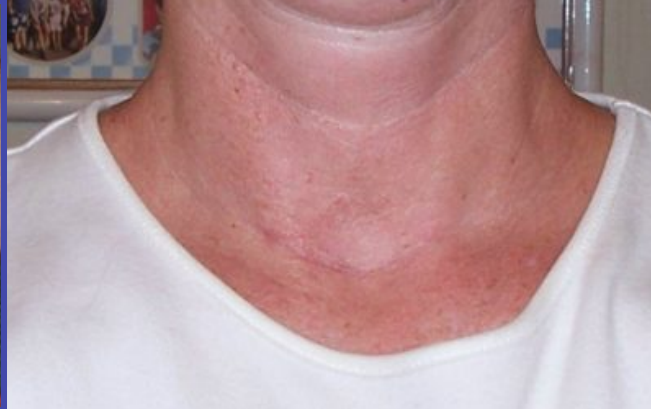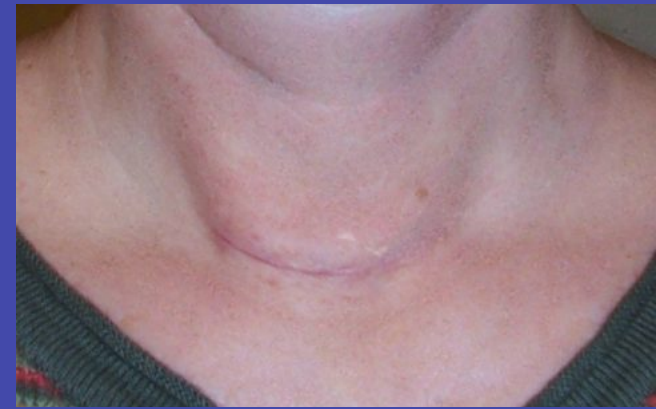VIDEO



VIDEO

Why? Full range of voice keeps everyone happy

First operation
Good cosmetic result– happy patient



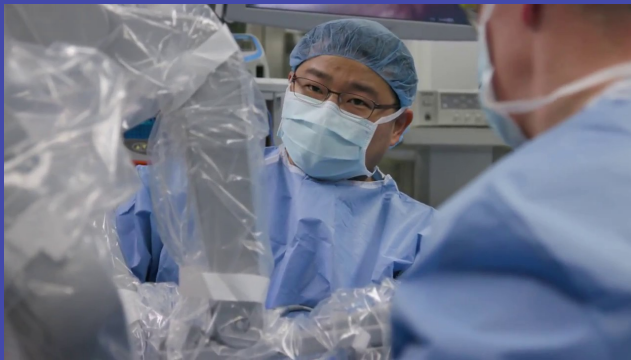
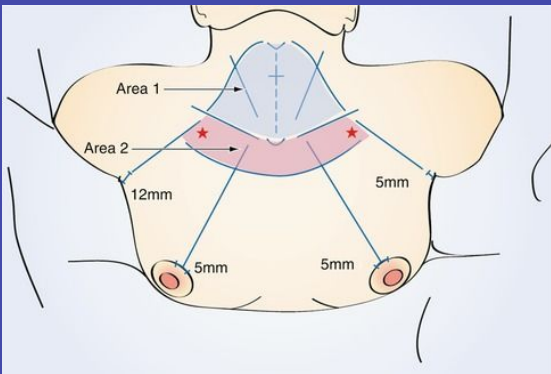
Alternatives for even better cosmesis

Onco-plastic surgery- alternate sites for incisions

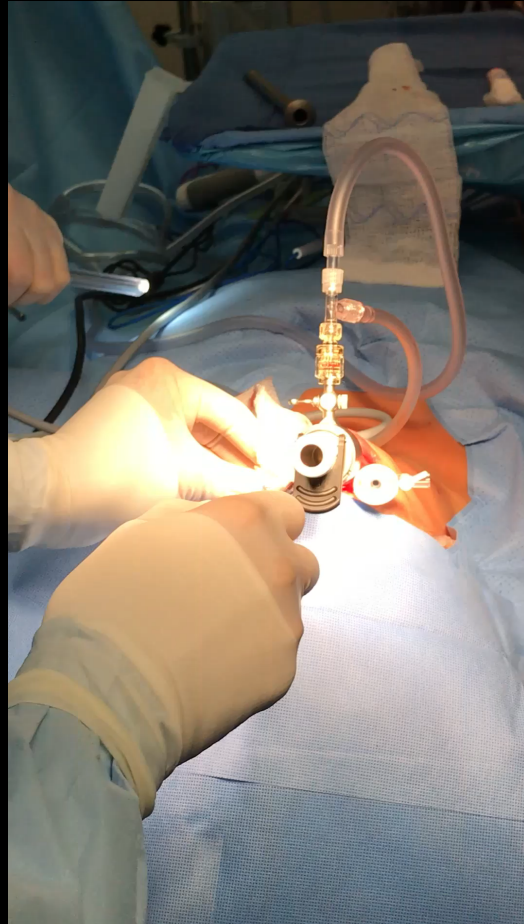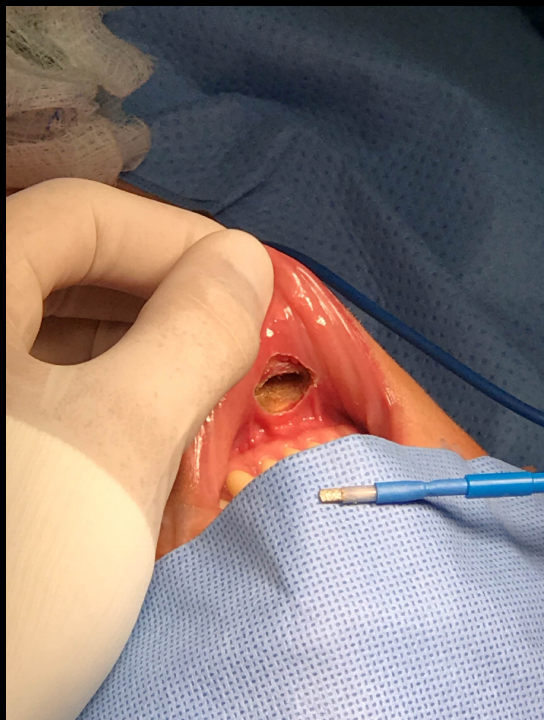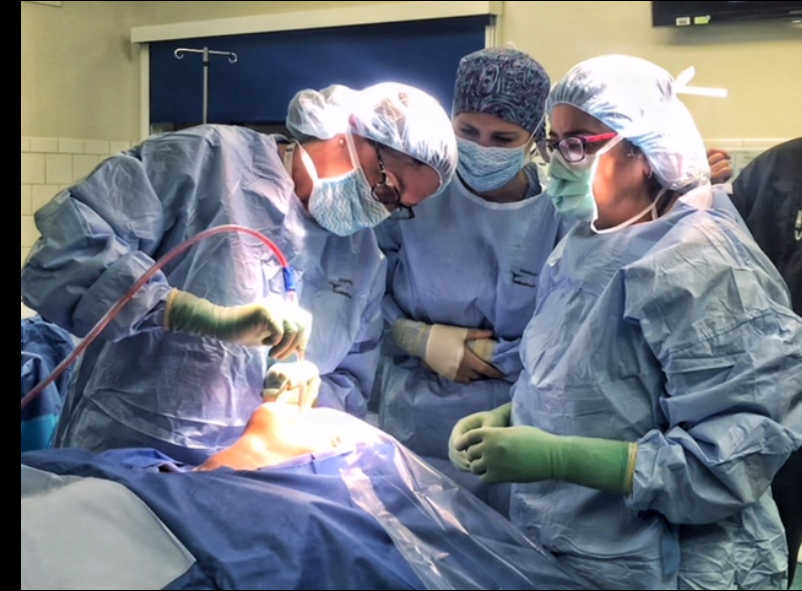Thyroidectomy with no neck scar
"Oncoplastic" thyroid surgery
Popularized in the far east
Two approaches:

BABA
bilateral axilla breast approach
Korea

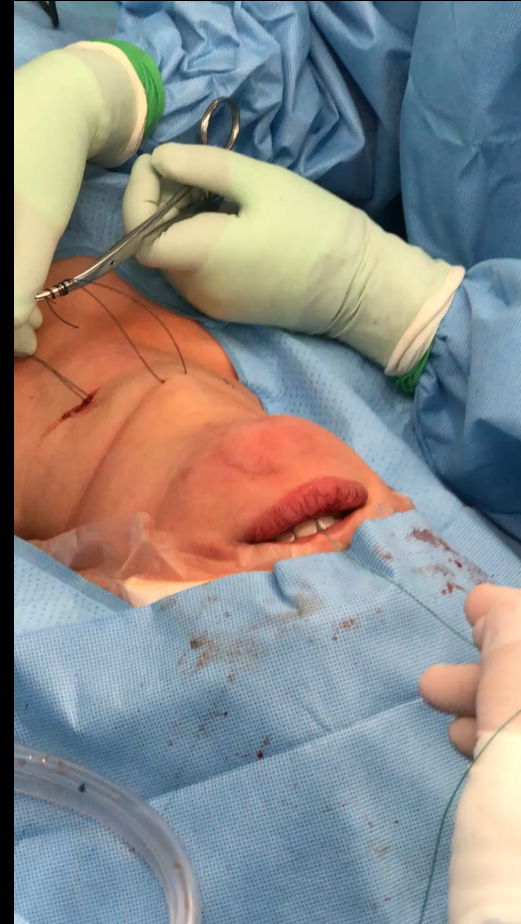TOETVA
transoral endoscopic
thyroidectomy vestibular approach
Thailand



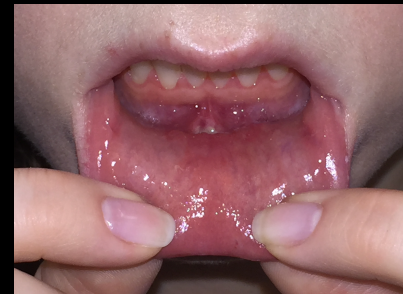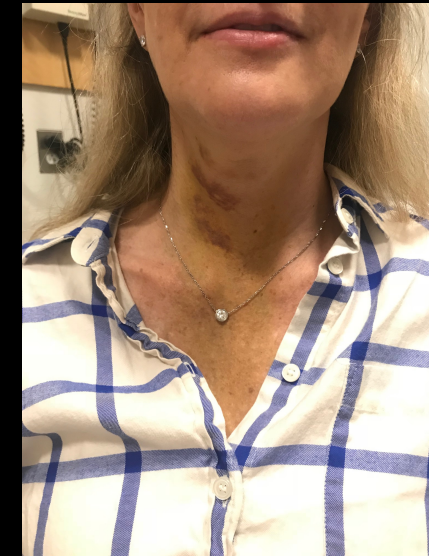TOETVA
transoral endoscopic
thyroidectomy vestibular approach
Thailand



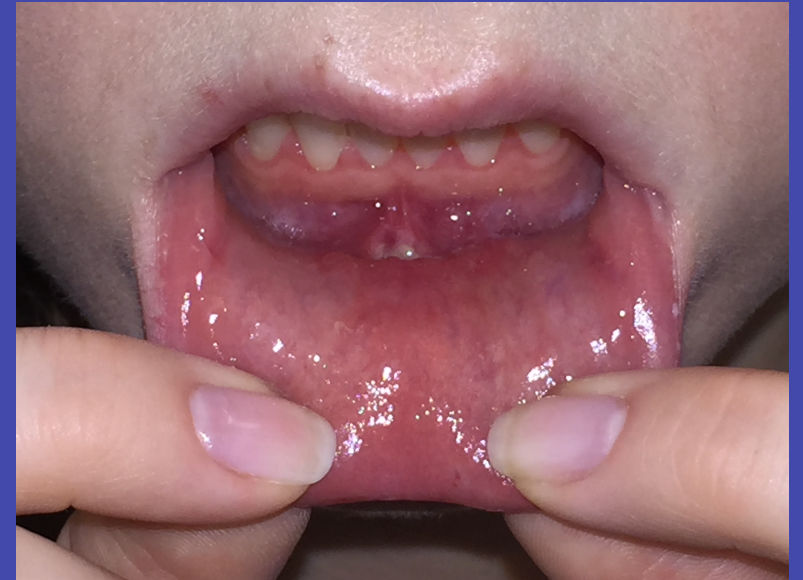VIDEO



VIDEO



Cosmetic Outcome



Training for a new procedure as an established practitioner



April 2017
AAES meeting
Orlando, FL

December 2017
Cadaver and lecture course
Mt Sinai, NY

May 2018
1st TOETVA at
MGH
Boston, MA


July 2018
2nd TOETVA at MGH
Boston, MA




June 2017
Lectures and Live Surgery
Mt Sinai, NY
Yale, CT

May 2018
Observe in
OR
Mt Sinai, NY

June 2018
Observe at Yale
New Haven, CT



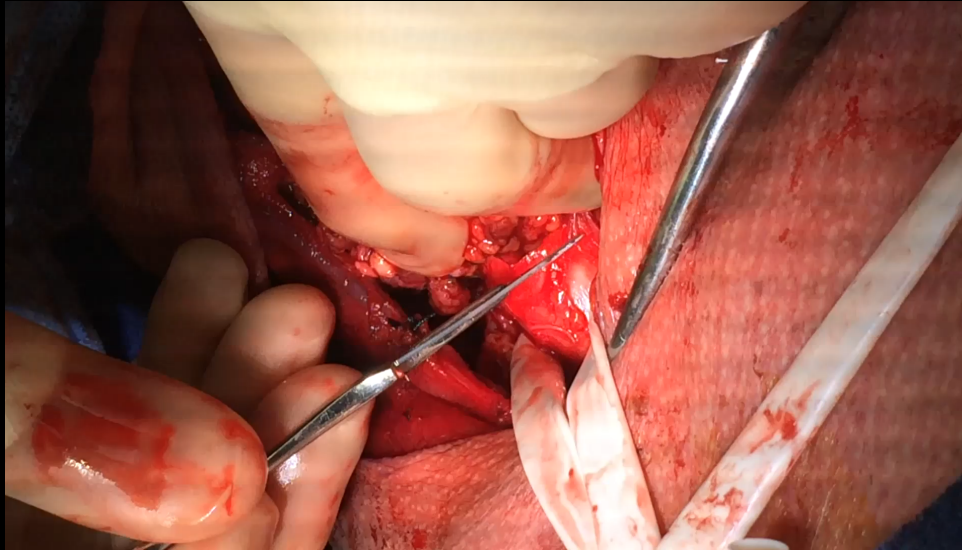
Assembled MGH team
Obtained permission
Reviewed equipment list
Budget and credentialing



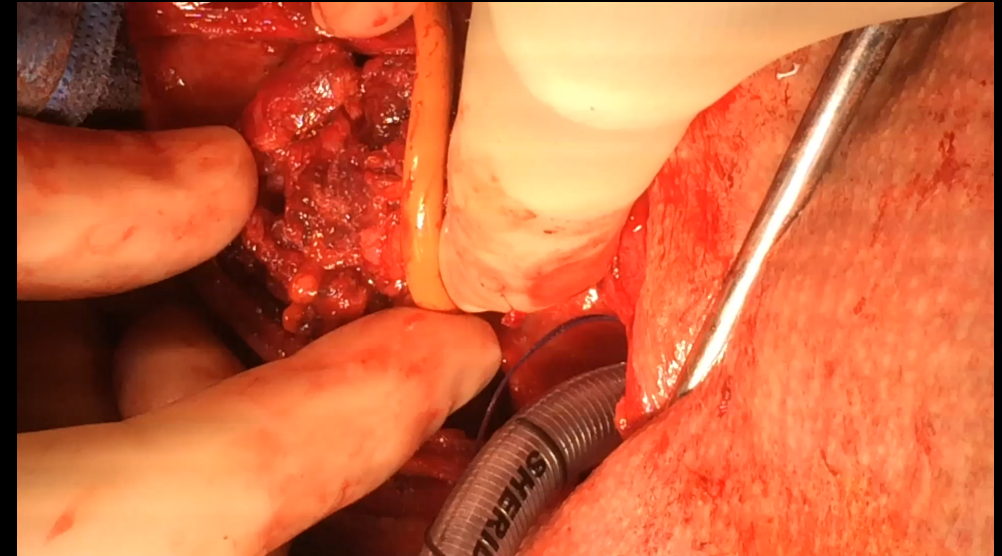
- Advertising and patient recruitment
- Track outcomes and engage in registries
- Continued education
- Continue to ensure that innovation benefits patients and their values, not those of the surgeon

First operation: Ask for help -you will never regret it

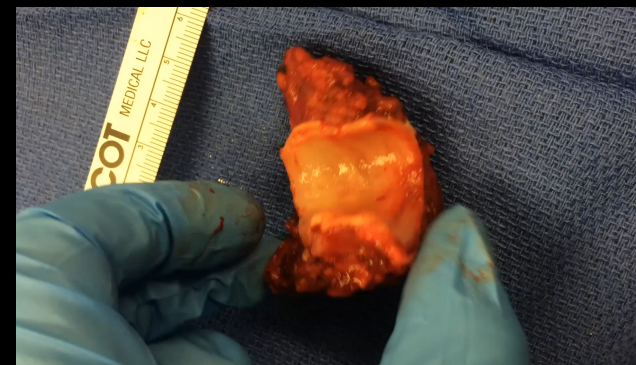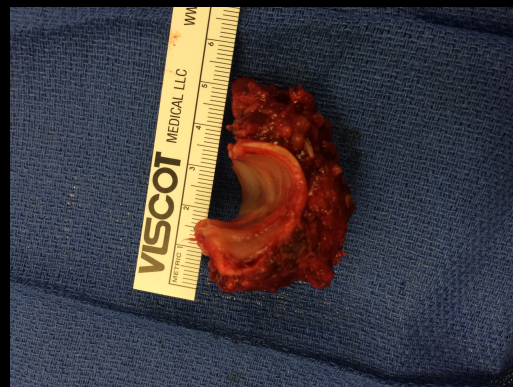- Resectable but has involvement of surrounding vital structures
 - Trachea, esophagus



VIDEO



VIDEO

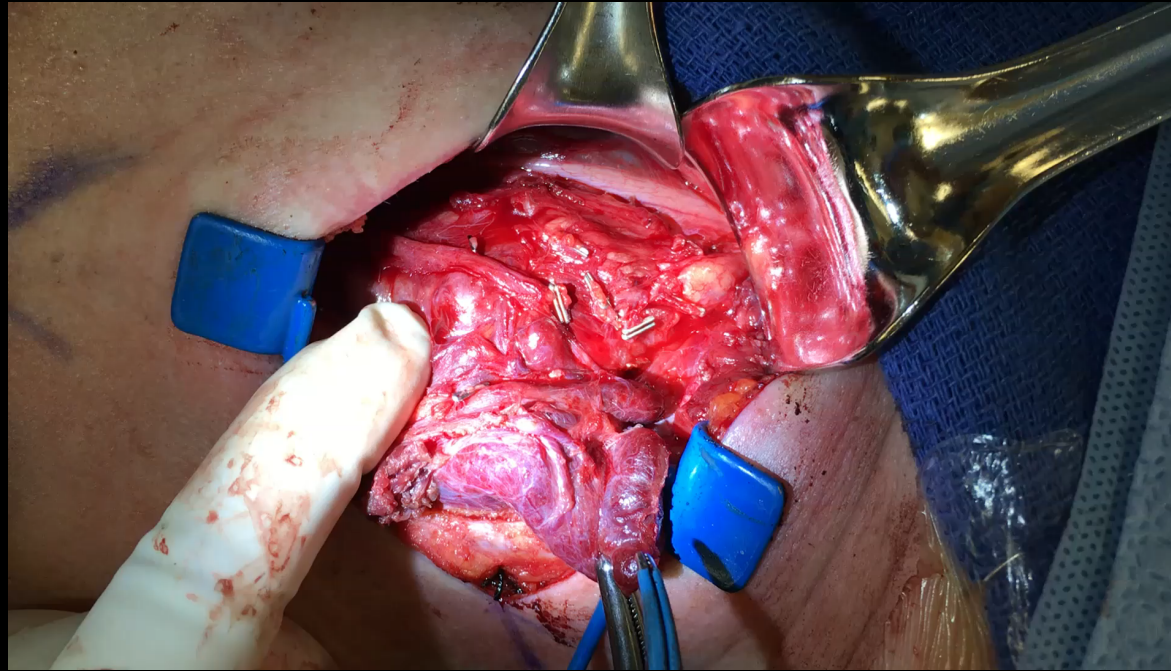
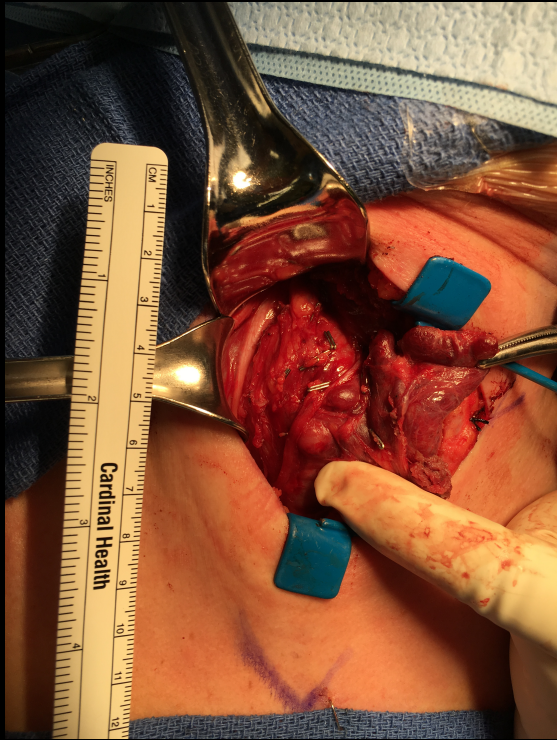


VIDEO

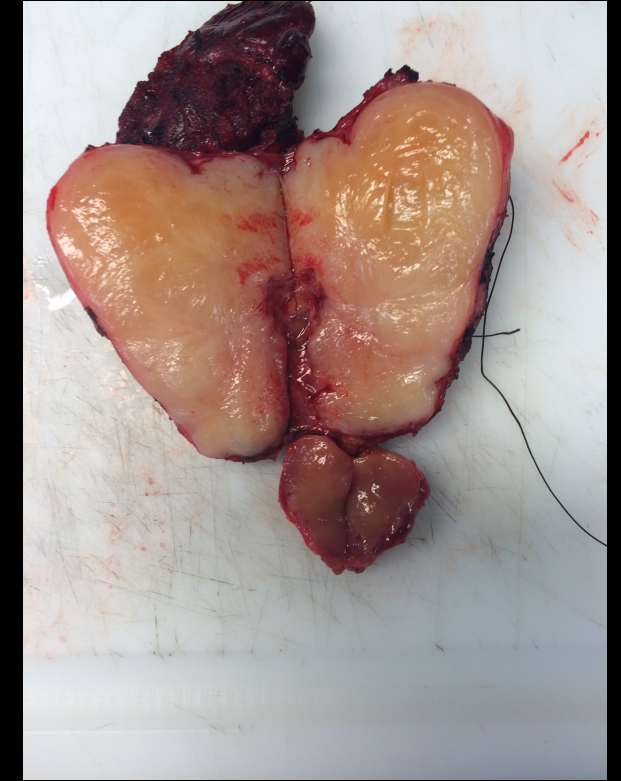
Primary cases- now more complex

My advice- you will never regret getting help

- Resectable but has involvement of surrounding vital structures
 - Trachea, esophagus

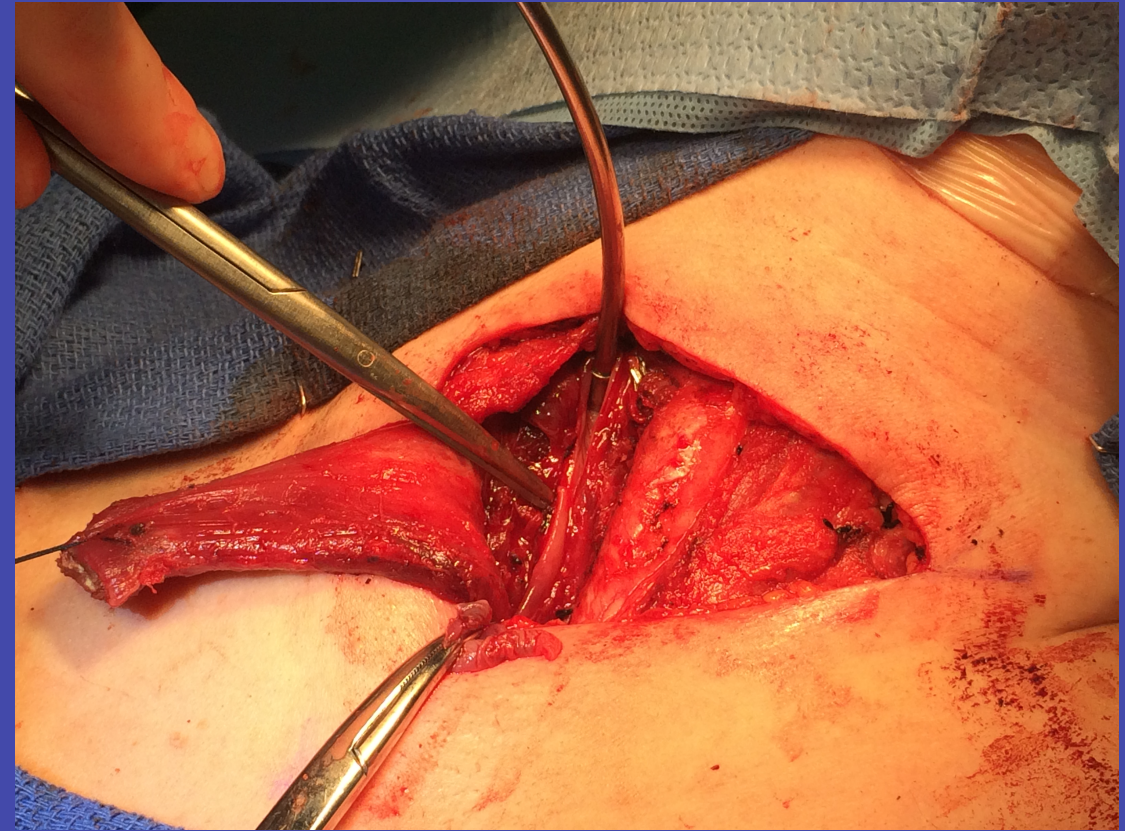
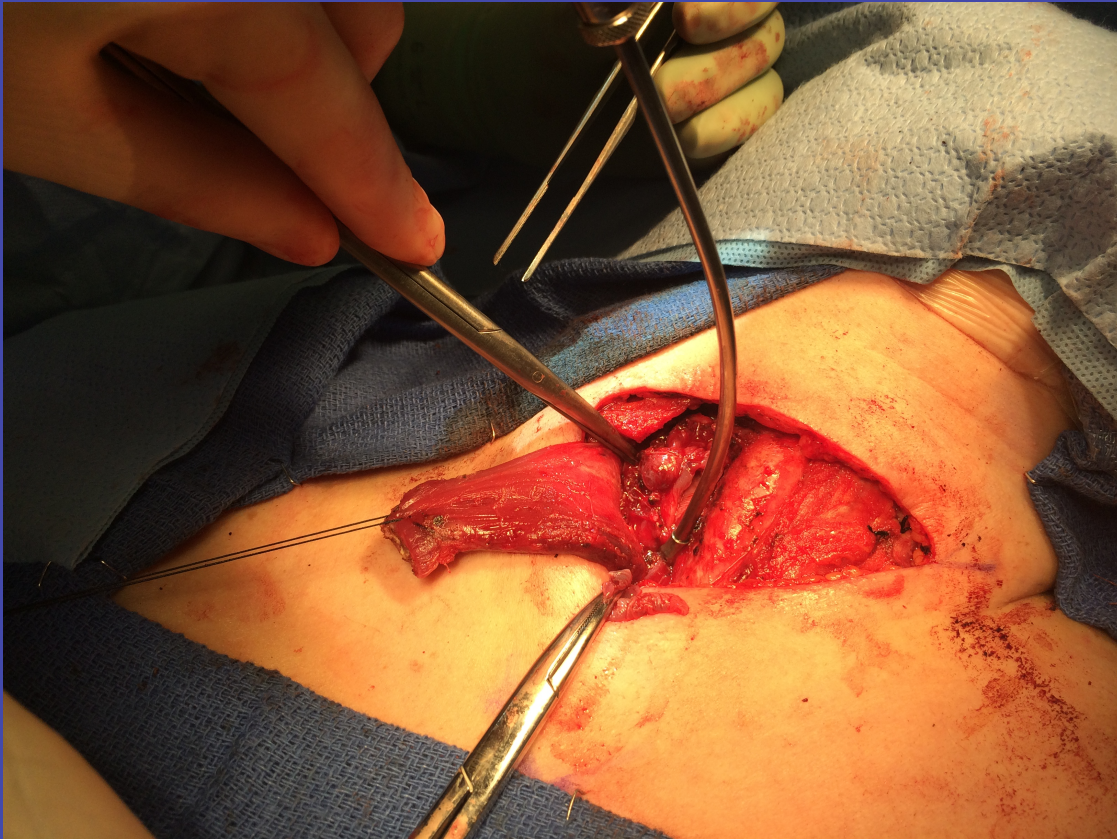


VIDEO



First operation: My advice- you will never regret getting help

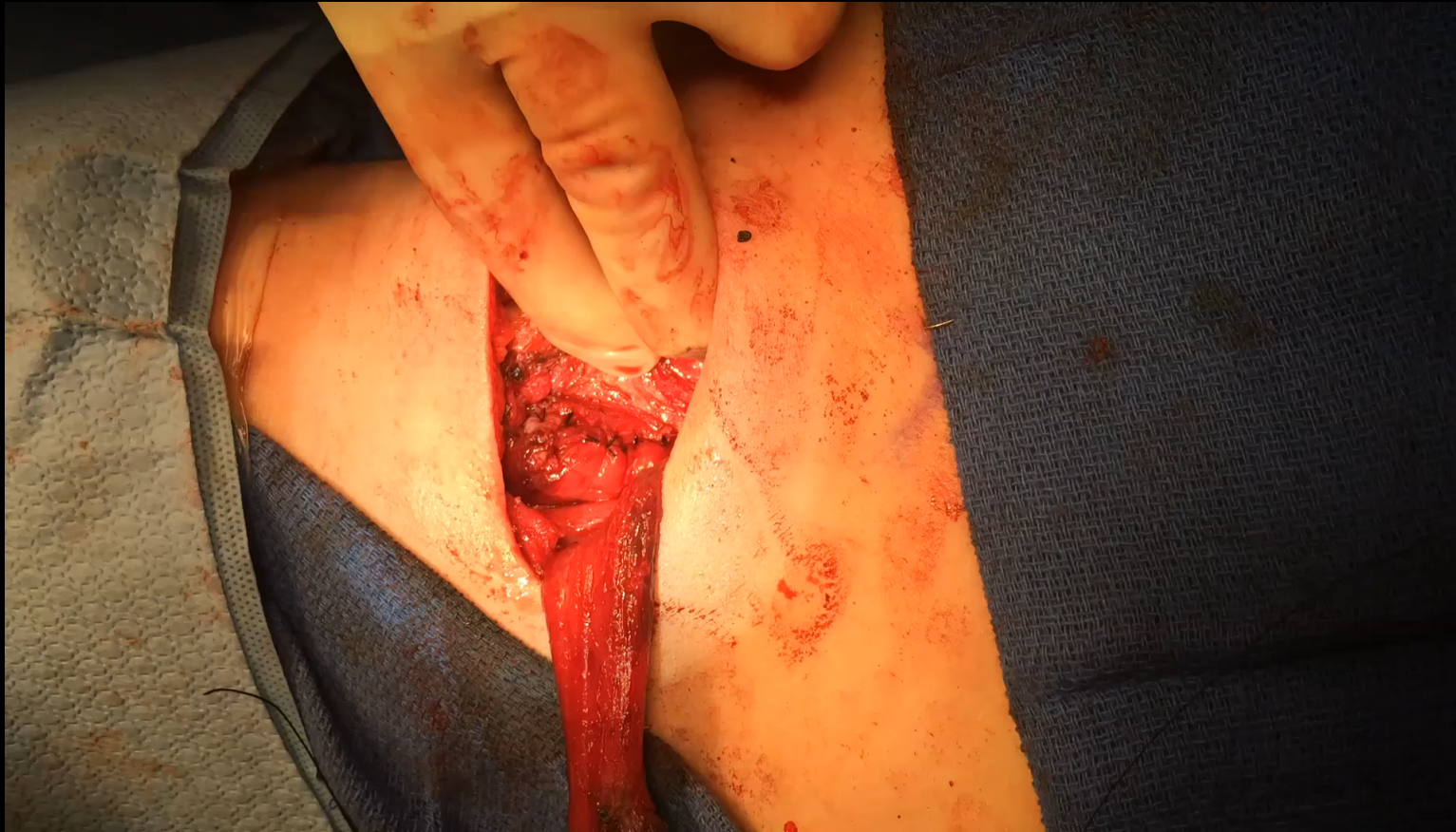- Resectable but has involvement of surrounding vital structures
 - Trachea, esophagus



First operation:

My advice- you will never regret getting help

- Resectable but has involvement of surrounding vital structures
 - Trachea, esophagus



VIDEO

Recurrences can still happen

- You did your best to avoid recurrence
 - You did the right surgery
 - Good endocrinologist followed the patient
 - TSH suppression, maybe RAI
 - Careful US surveillance
- **BUT your patient has a recurrence**
 - There is a poorly defined risk of recurrence
 - Low risk group :10-30% recurrent rate
 - High risk group : 20-50% recurrent rate
 - Everyone is anxious
 - HOW DID THIS HAPPEN?
- Should they be anxious?
 - Overall disease mortality: 30-50%
 - Shorter disease-free interval
 - **What kind of a recurrence is it??**

Different kinds of recurrence require different treatments

Not too bad

“Everybody is nervous”



Terrible

Patients show a spectrum of problems

- Patients with biochemical recurrences-slight elevations in serum Tg in low-risk patients
 - Itsy bitsy nodal recurrences

- Patients with lateral nodal recurrences
- Patients with bulky recurrences in central nodes
- Patients with structural recurrence in neck
- Patients with distant mets

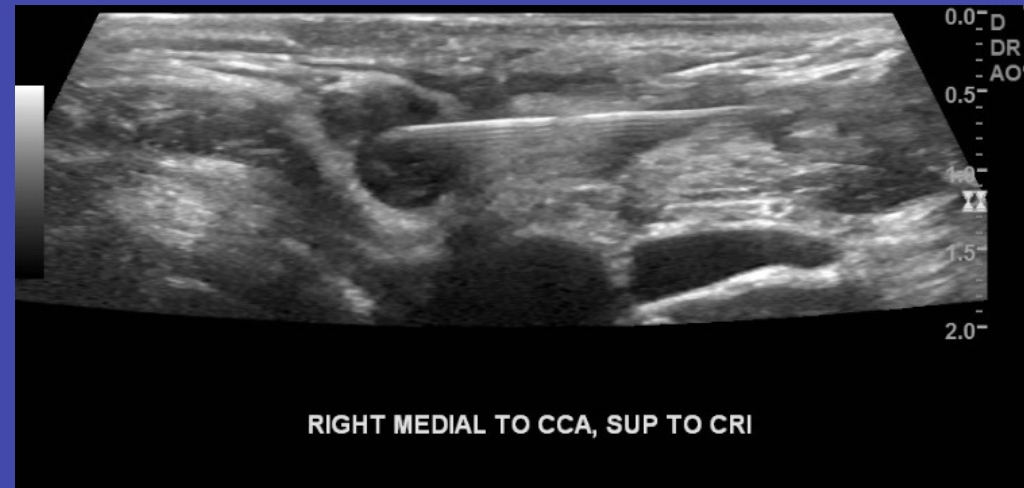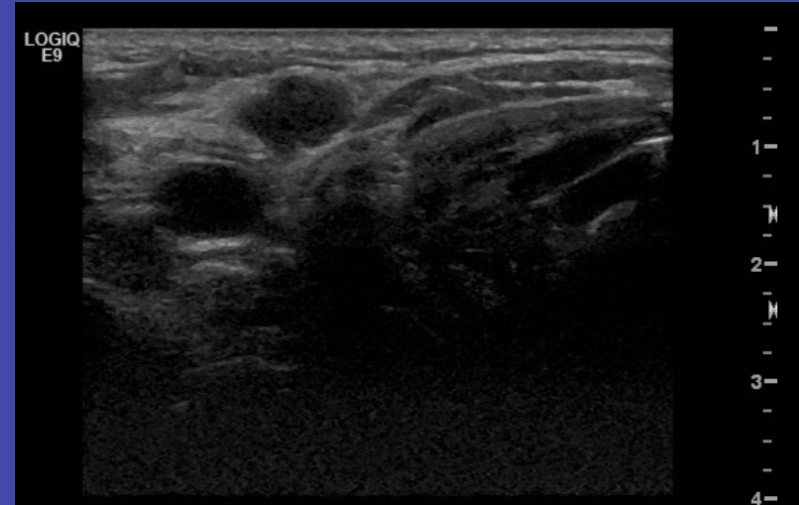
“Let the punishment fit the crime”

W.S Gilbert, The Mikado

Second operation- Surgeons pay attention to the nodes AND cosmesis

Patient case

- Total thyroidectomy 2012 for goiter– benign final path
- 2015- mass in right level II node
- FNA- PTC
 - Thyroglobulin baseline 0.3 TSH 1.7
 - Stimulated TG- 5.7




Next steps?

Dealing with lateral nodal recurrence

Patient case

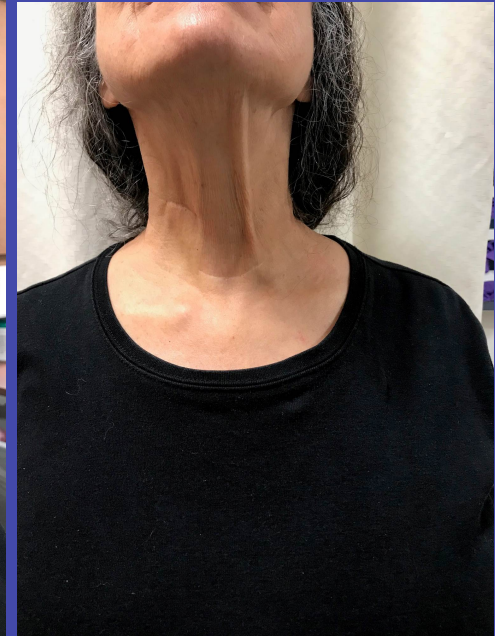
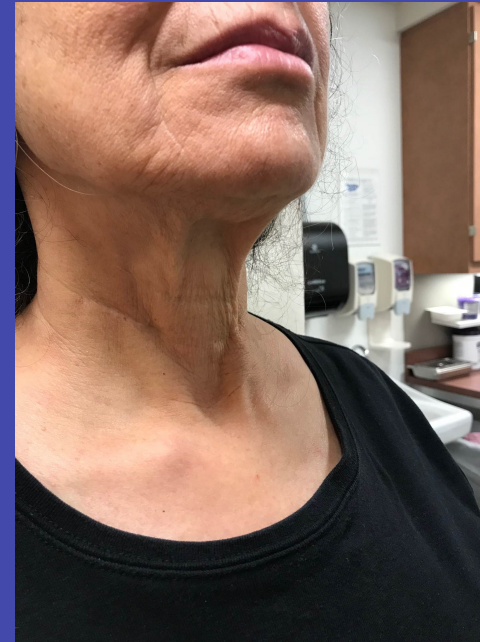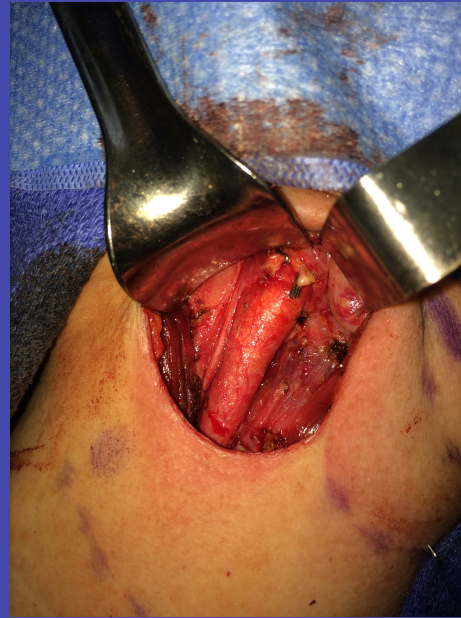
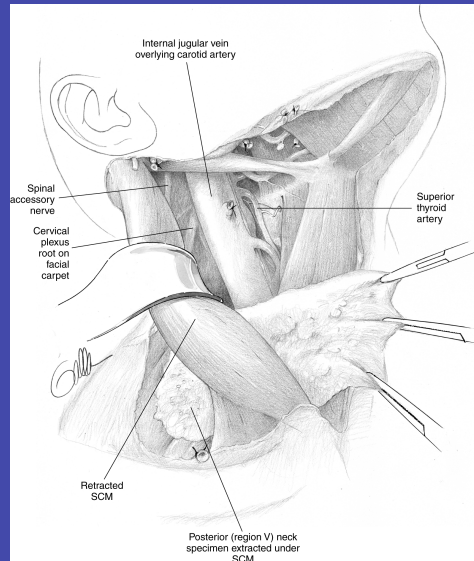
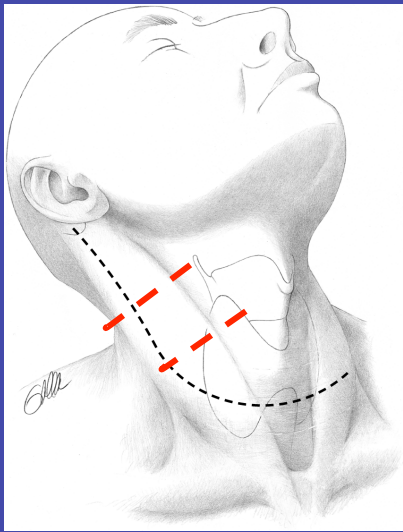
- Next steps?
 - Review old path
 - Review FNA
 - Any other sites of disease?
 - RAI scan
 - Comprehensive US neck
 - Nobody likes recurrences, they like re-recurrences even less
- RAI no metastatic disease
- US neck shows only one set of suspicious nodes in right neck
- Vocal cords move normally
- Next steps- TALK TO PATIENT
 - ETOH ablation
 - Right neck dissection
 - Incision choice

Not too bad



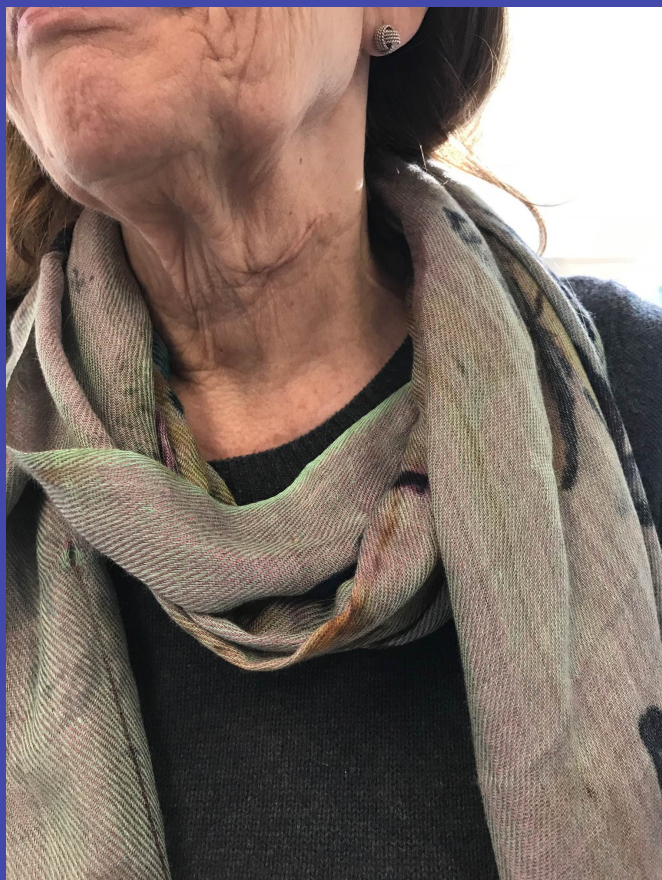Revision Surgery: Complete operation safely AND pay attention to cosmesis

- Next steps?
 - Right neck dissection through a small incision along a natural skin crease,
 - use US to guide you both preop and during positioning for finding nodes and incision placement

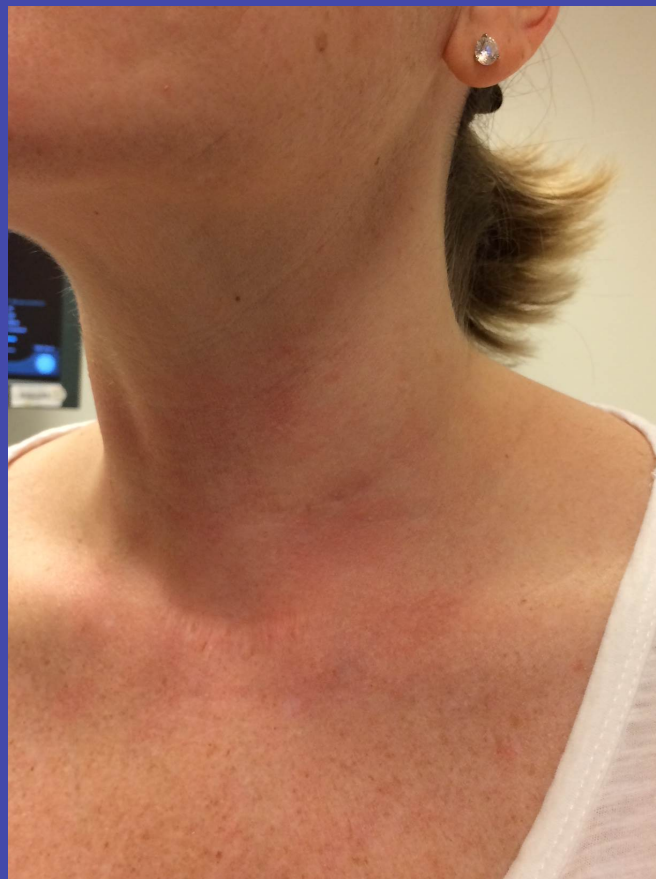

1/28 nodes positive for malignancy

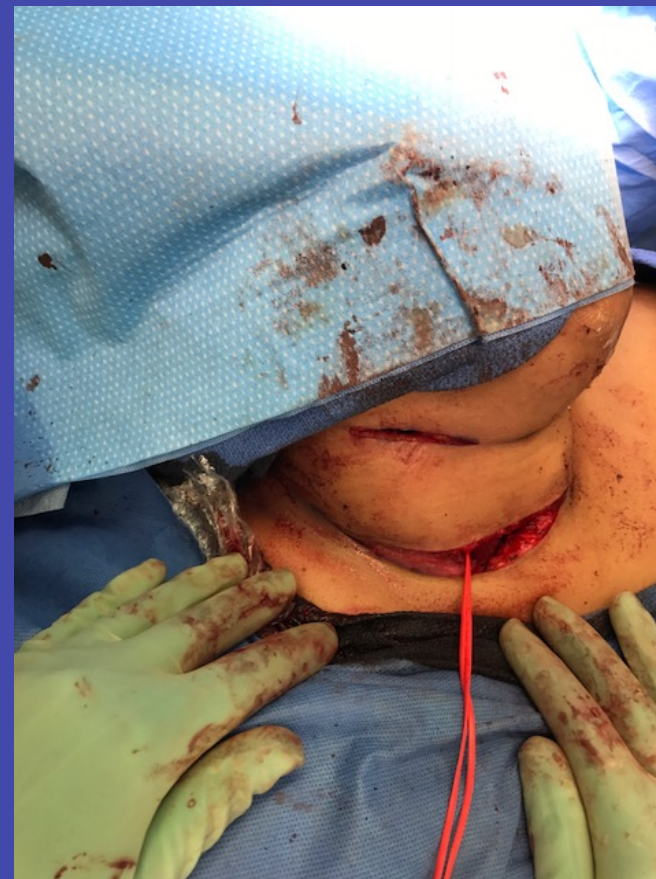Revision Surgery: Complete operation thru pretty scar = happy patient



3/37 nodes positive for malignancy



3/23 nodes positive for malignancy

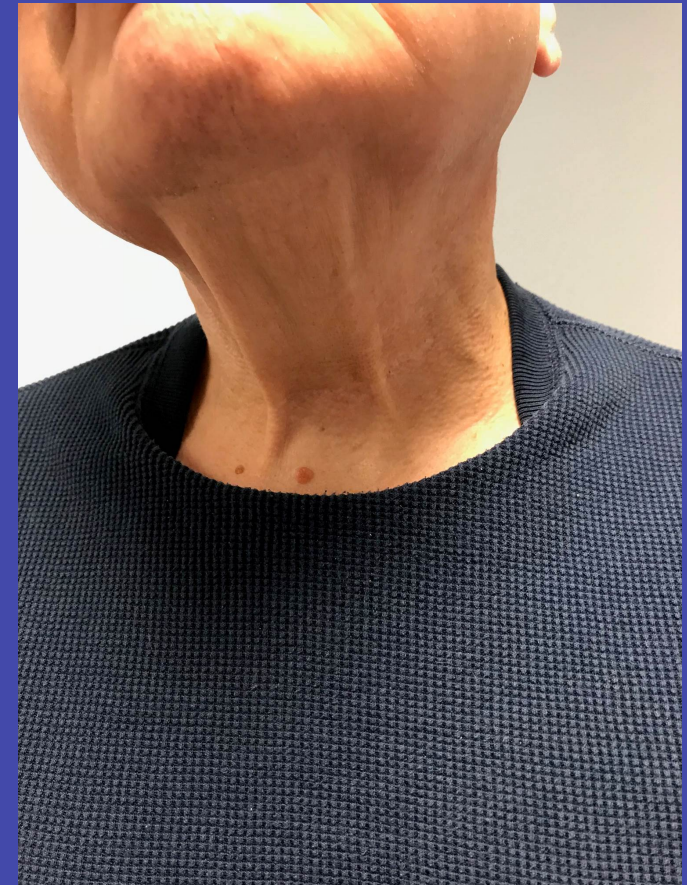
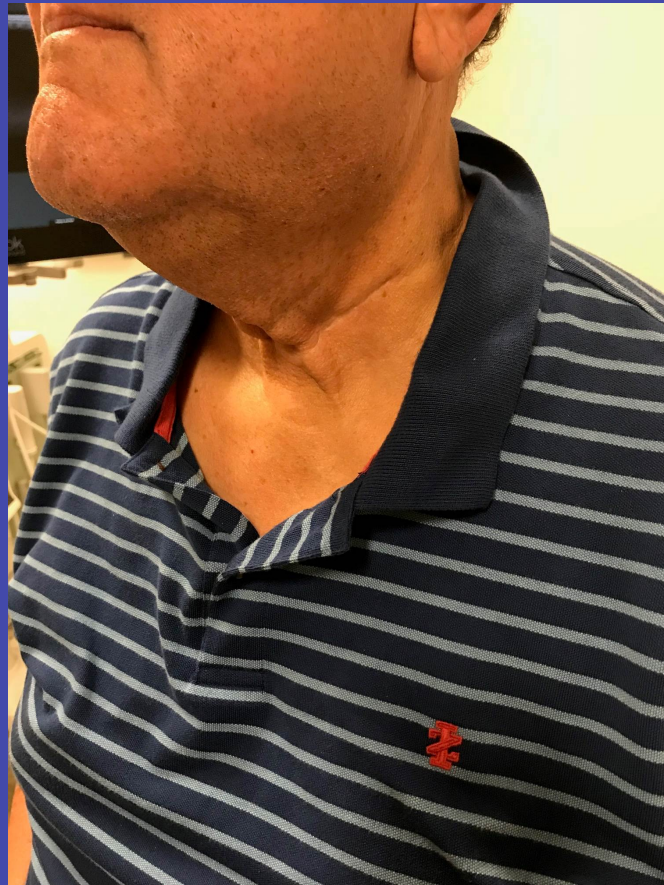
30/89 nodes positive for malignancy

Revision Surgery: Complete operation thru pretty scar = happy patient



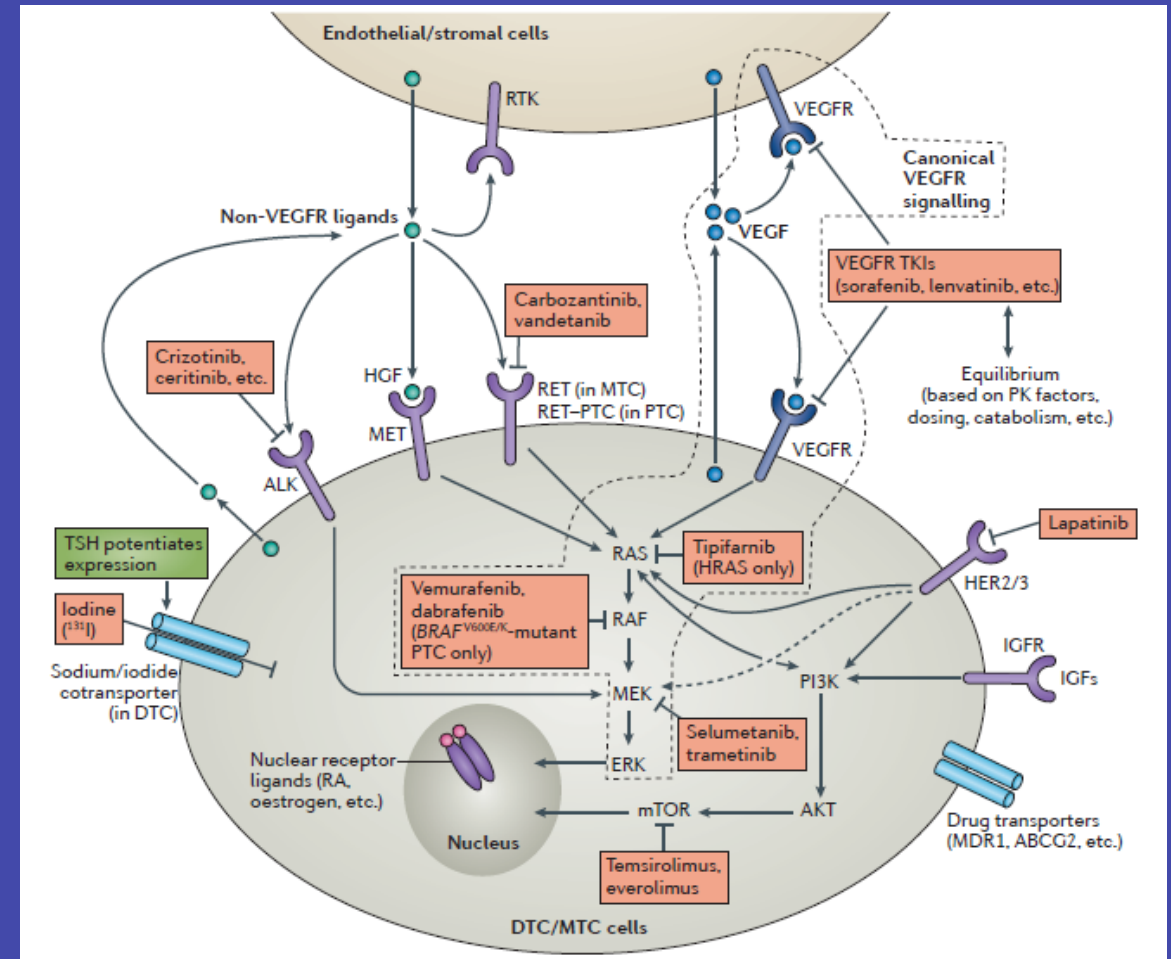
1/39 nodes positive for malignancy



1/19 nodes positive for malignancy

The decade of therapeutic development for recurrent or unresectable thyroid cancers

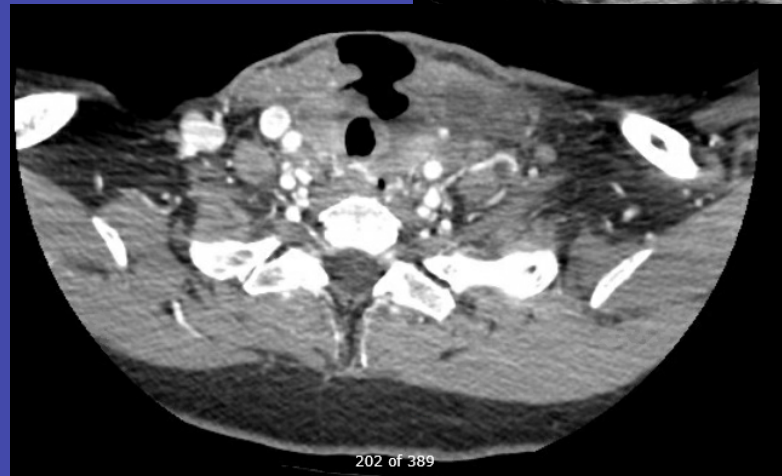
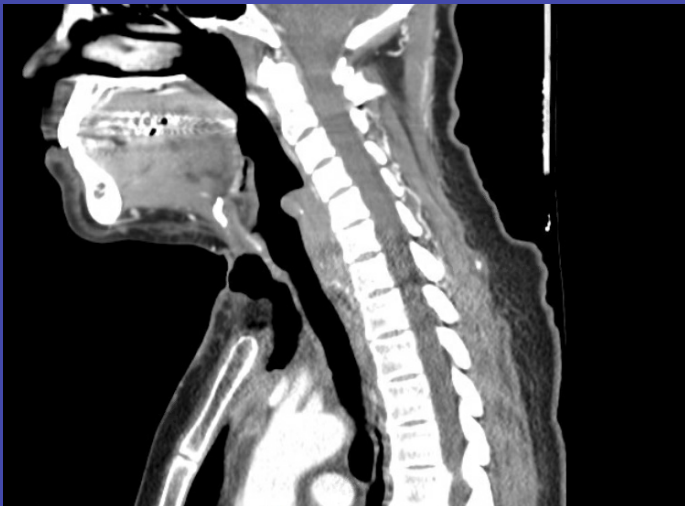
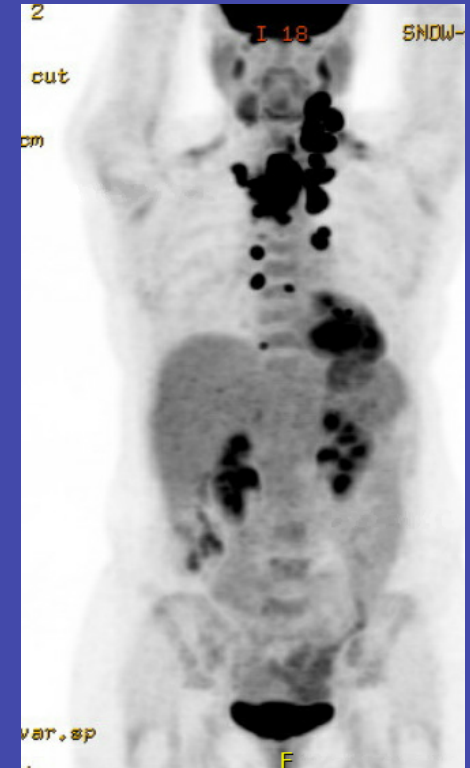
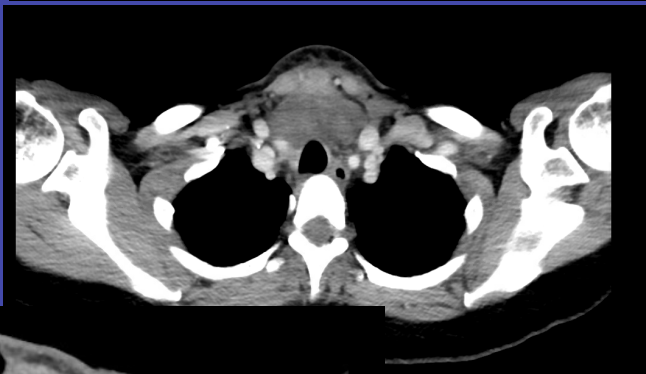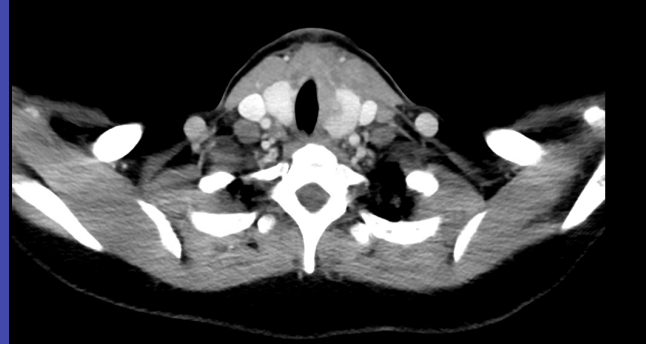- Rapid explosion of testing of novel therapeutics
 - Many clinical trials just opened or being designed/finalized specifically for aggressive thyroid cancers
 - Tyrosine kinase inhibitors
 - MEK inhibitors
 - **BRAF inhibitors:** For patients with BRAF mutation
 - BRAF +MEK
 - Lenvatinib
 - Immunotherapy combinations



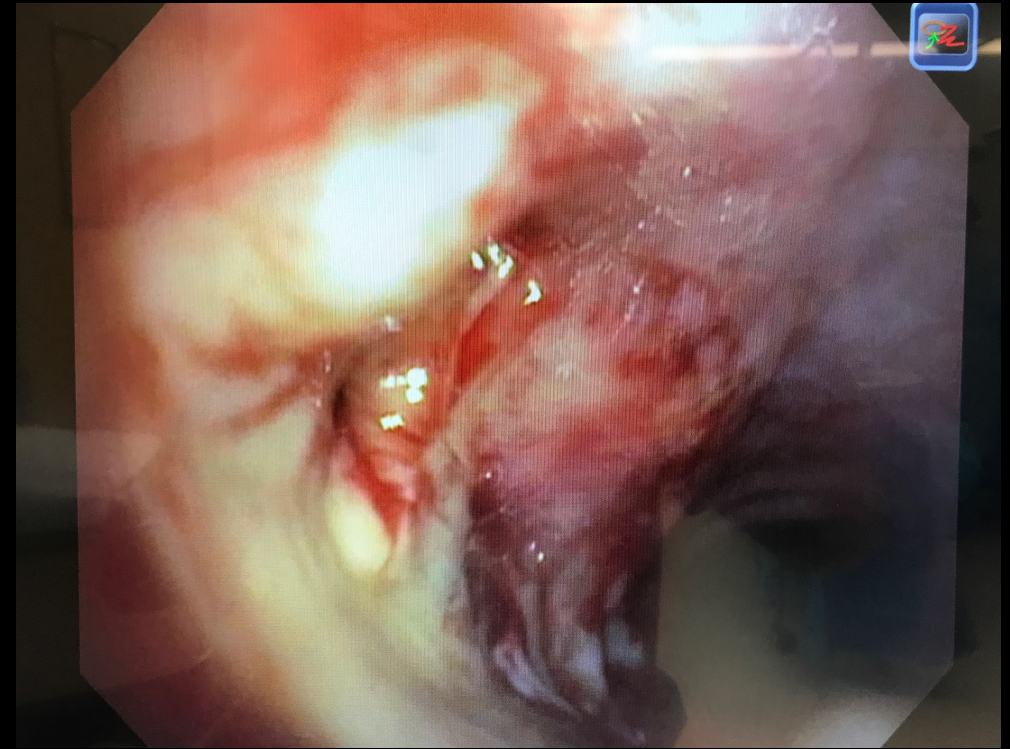
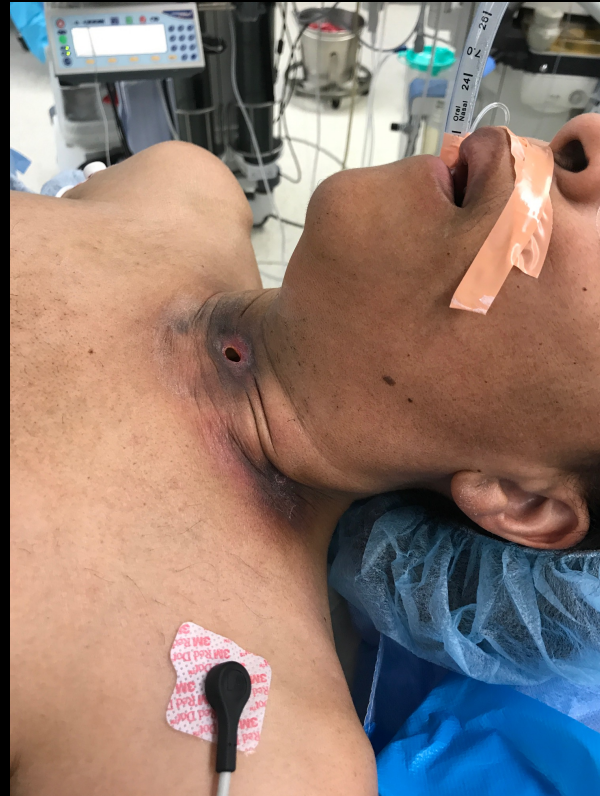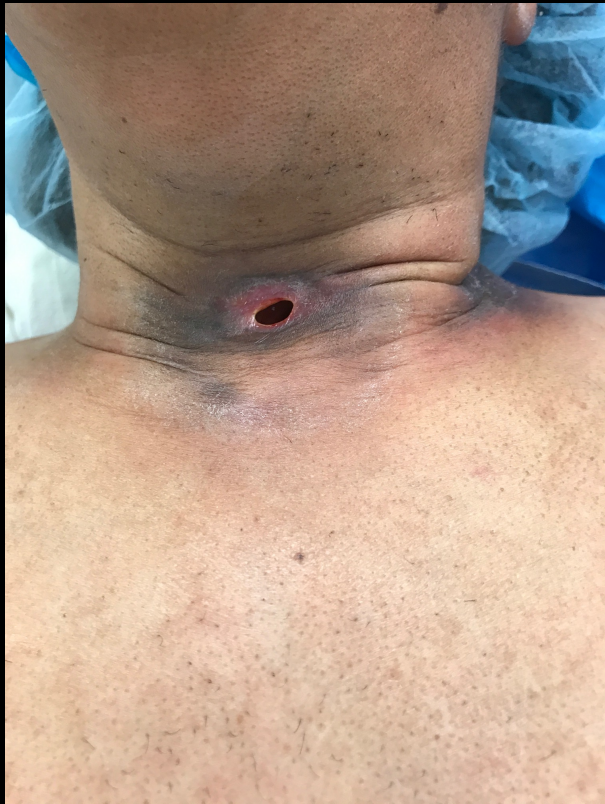Surgeons as part of a multidisciplinary team: Multimodal therapy for unresectable tumors

May 2017: 54 yo woman noted neck mass while traveling in Europe

- CT-Neck: 5 cm left necrotic thyroid mass with nodes with pulmonary nodules and mediastinal adenopathy- PET avid
- Biopsy- ATC- Stage IVC
- May 2017 Started trial with Lenvatinib
- June 2017- sinus tract
- August 2017- cavitation of tumor

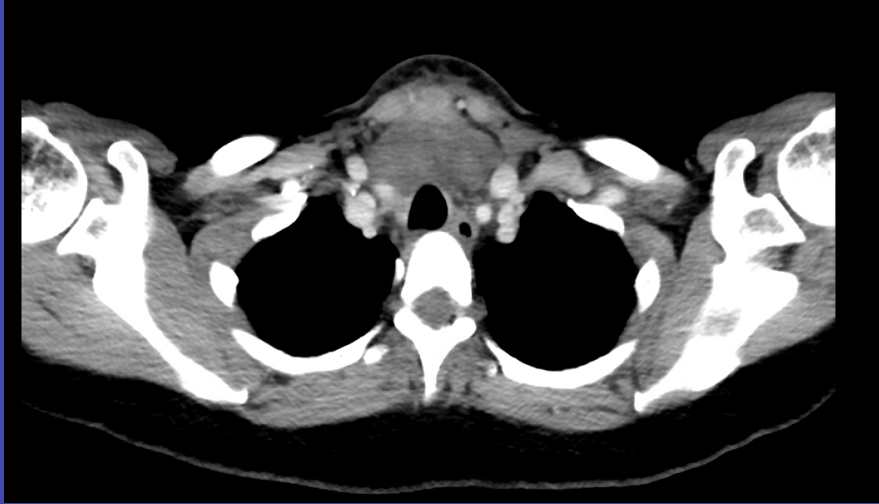

Surgeons as part of a multidisciplinary team: Multimodal therapy for unresectable tumors

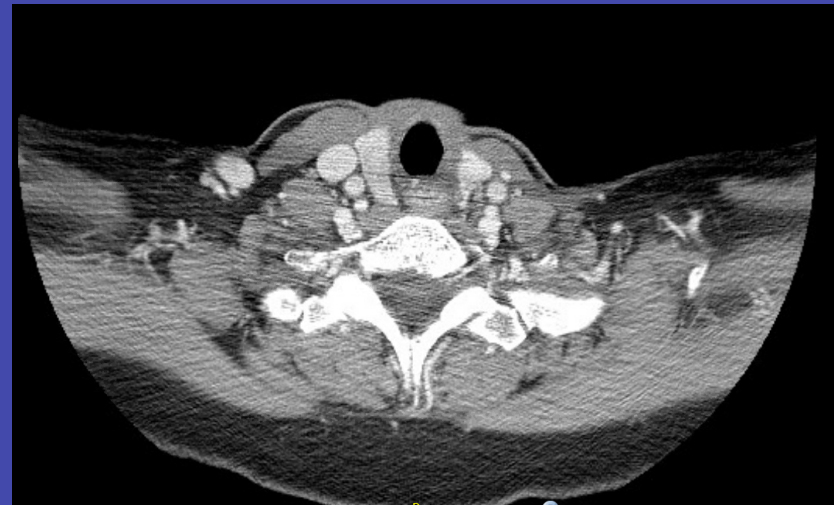
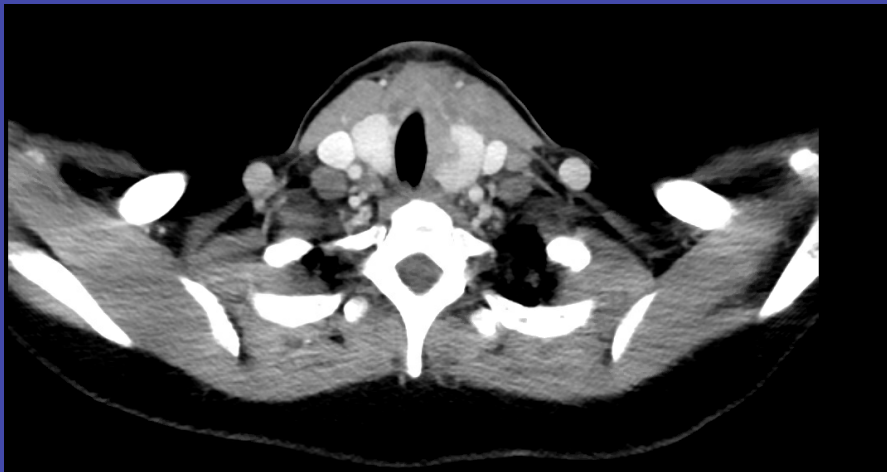
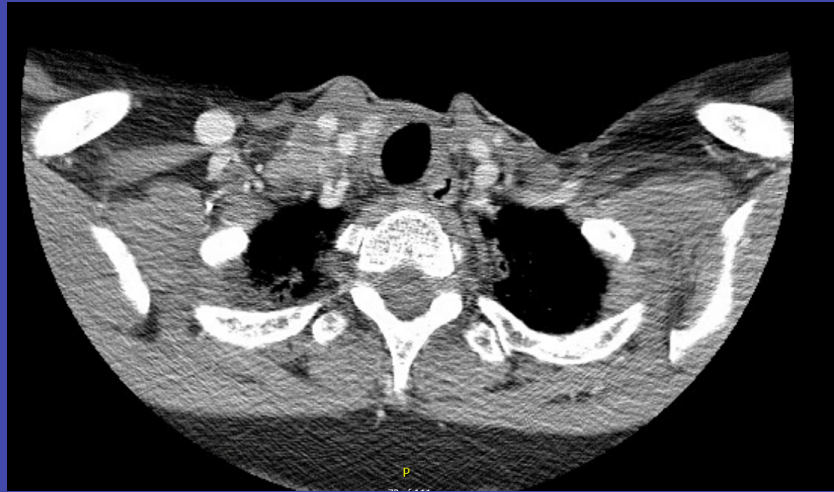Surgeons as part of a multidisciplinary team: Multimodal therapy for unresectable tumors

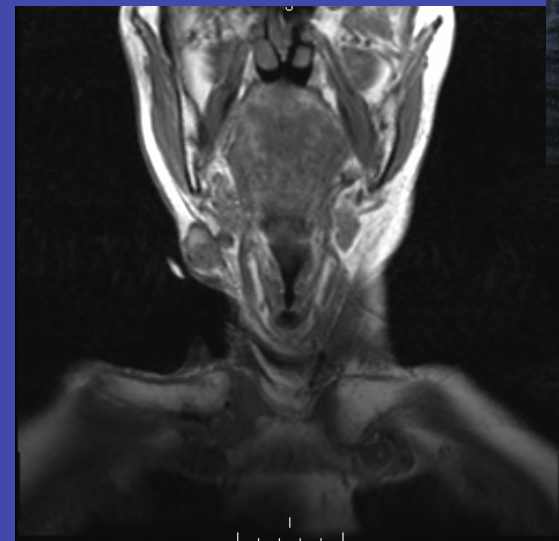
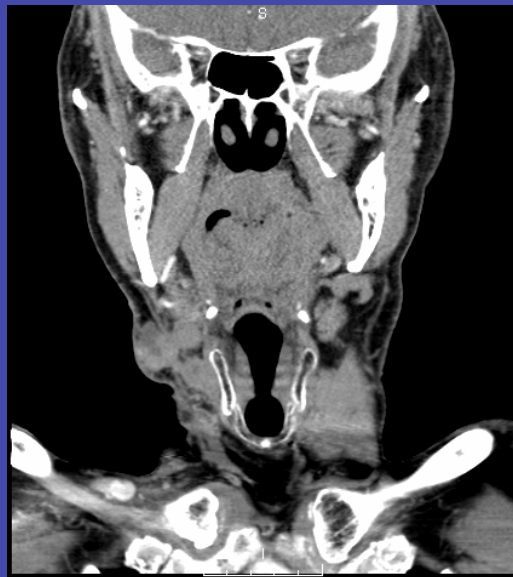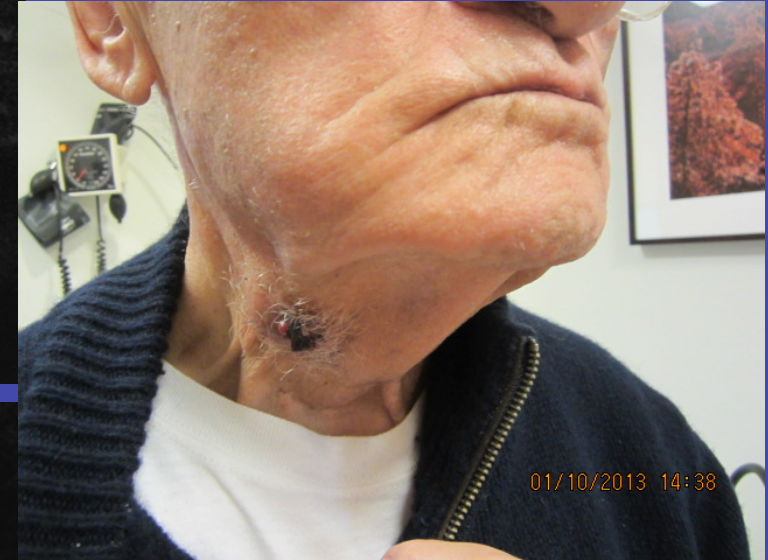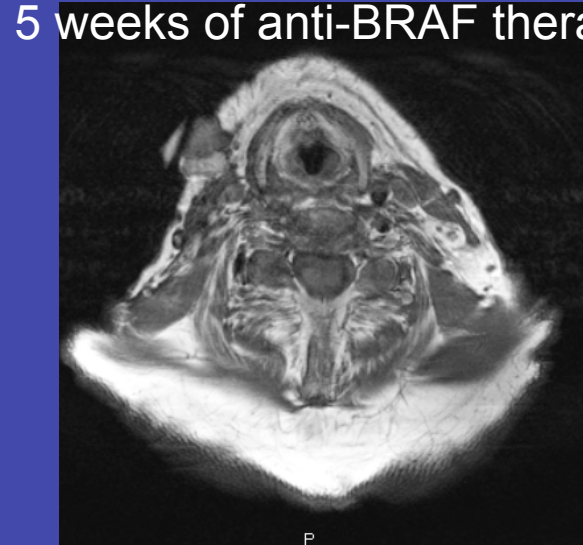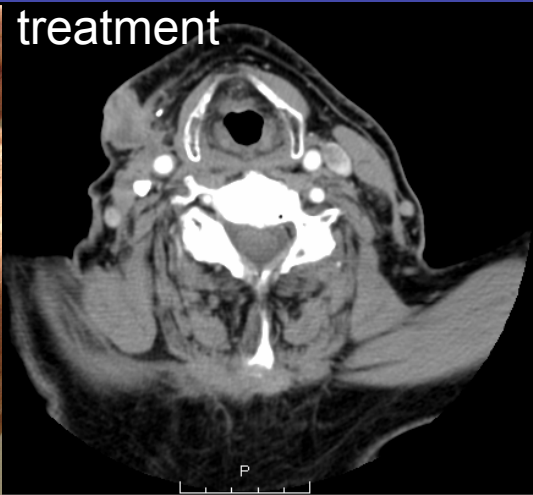
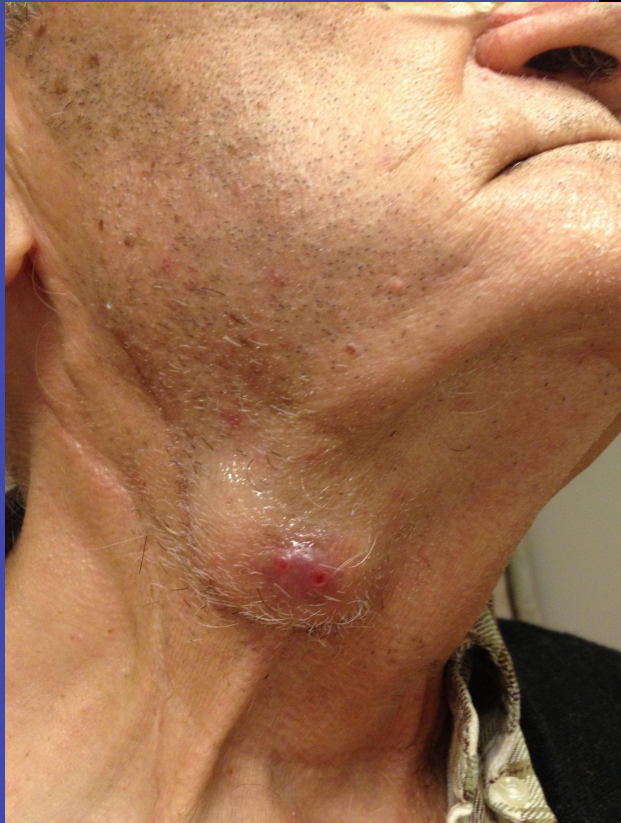May 2018



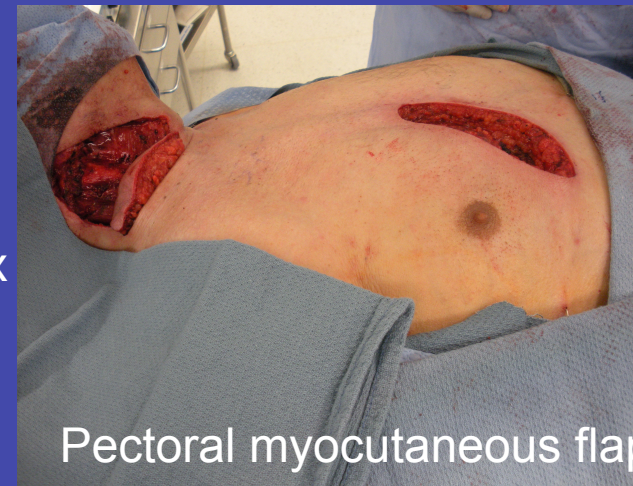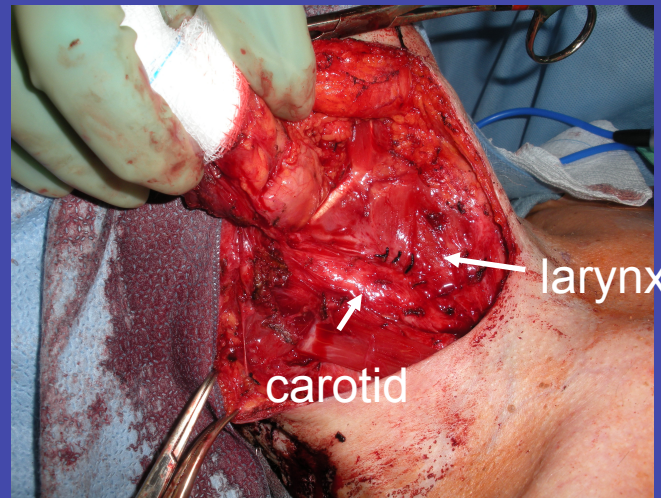
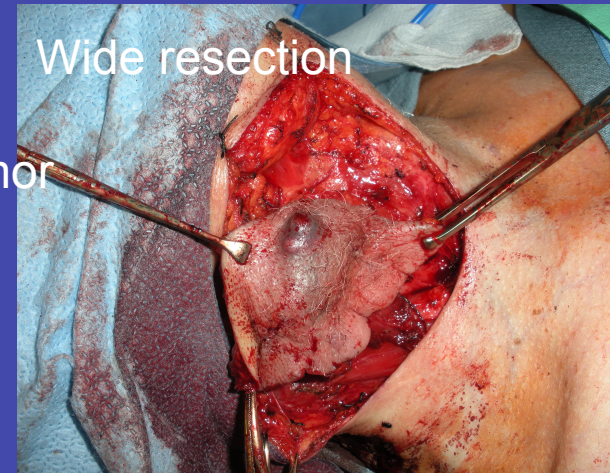
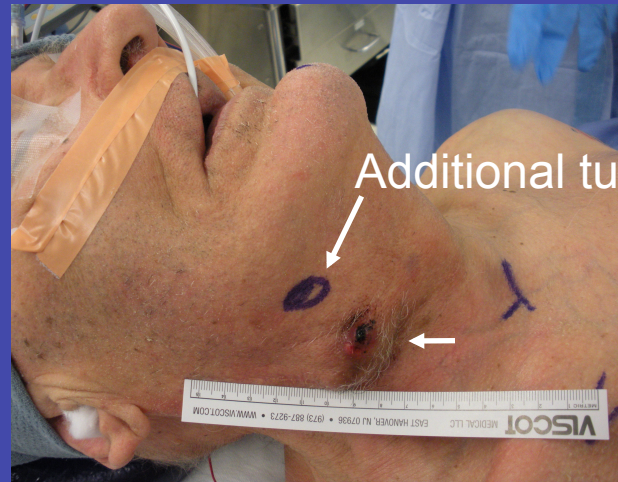
October 2018

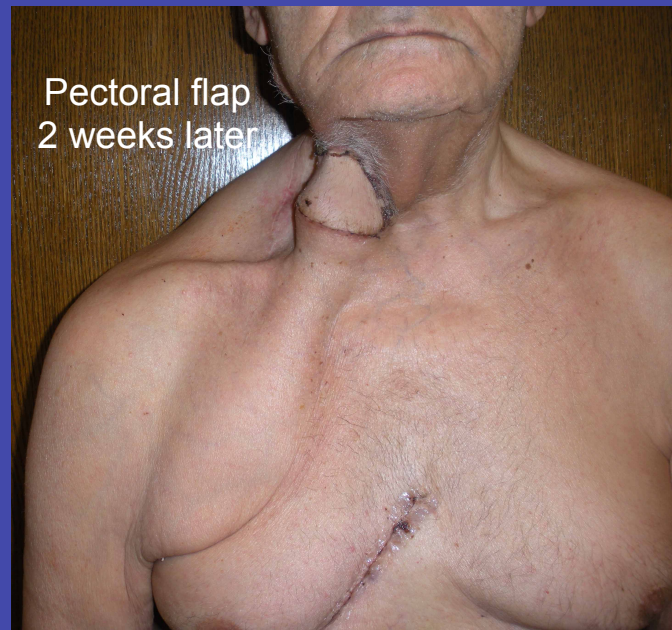
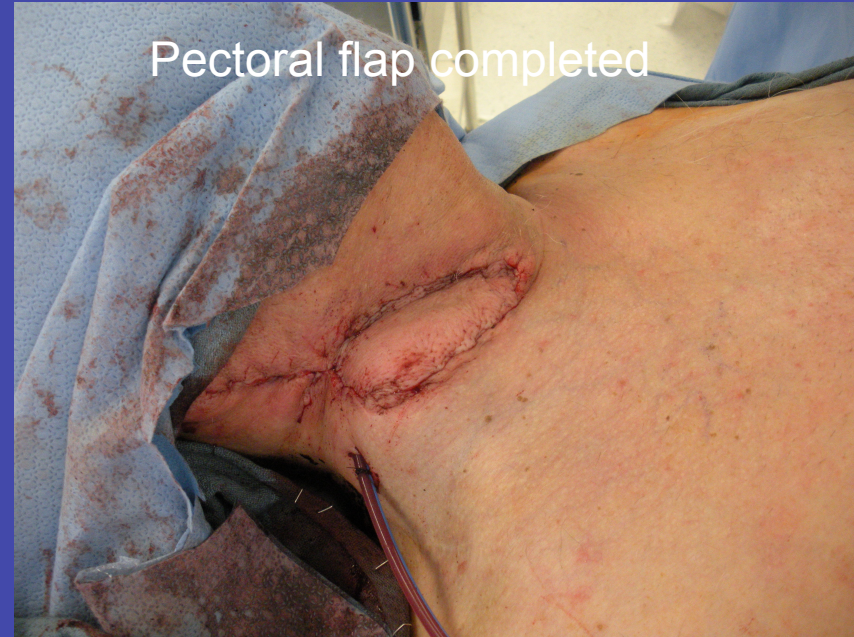
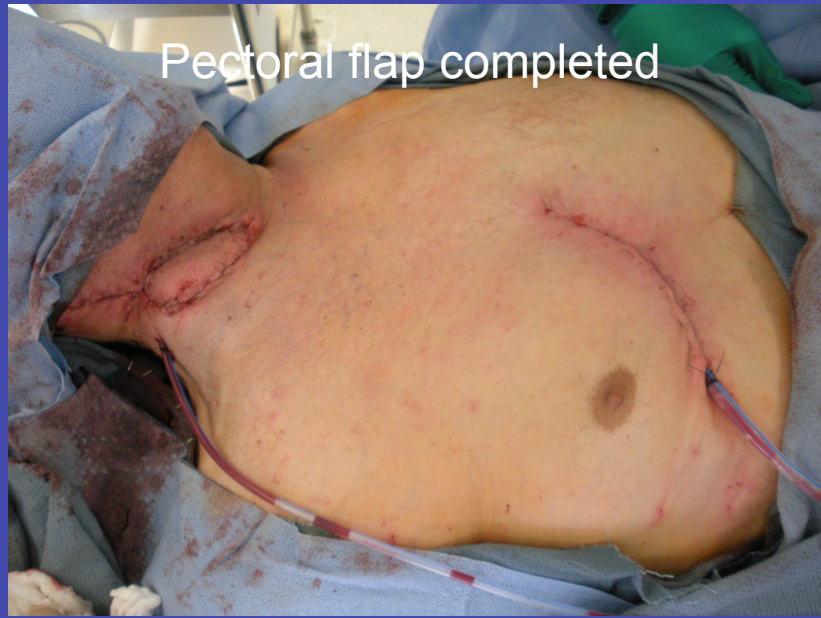
Surgeons as part of a multidisciplinary team: Multimodal therapy for difficult recurrences



Surgeons as part of a multidisciplinary team: Multimodal therapy for difficult recurrences





Take Home Message

- Careful preoperative workup is very important
 - Be kind to your patients, talk about risks
 - Map the nodal disease
 - Be prepared, have help
- Recurrence rates will be lower if the first surgery is done right
 - Total thyroidectomy, find and remove involved nodes
 - Identify high risk patients upfront using all available tools
 - Use capable endocrinologist to follow your patients
- Surgery is still the primary management of the recurrent thyroid carcinoma
 - ETOH ablation/watchful waiting in select cases
- Experienced surgeon are critical
- Multidisciplinary approach important
 - Have the right endocrine/oncology/radiology team

Team members

- MGH Department of Surgery and MGH Endocrine Tumor Program
 - Keith Lillemoe
 - Richard Hodin
 - Gilbert Daniels
- Parangi Lab Members
 - **V. Gunda**
 - P.Vandenborre
 - M. Bernasconi
- Collaborators
 - Carrie Lubitz, MD MPH
 - David McFadden MD PhD



MGH Endocrine Surgery



Parangi Lab