



ITALIAN CHAPTER

Laser Ablation, Microwaves and High Focused Ultrasound

Enrico Papini

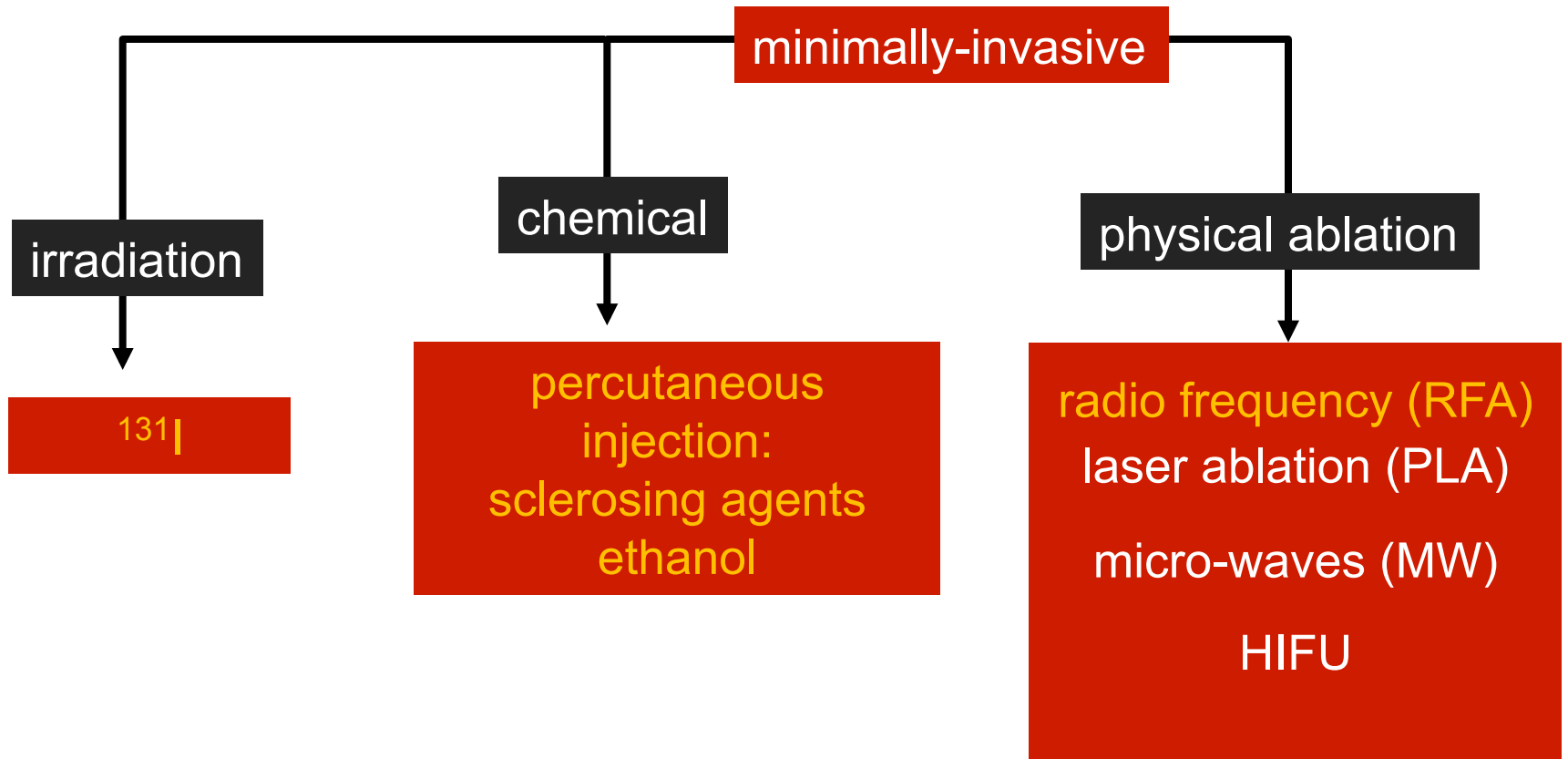
Department of Endocrinology & Metabolism
Regina Apostolorum Hospital

Conflitti di interesse

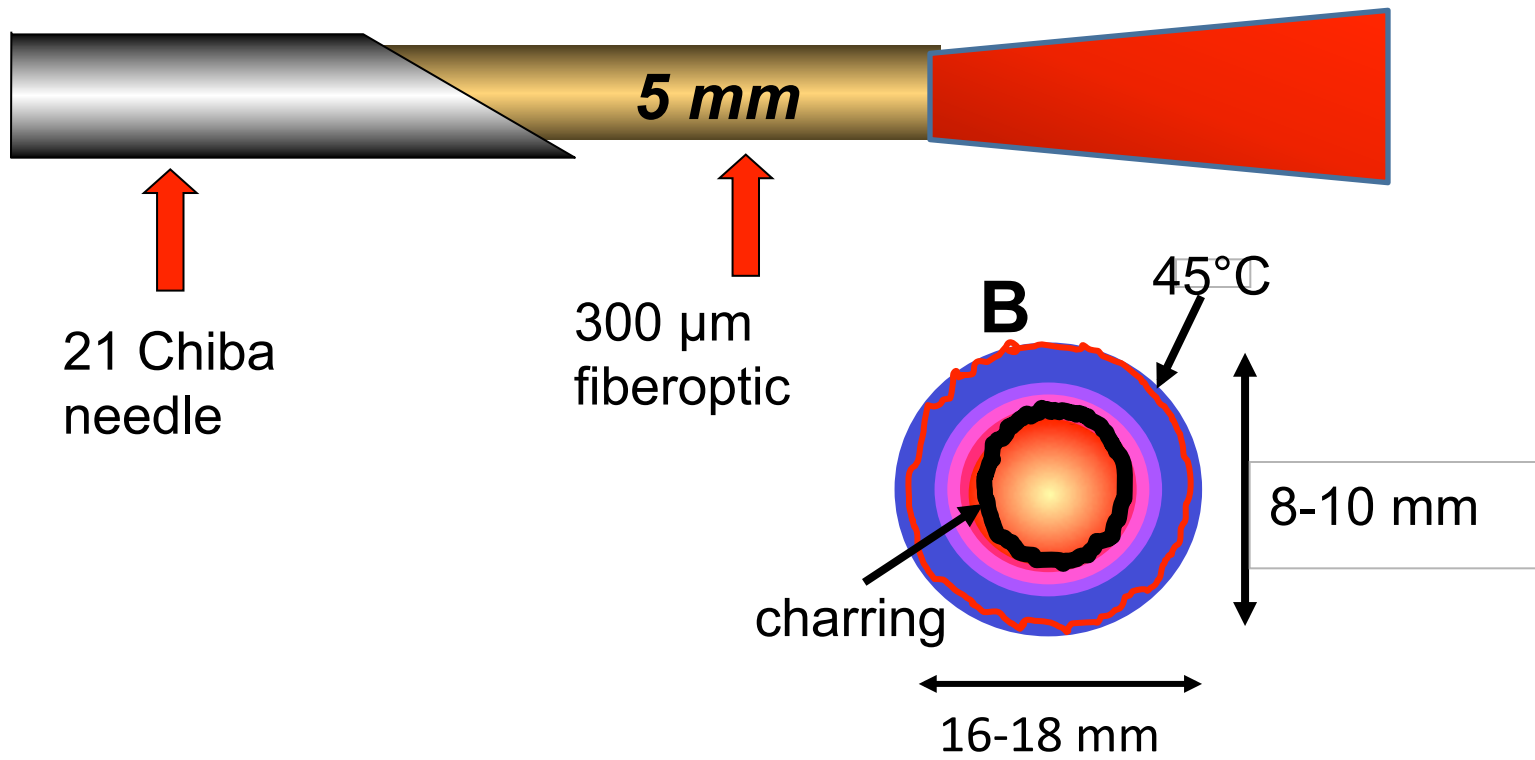
Ai sensi dell'art. 3.3 sul conflitto di interessi, pag 17 del Regolamento Applicativo Stato-Regioni del 5/11/2009, dichiaro che negli ultimi 2 anni ho avuto rapporti diretti di finanziamento con i seguenti soggetti portatori di interessi commerciali in campo sanitario:

Elesta, IBSA, Ipsen, Lilly, Merck, Novo, Theraklion.

Non surgical techniques for thyroid tissue ablation

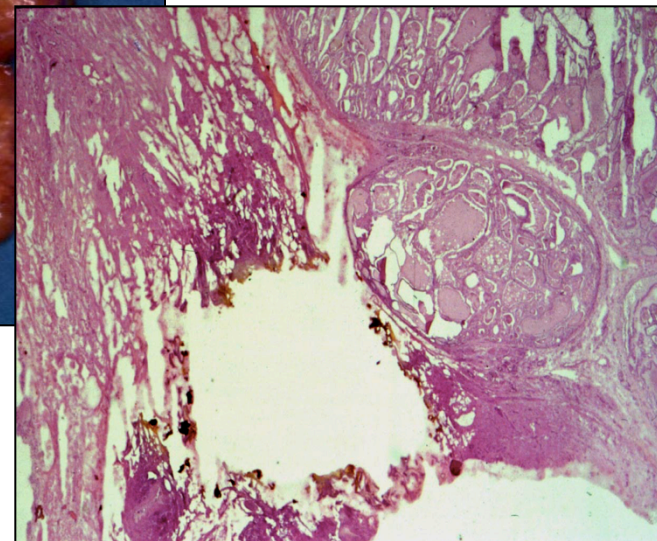
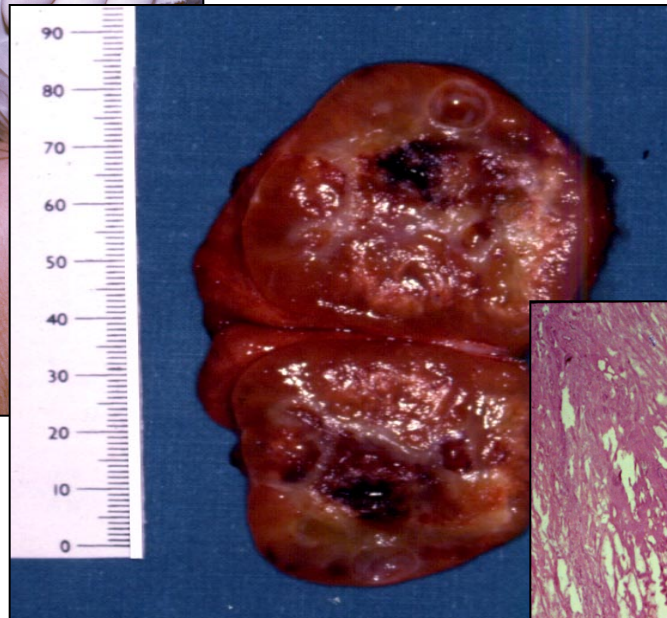
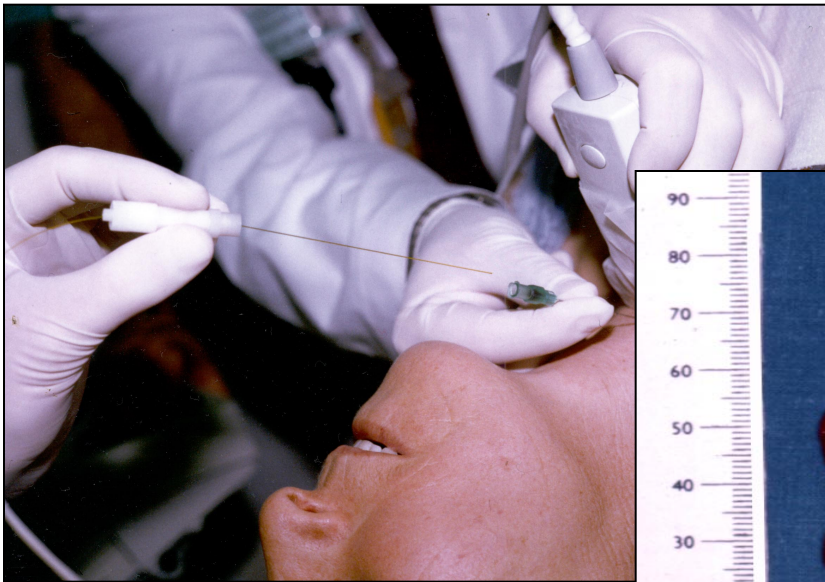


Laser Standard Damage Effect



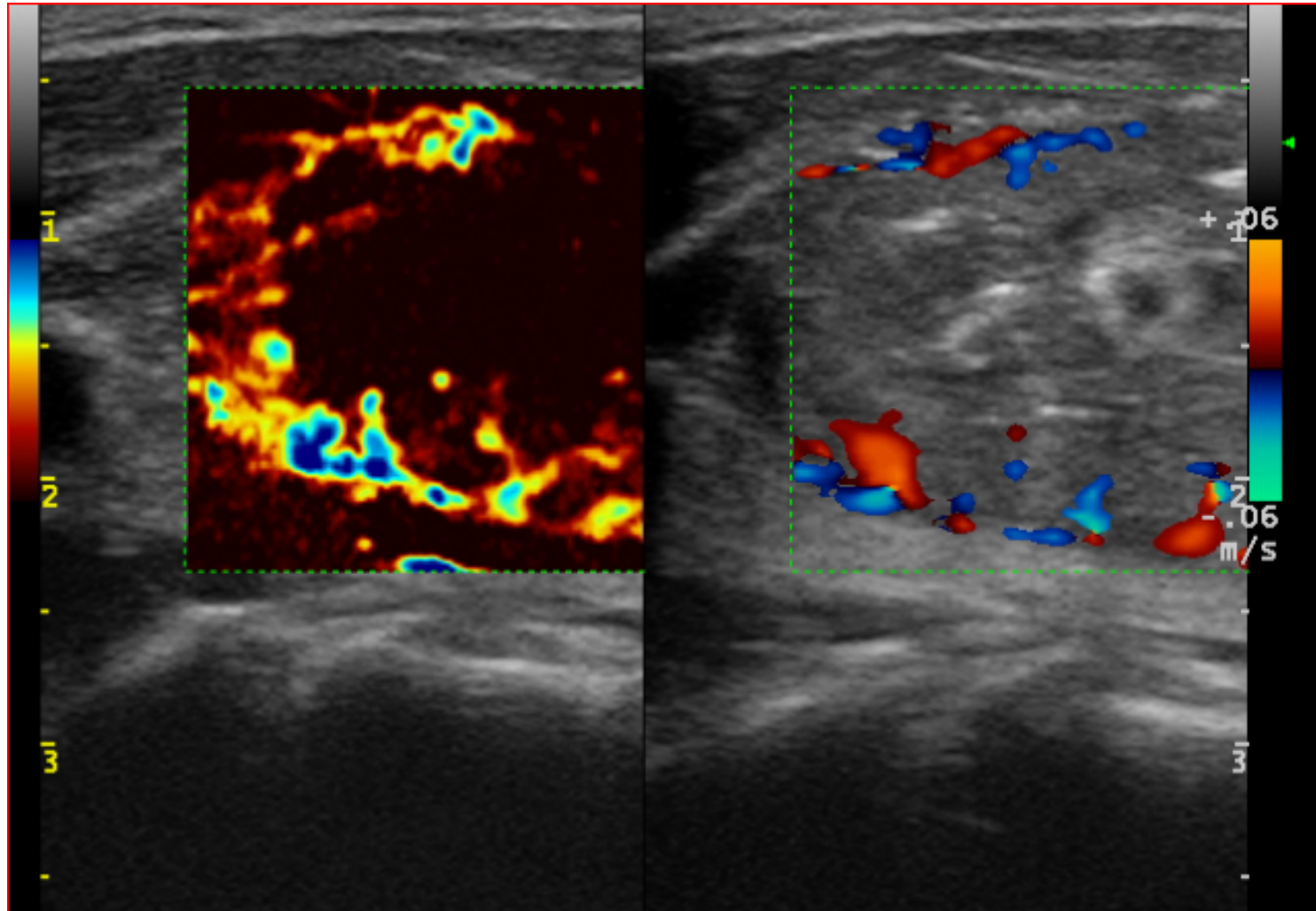
**Feasibility:
Radiology
2000**

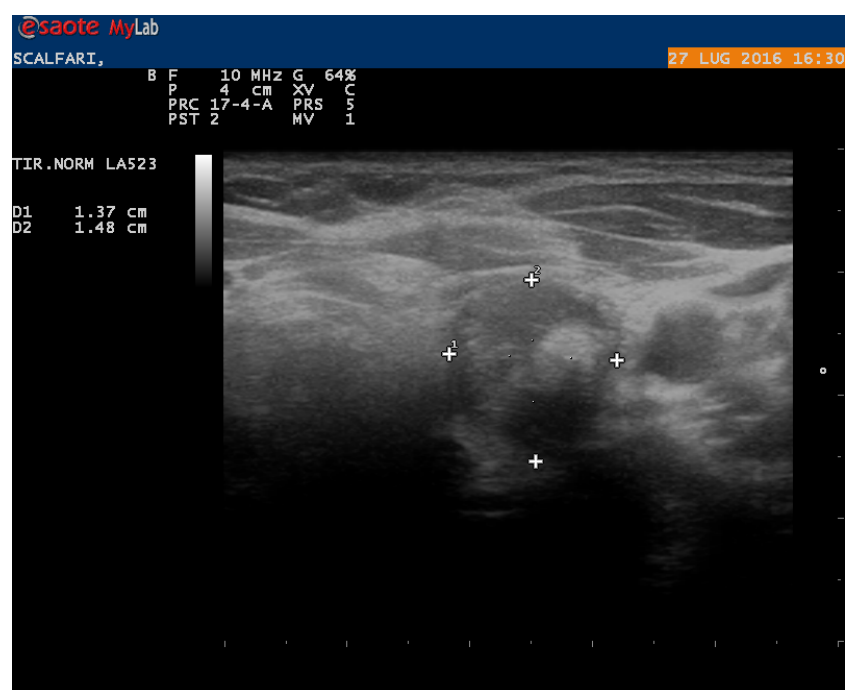
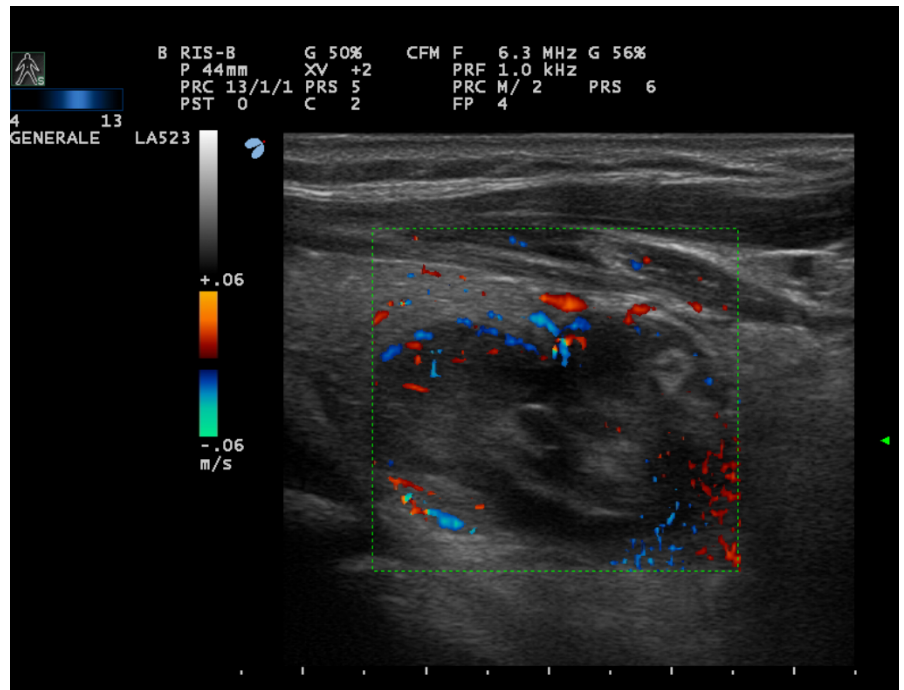
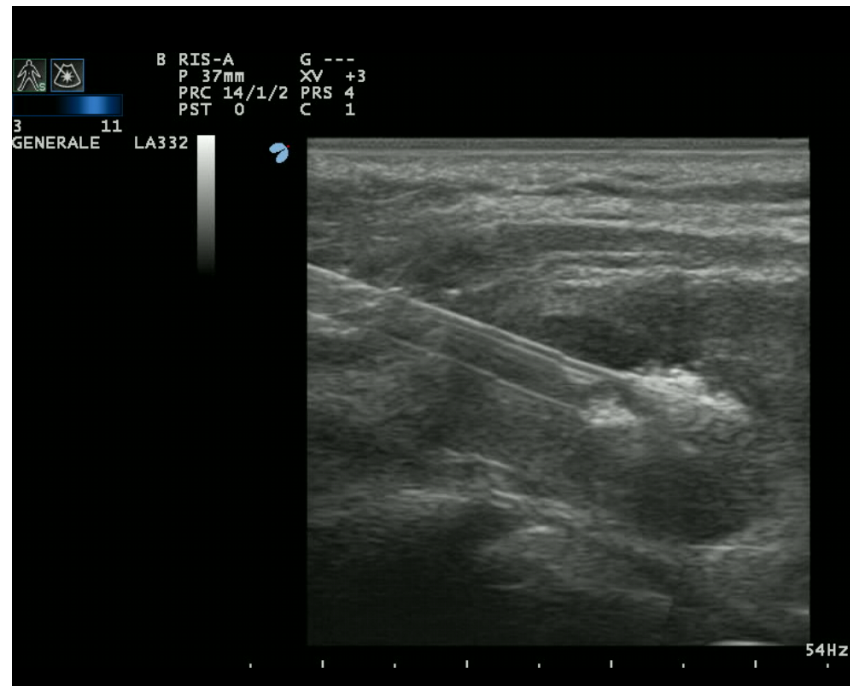
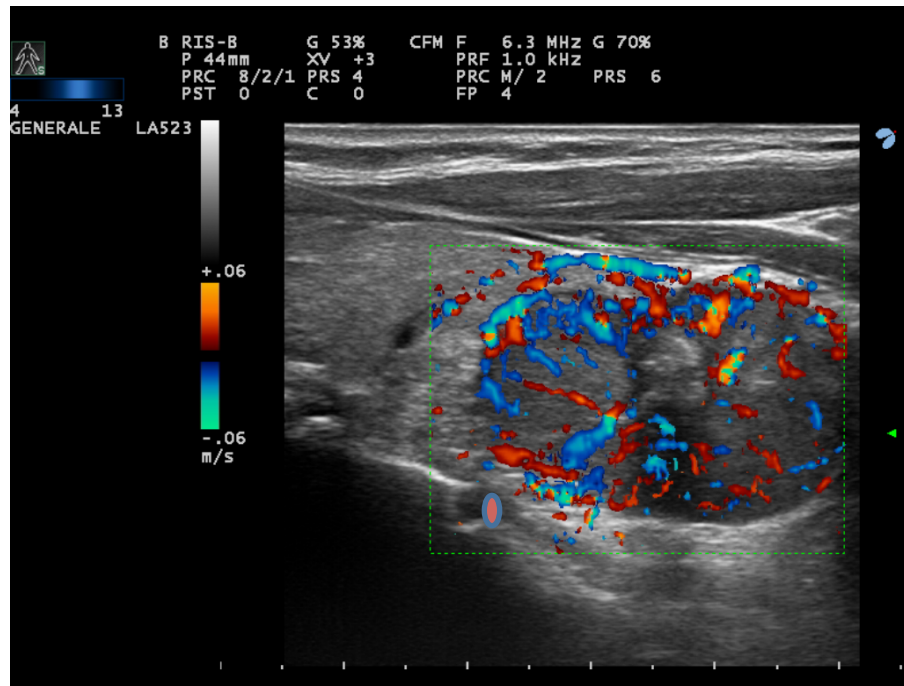
Thyroid Tissue: US-guided Percutaneous Interstitial Laser Ablation—A Feasibility Study¹



Histologic examination: central cavitation area, rim of carbonization, coagulative necrosis, peripheral edema.

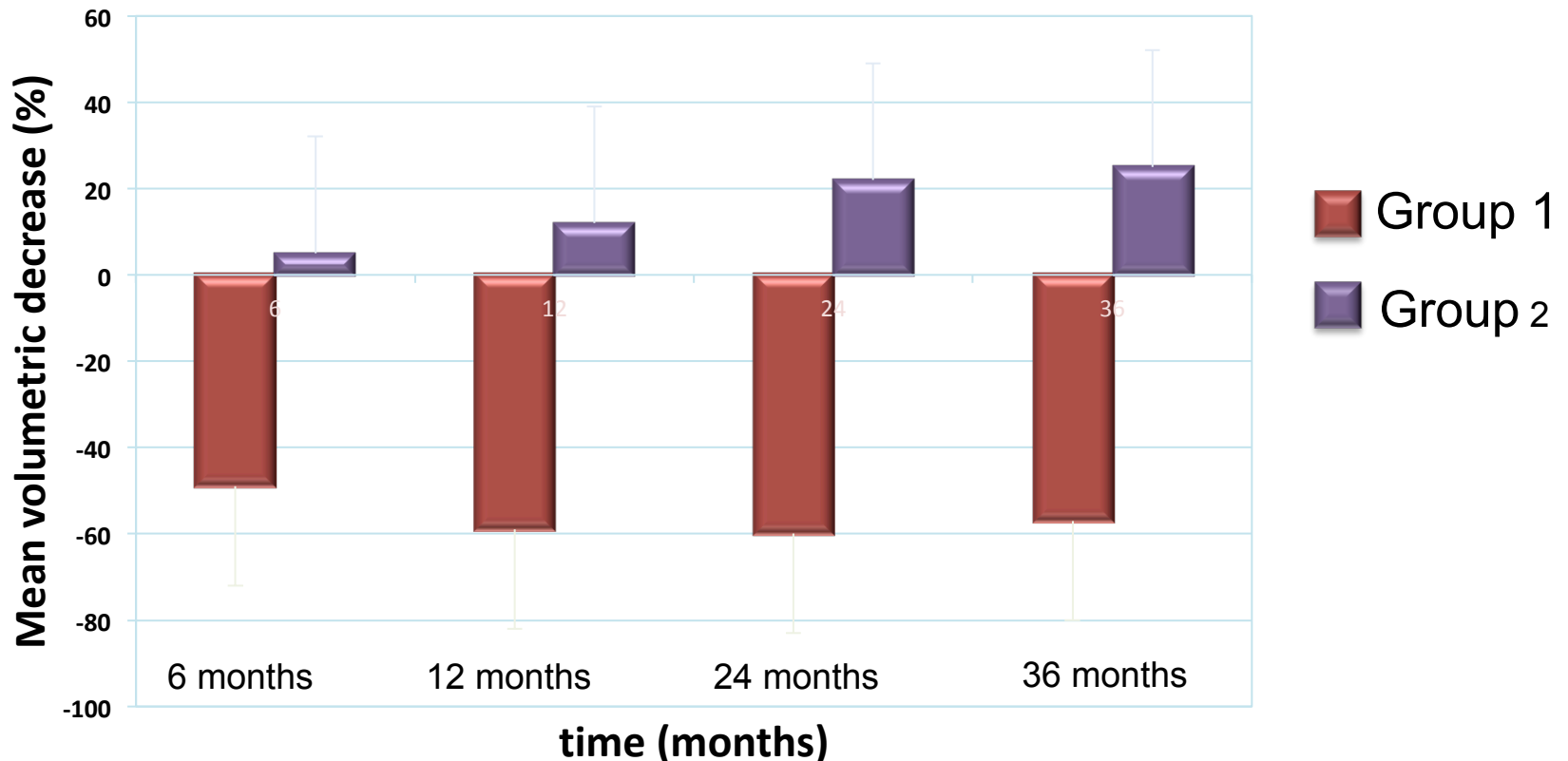
Microvascular and power-Doppler assessment after laser ablation of thyroid nodules





2014: Italian Multicenter Study on Laser Ablation of Cold Thyroid Nodules. Three-Year Results

Mean volume changes (%) at 6, 12, 24, and 36 months respect to baseline values in Group 1 (active treatment, 101 cases) and Group 2 (99 controls).



2015: Large scale trials

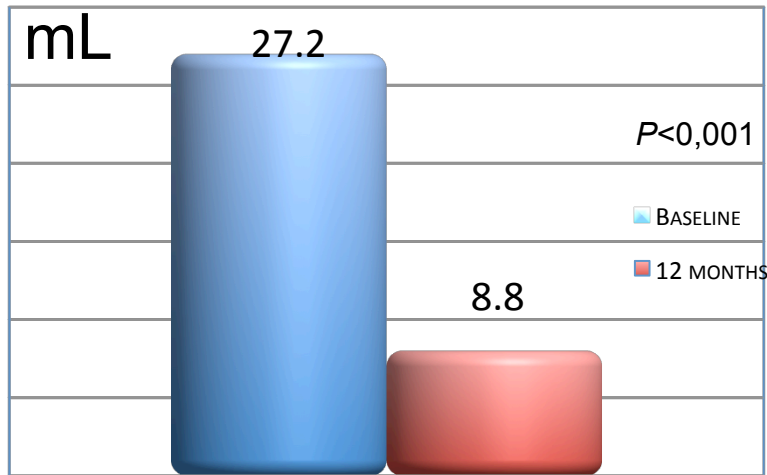
Outcomes and Risk Factors for Complications of Laser Ablation for Thyroid Nodules. A Multicenter Study on 1531 Patients

Pacella CM*, Mauri G°, Achille G°, Barbaro D°°, Bizzarri G*, De Feo P**, Di Stasio E+, Esposito R, Gambelunghe G**, Misischi I***, Raggiunti B, Rago T, Patelli GL#, D'este S #, Vitti P, and Papini E***

Results: Total number of treatments was 1,837; 1,280 (83%) of nodules had a single LAT session. Mean nodule volume decreased from 27 ± 24 mL at baseline to 8 ± 8 mL 12 months after treatment ($p < 0.001$). Mean nodule volume reduction was $72 \pm 11\%$ (range, 48–96%). This figure was significantly greater in mixed nodules ($79 \pm 7\%$; range, 70–92%) because they were drained immediately before laser illumination. Symptoms improved from 49% to 10% of cases ($p < 0.001$) and evidence of cosmetic signs from 86% to 8% of cases ($p < 0.001$). Seventeen complications (0.9%) were registered. Eight (0.5%) patients experienced transitory voice changes that completely resolved at ENT examination within 2–84 days. Nine (0.5%) minor complications were reported. No changes in thyroid function or autoimmunity were observed.

- **mean nodule volume decrease: 70%**
(multiple treatments)
- **complication rate: 0.5%**

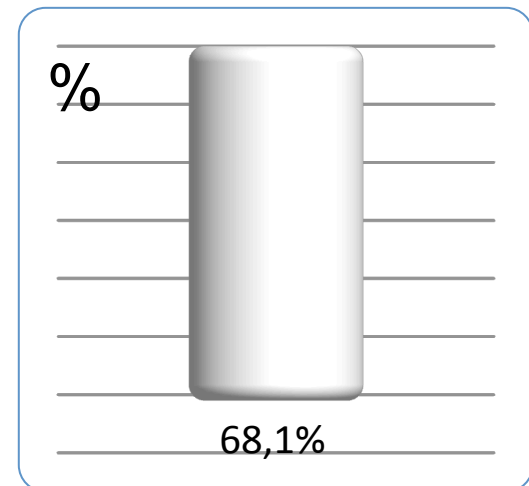
MEAN VOLUME REDUCTION AT 12 MONTHS



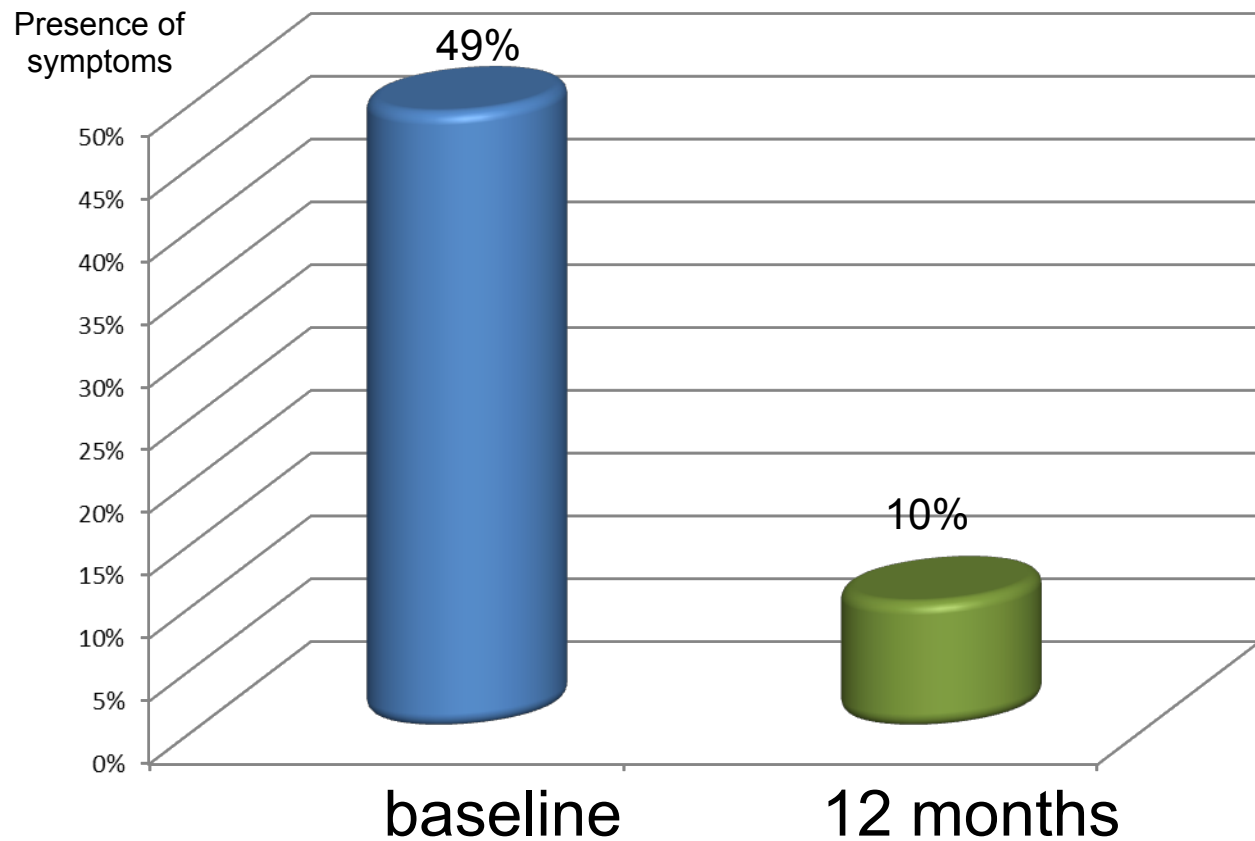
baseline 12 months

Mean volume decrease (mL)
12 months after LAT

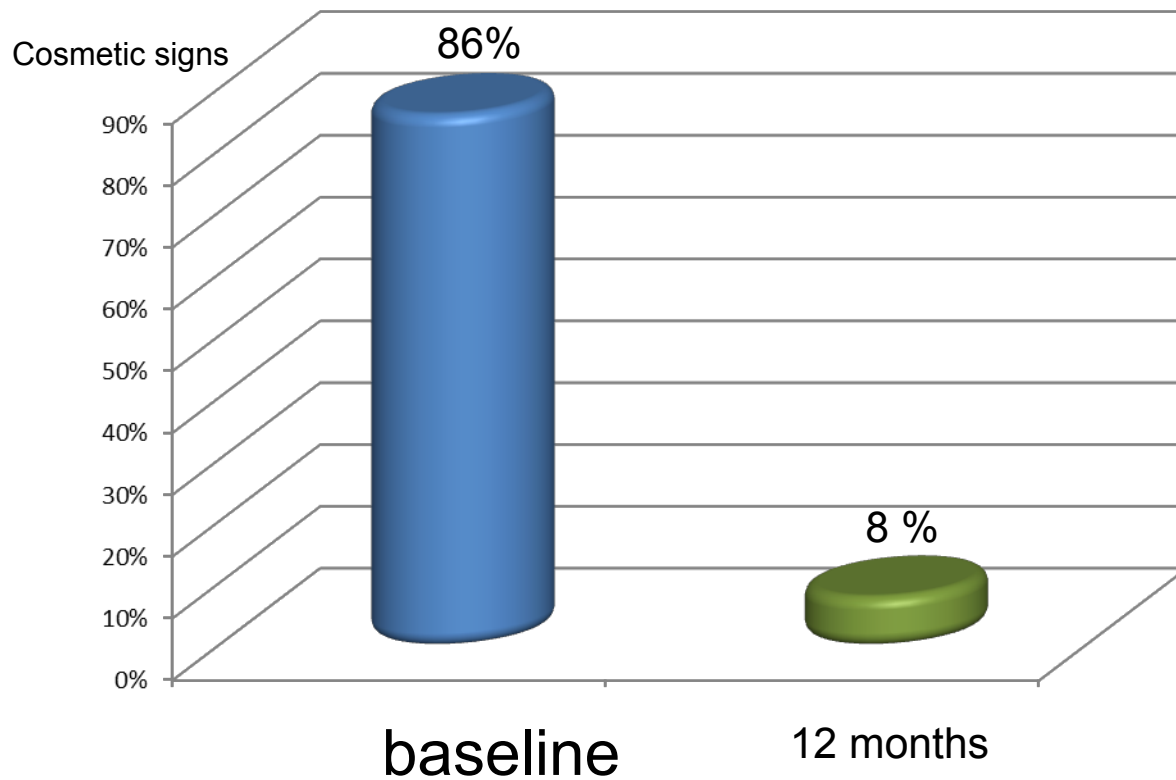
Percentage volume decrease (%)
after 12 months



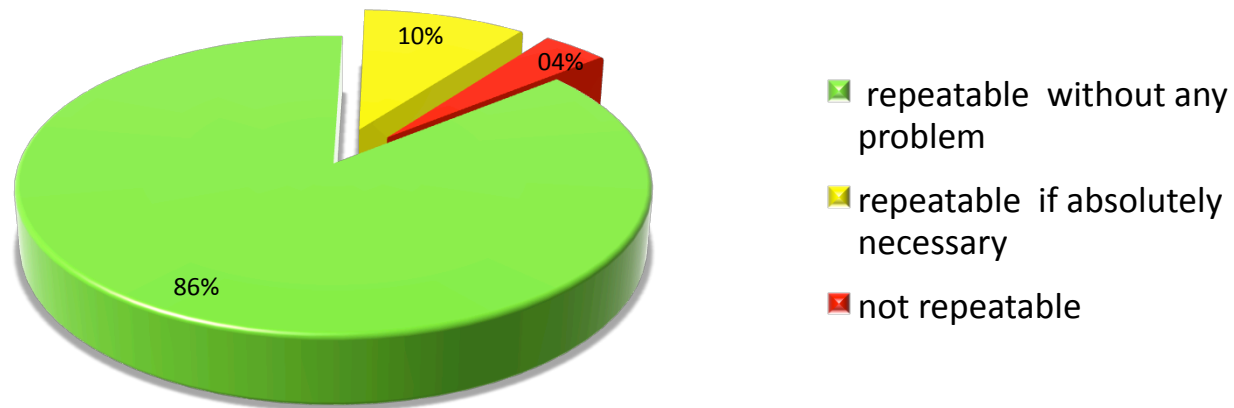
LOCAL SYMPTOMS CHANGES: 12 MONTHS VS BASELINE



COSMETIC SIGNS (NODULE VISIBILITY) CHANGES: 12 MONTHS VS BASELINE

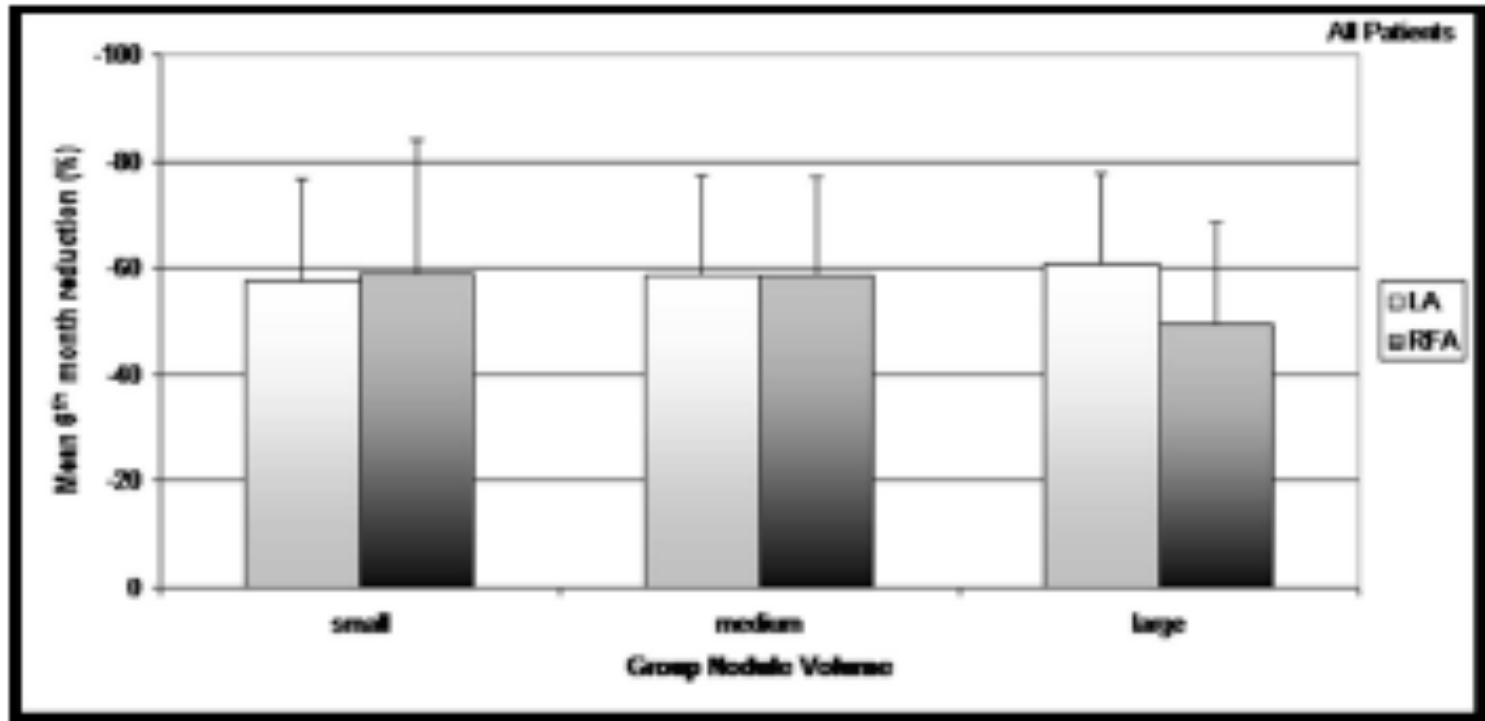


Discomfort Induced By Laser Treatment

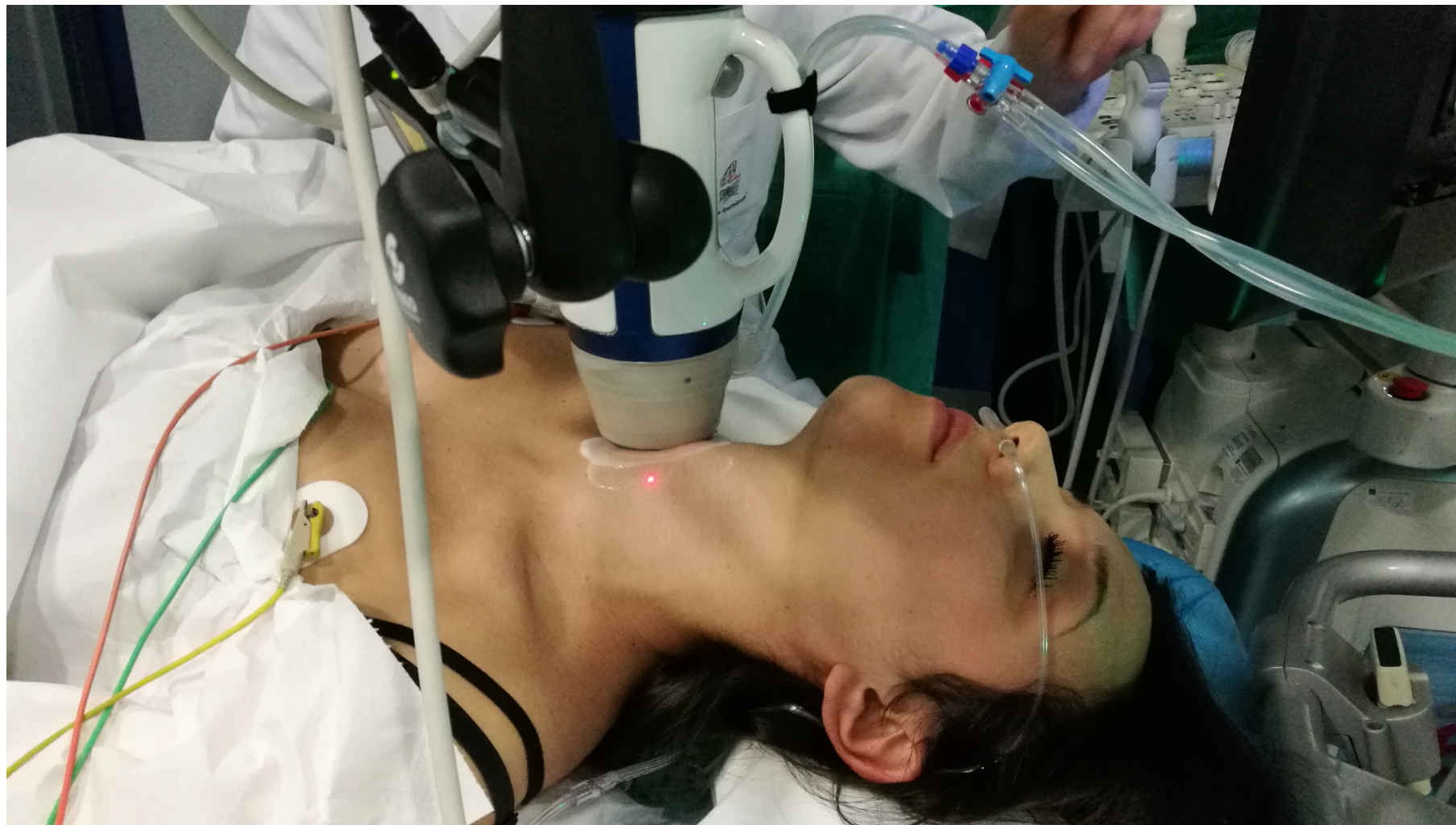

PAIN WAS REPORTED AS MILD AND SHORT-TERM BY 86% OF TREATED PATIENTS

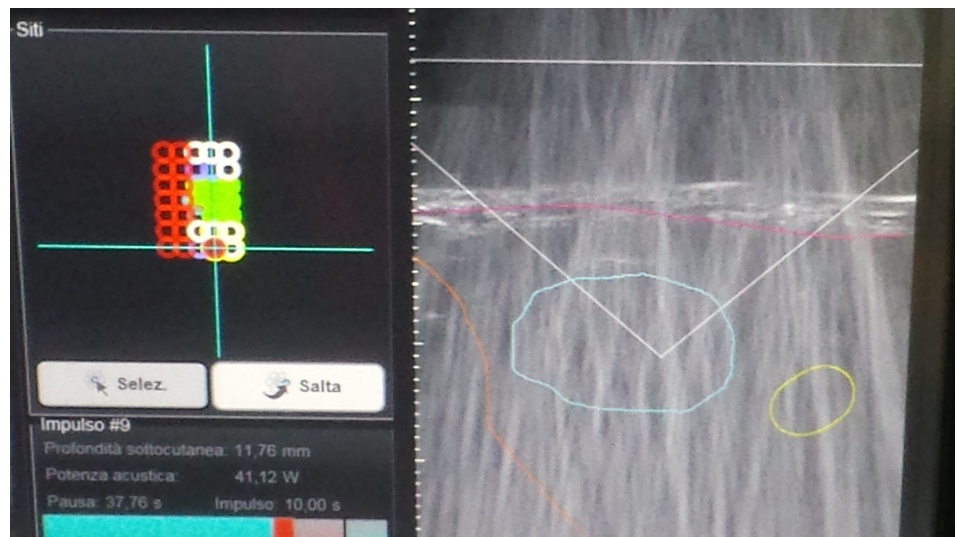
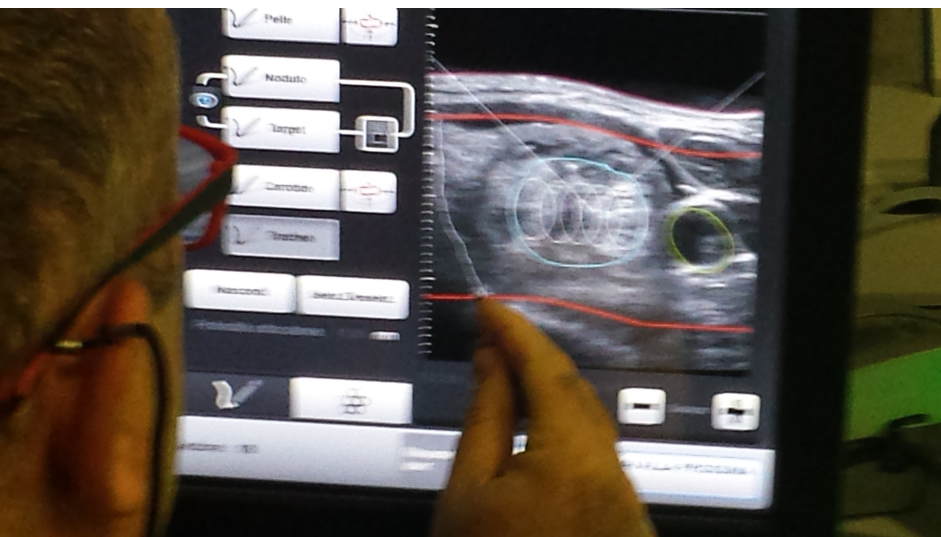
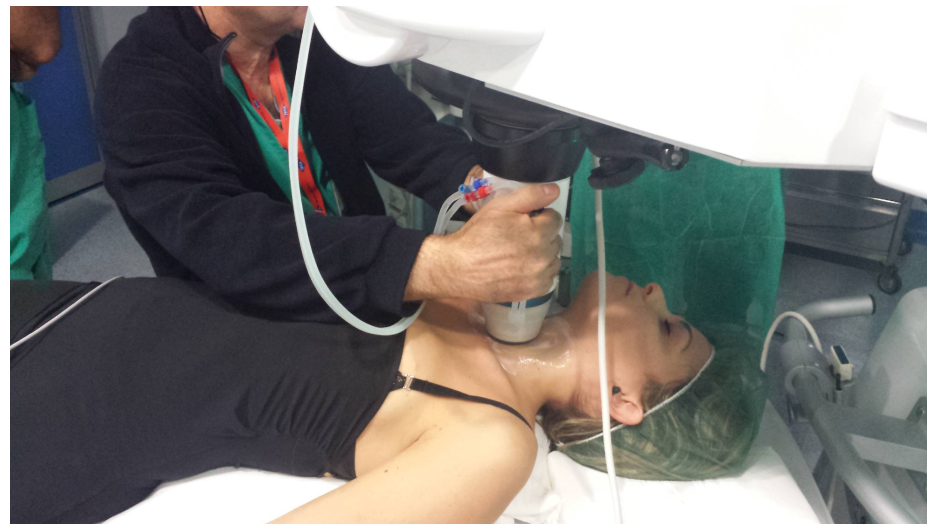
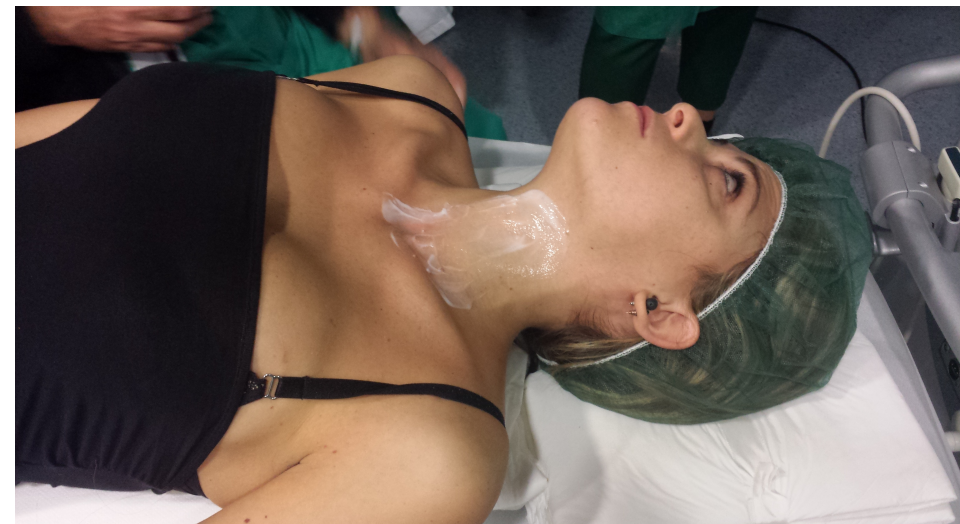A Comparison of Laser with Radiofrequency Ablation for the Treatment of Benign Thyroid Nodules A Propensity Score Matching Analysis



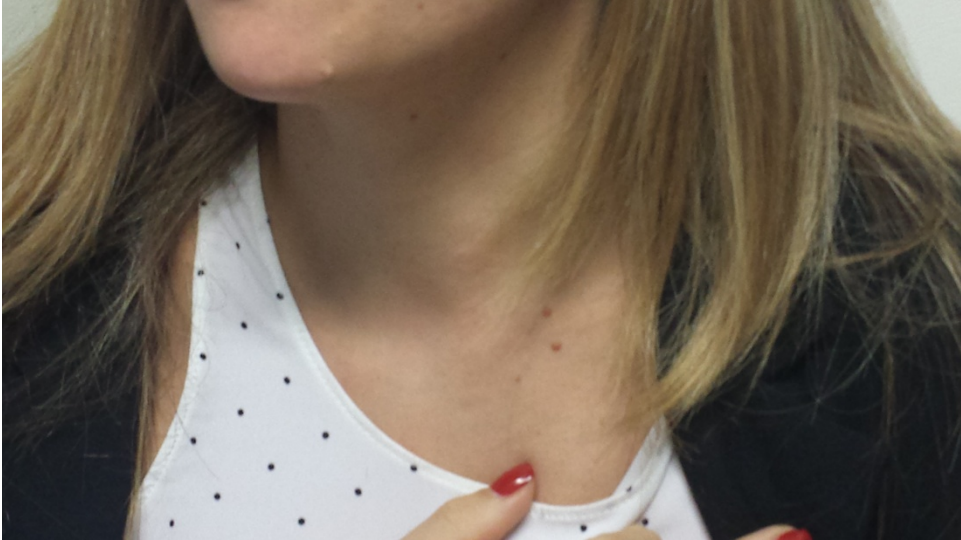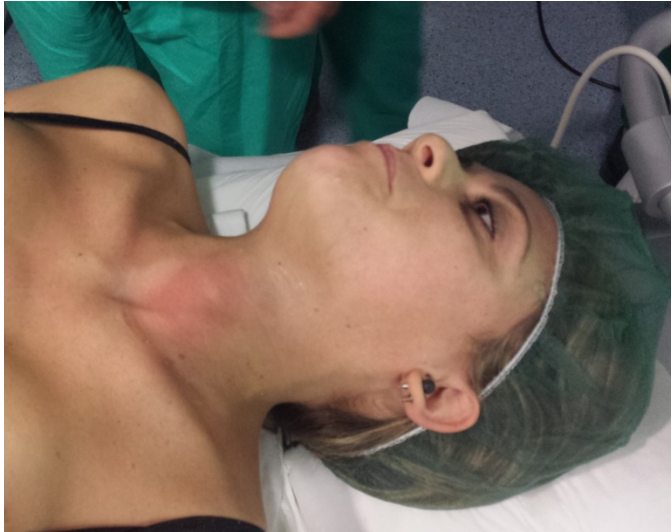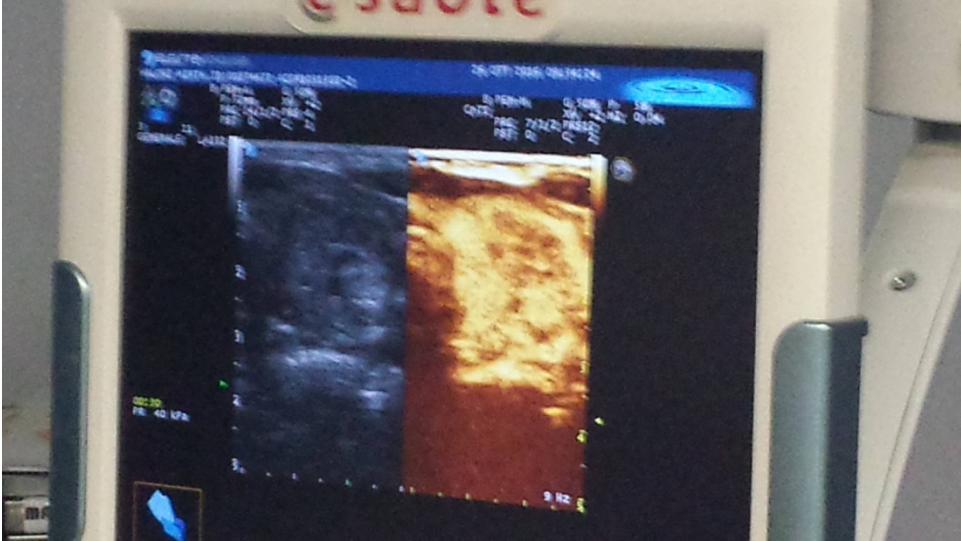High Focused Ultrasound

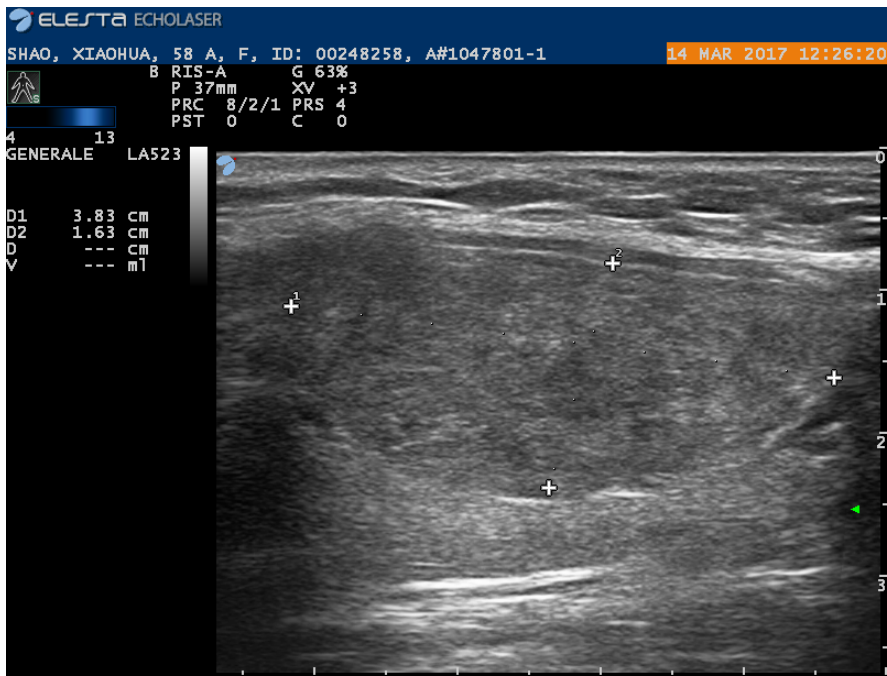


HIFU Procedure

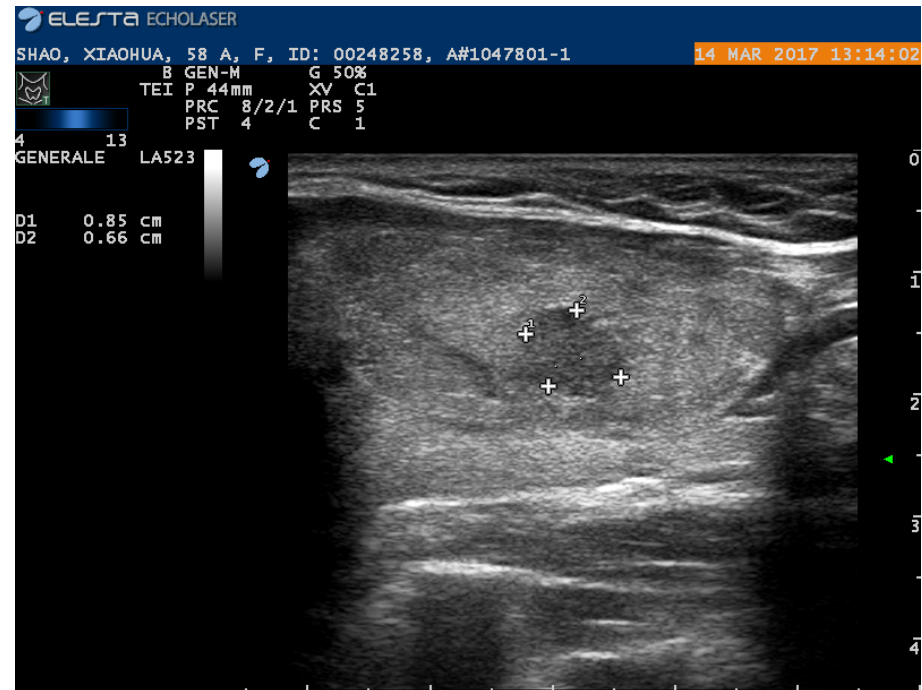
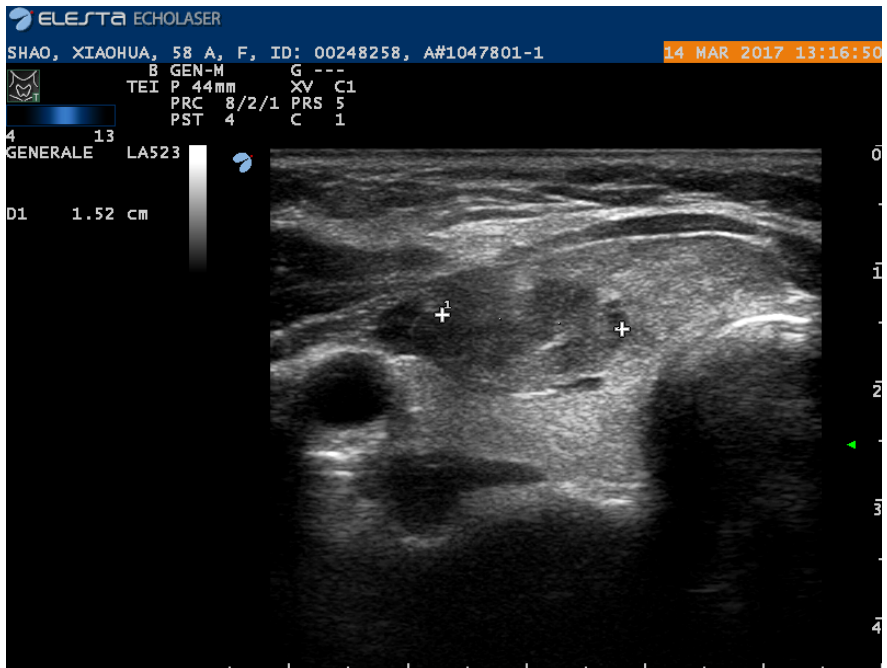


HIFU Procedure 2.



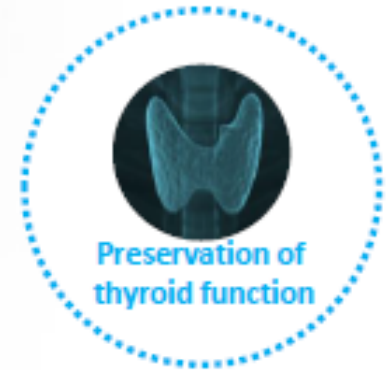

US pattern 1 hour after HIFU treatment



Localized thyroid tissue ablation by HIFU: Volume reduction, effect on thyroid function and immune response

H. Korkusuz, M. Sennert, N. Fehre, C. Happel and F. Grünwald; Röfo; 2015



Rationale

Initial demonstration of thyroid nodule volume reduction by high intensity focused ultrasound has been done.

The goal of this study is to assess the effectiveness of the treatment in reducing the volume while preserving thyroid function as measured by immunological response.

Methods

12 patients diagnosed with a single thyroid nodule were treated in one session with ultrasound-guided high intensity focused ultrasound (i.e. echotherapy)

Mean thyroid volume at baseline: 3.4mL [0.6-5.0]

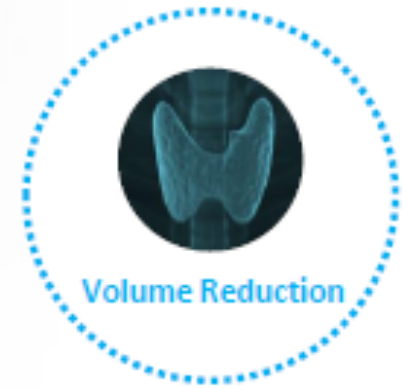Mean patient age: 56.9y [37-81]

Treatment on an outpatient basis and under local anesthesia

- **Small size nodules (median volume 3.4 mL)**
- **12 patients (partly same cases?)**
- **Local anesthesia**
- **Mean volume reduction vs baseline: 48%**

Single-session High Intensity Focused Ultrasound (HIFU) Treatment in Large-sized Benign Thyroid Nodules

Brian Hung-Hin LANG; Yu-Cho WOO; Keith Wan-Hang CHIU; Thyroid; March 2017



Rationale

High Intensity Focused Ultrasound (HIFU) is a new, promising thermal ablation technique in treating benign thyroid nodules but its effectiveness in larger-sized nodules has been less well described. The present study aimed to evaluate the treatment efficacy (i.e. extent of shrinkage at 6-month) of large-sized benign thyroid nodules by ultrasound-guided HIFU ablation (echotherapy).

Methods

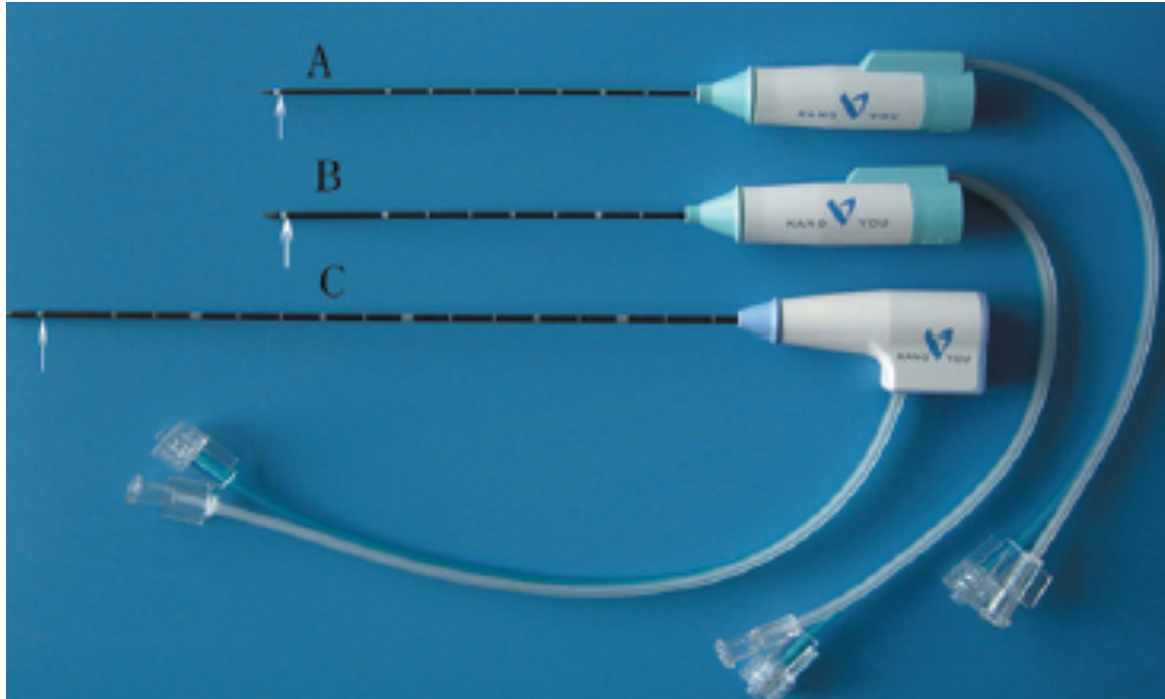
- 73 patients – Treated nodules categorized according to pre-ablation volume (<10 mL (group I), 10 – 30 mL (group II) and >30 mL (group III))
- Single HIFU session
- Nodule volume monitored
 - 1 week
 - 1 – 3 – 6 months

- **73 patients in 3 groups (< 10 mL, 10-30 mL, > 30 mL)**
- **Single session; 6 months follow-up**
- **Mean volume reduction vs baseline: 68% (Group 3: 48% vs Group 1: 77%)**

Echopulse (HIFU)

- High-intensity focused ultrasound (HIFU) is a completely non-invasive treatment based on the use of high-intensity ultrasound waves
- HIFU demonstrated in non controlled trials a clinically significant efficacy with a 50% mean nodule volume reduction
- HIFU treatment is well-tolerated and devoid of major complications.

MicroWaves



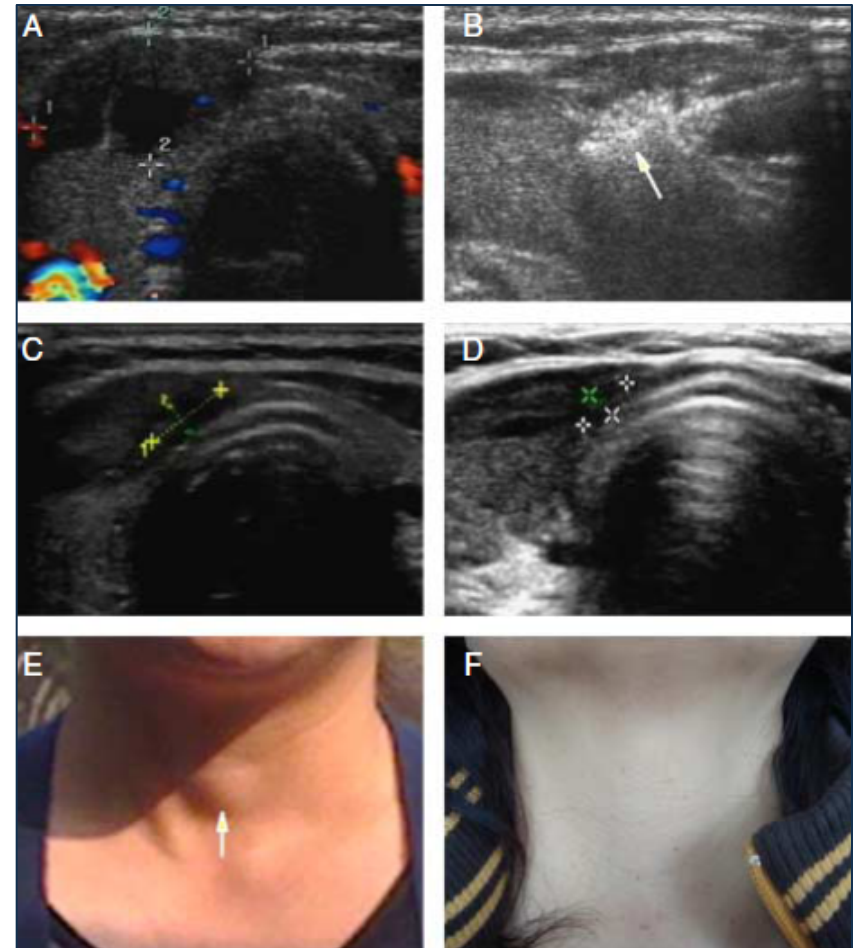
- (A) 16 G antenna, 10 cm long with 3mm radiating segment, designed to treat superficial (neck) lesions <10mm in diameter
- (B) 16 G antenna with 5 mm radiating segment for larger superficial lesions
- (C) 14 G antenna, 20 cm long with 11 mm radiating segment, designed for abdominal lesions.


CLINICAL STUDY

Ultrasound-guided percutaneous microwave ablation of benign thyroid nodules: experimental and clinical studies

Bing Feng, Ping Liang, Zhigang Cheng, Xiaoling Yu, Jie Yu, Zhiyu Han and Fangyi Liu

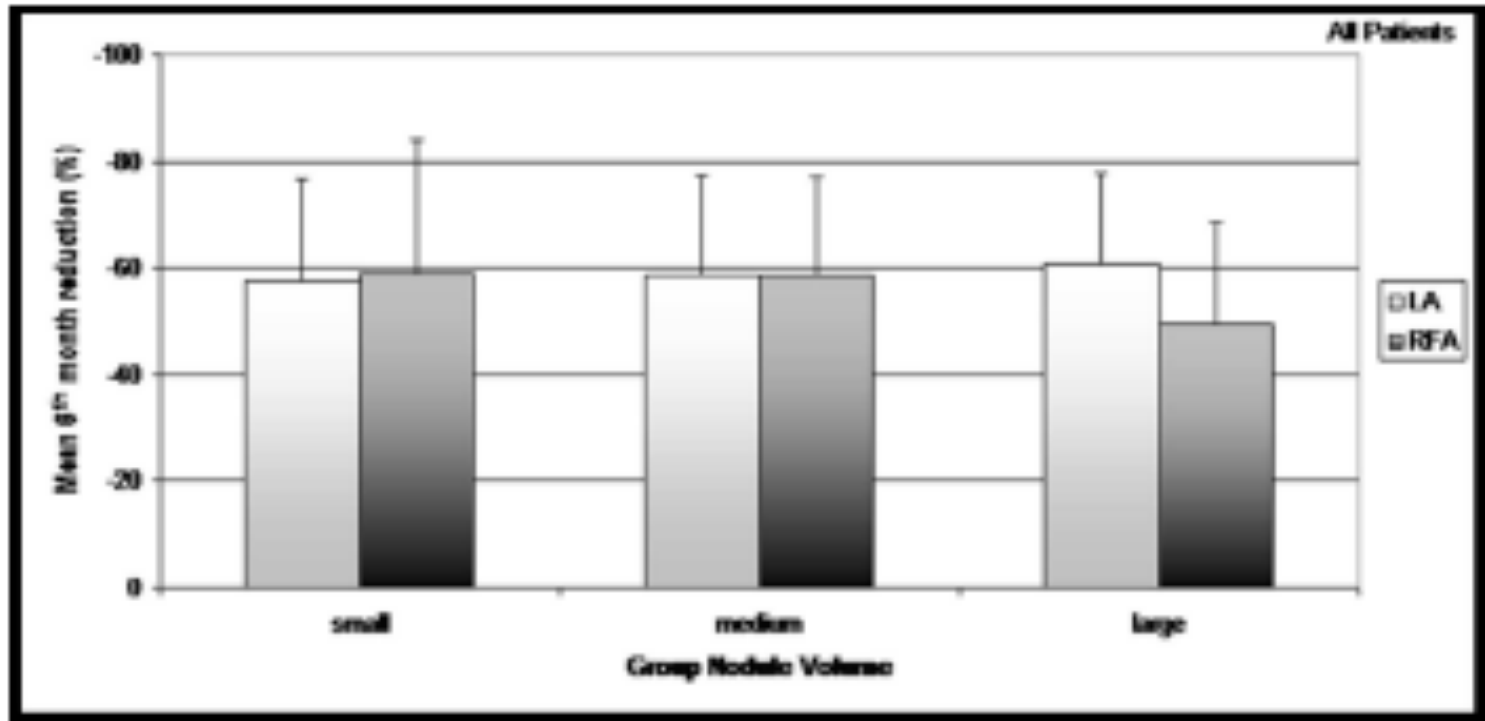
- Local anesthesia and conscious sedation
- Internally-cooled 16 G MW antenna
- 12 month US follow-up
- Nodule volume decrease: 46% vs. baseline
- Several major and minor side-effects.





Which are the advantages and disadvantages of the various techniques?

A Comparison of Laser with Radiofrequency Ablation for the Treatment of Benign Thyroid Nodules A Propensity Score Matching Analysis



Comparative Efficacy of RF and Laser Ablation for the Treatment of Benign Thyroid Nodules

	Initial		Treatment Session	Follow-Up, mo	Outcomes		
	Volume, mL	Solidity			Volume, mL	Complication	Pain
Døssing (16)	10.0	Solid	1	6	5.4	–	+
Døssing (35)	9.0	Solid	1	6	5.3	–	+
Døssing (28)	10.1	Solid	1	6	5.7	–	+
	10.7	Solid	3	6	4.6	–	+
Døssing (36)	10.6	Solid	1	6	6.5	–	+
Gambelunghe (37)	10.4	Solid	1	7.5	5.7	+ ^a	+
Døssing (38)	10.6	Solid	1	6	4.6	–	+
Papini (39)	11.7	Solid	1	12	6.2	–	+
Bæk (40)	7.5	Solid	1	6	1.3	–	+
Huh (24)	13.3	Solid	1	6	3.8	–	+
	13.0	Solid	2	6	3.0	–	+
Faggiano (41)	13.3	Solid	1	6	3.2	–	–

Tx	LA	RFA	Control	Prob Best	Rank
LA		–28.31 (–53.26, –3.39)	49.53 (26.66, 72.36)	.01316	2
RFA			77.84 (67.7, 87.97)	.9868	1
Control				.0	3


Ha et al., J Clin Endocrinol Metab 100: 1903–1911, 2015

Outcomes and Risk Factors for Complications of Laser Ablation for Thyroid Nodules

Hospital	Patients, n, Males/Females	Age, y ^a	BTNs, n	Volume of BTNs ^a	Sessions, mean	VR at 12th mo	Patients Treated With Two or More BTNs, n	Local Anesthesia	Sedation, Yes/No	Major Complications, n, % ^b	Minor Complications, n % ^b	Side Effects, n, % ^c
Albano Laziale	341, 110/231	51.5 ± 13.7	341	13 ± 12 (2–126)	1.5	6.7 ± 10		Yes	No	1 (0.3)	1 (0.3)	37 (10.9)
Atri	138, 22/116	52.1 ± 12.1	138	13 ± 9 (1.5–45)	1	7.6 ± 8		Yes	Yes	3 (2.2)	2 (1.4)	20 (14.5)
Alzano Lombardo	36, 4/32	58.6 ± 15.0	36	5 ± 3 (2–21)	1	8.4 ± 5		Yes	Yes	0 (0.0)	0 (0.0)	1 (2.8)
Bari	45, 10/35	52.0 ± 13.3	45	24 ± 19 (1.4–93)	1	9.2 ± 13		Yes	Yes	1 (2.2)	0 (0.0)	13 (28.9)
Cosenza	242, 62/180	54.4 ± 11.8	242	19 ± 13 (1.9–84)	1	7.6 ± 8		Yes	No	0 (0.0)	0 (0.0)	54 (22.3)
Livorno	334, 111/223	51.6 ± 31.1	337	49 ± 18 (10–78)	1.4	6.8 ± 8	3	No	No	1 (0.3)	0 (0.0)	184 (54.6)
Perugia	58, 26/32	58.1 ± 8.9	58	25 ± 29 (7–215)	1.1	7.6 ± 7		Yes	Yes	2 (3.4)	2 (3.4)	51 (87.9)
Perugia	189, 81/108	56.1 ± 9.9	189	20 ± 24 (3–216)	1.1	7.3 ± 11		No	Yes	0 (0.0)	4 (2.1)	71 (37.6)
Pisa	148, 18/130	52.6 ± 13.0	148	47 ± 27 (6–172)	1.1	7.2 ± 11		No	Yes	0 (0.0)	0 (0.0)	32 (21.6)
Combined Hospitals	1531, 444/1087	54.1 ± 14.3	1534	27 ± 24 (1.4–216)	1.2	7.2 ± 11	3			8 (0.5)	9 (0.6)	463 (30.2)

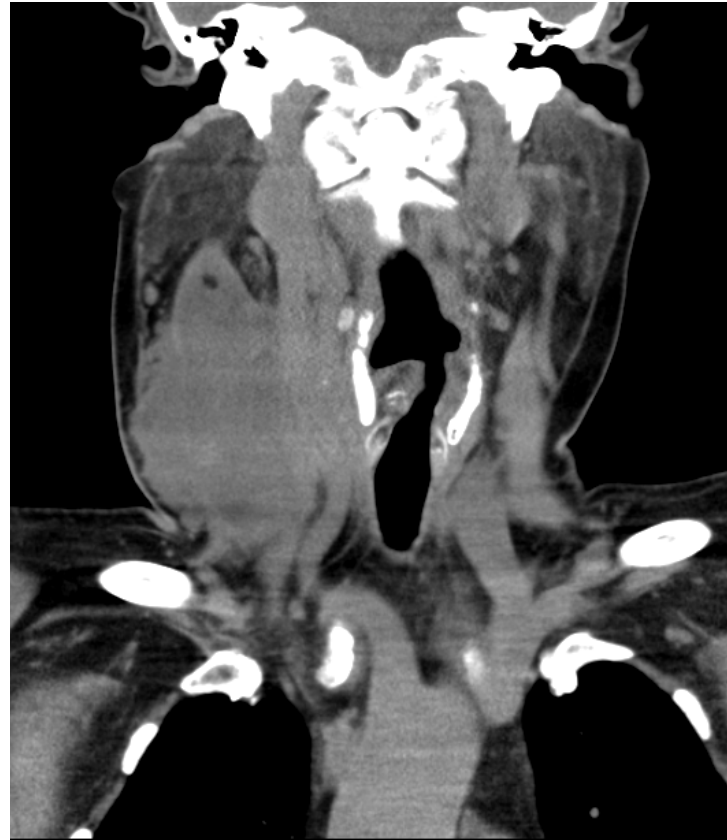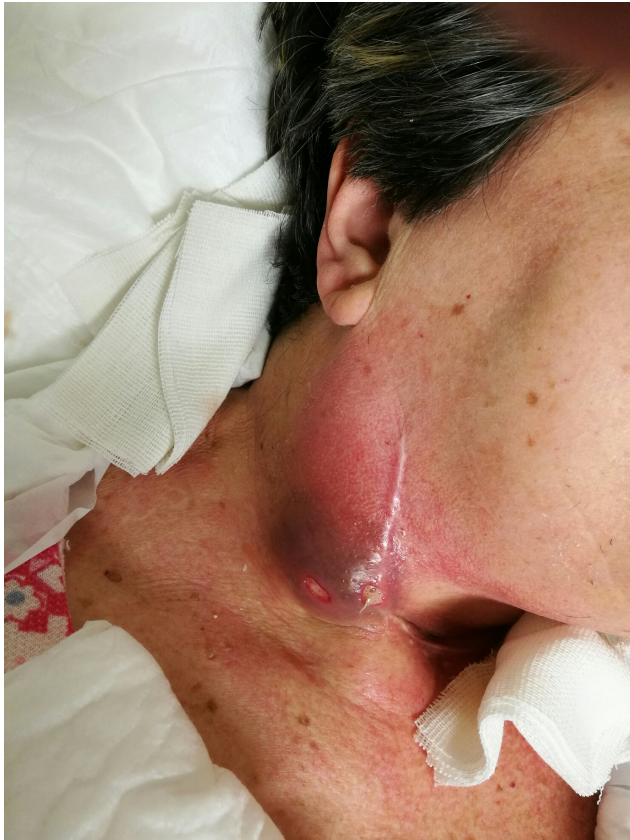Efficacy, Cost, Indications & Limits of MITs

	PEI	PLA	RFA	MW	HIFU
Efficacy	+++	+++	+++	?	+
Safety	+++	+++	++	-/?	+++
Cost	+	++	+++	?	+++++
Training	+	++	+++	?	++
Indication	Cystic & complex lesions	Solid nodules & Recurrence	Solid nodules & Recurrence	?	Selected nodules



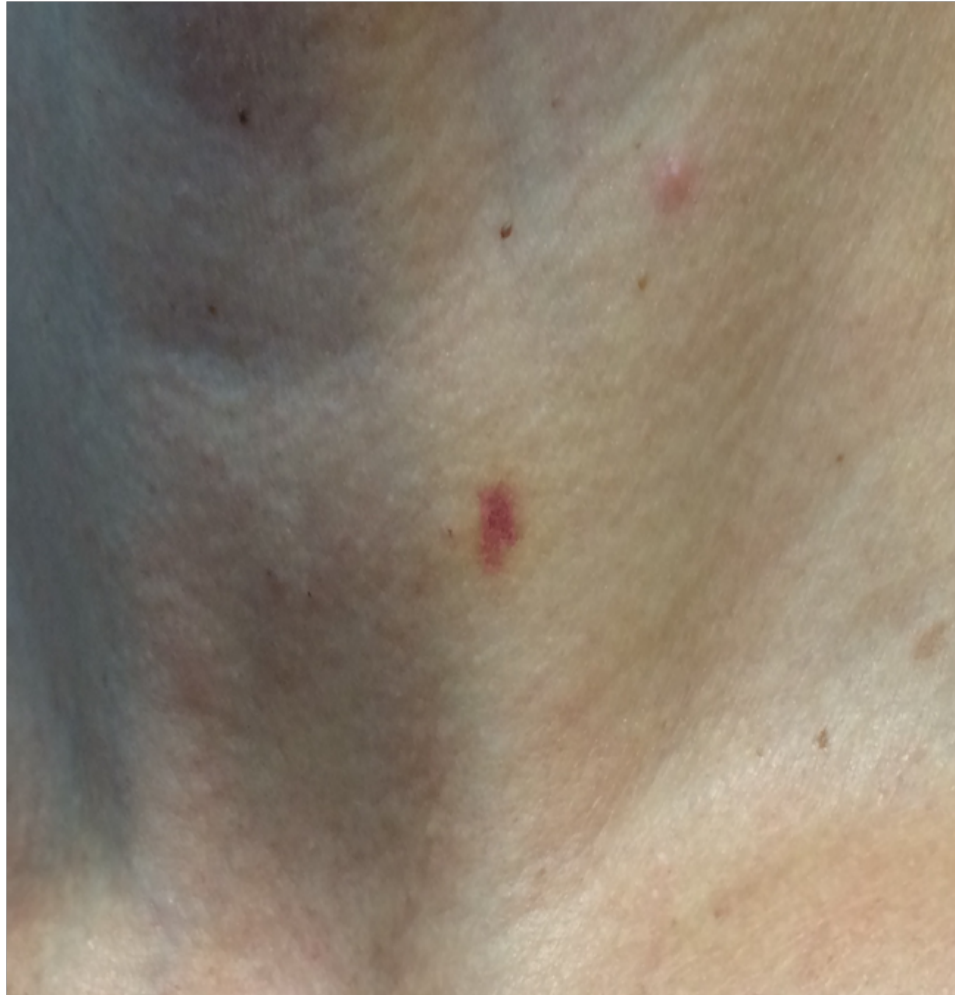Take Care:
Complications are
rare but may be
relevant

COMPLICATIONS OF LAT FOR UNRESECTABLE CANCER



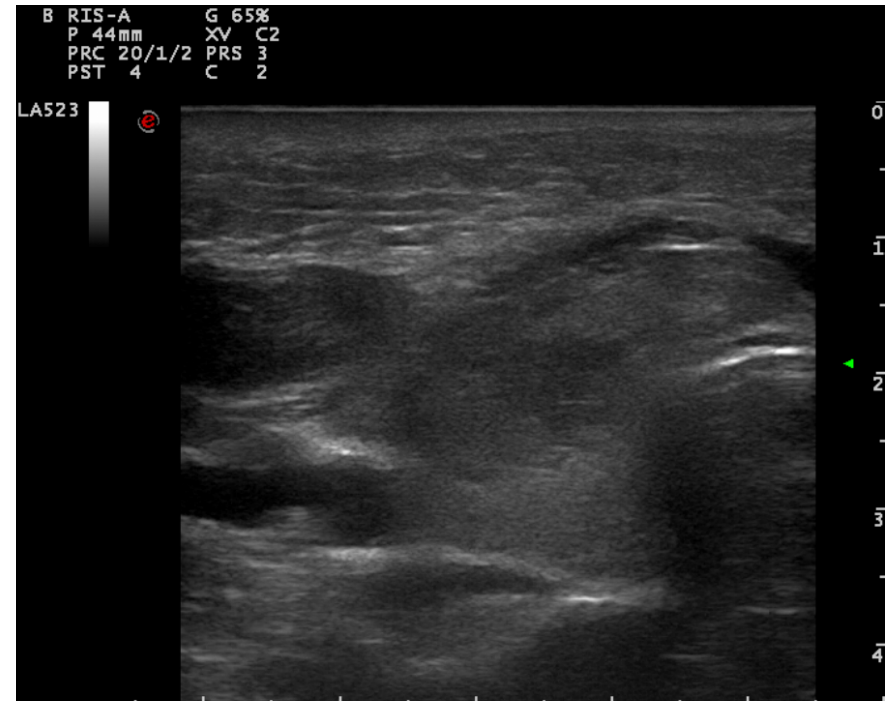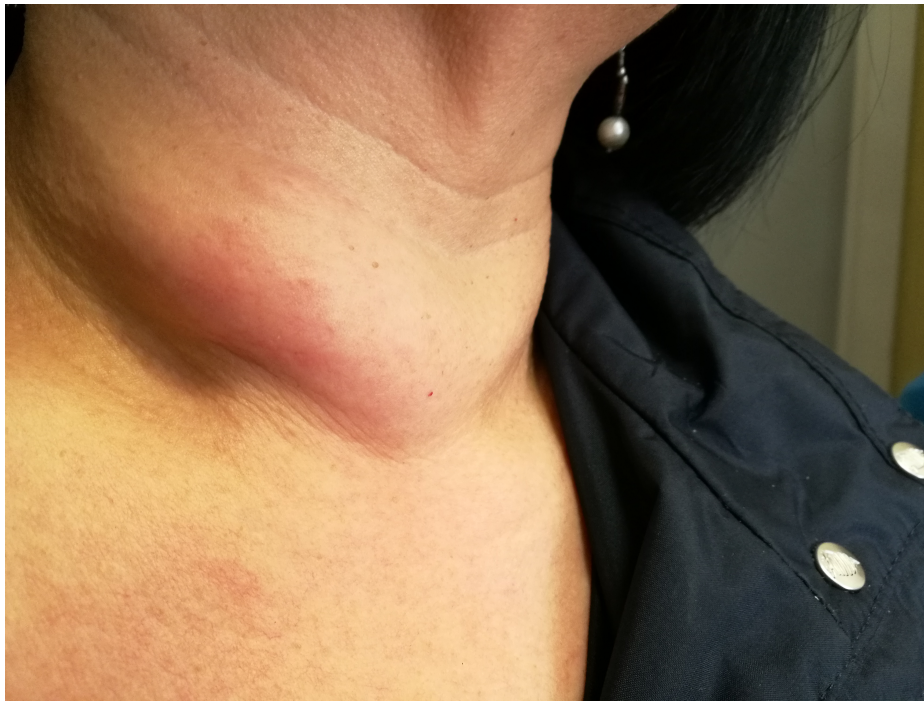Neck abscess treated with drainage and parenteral antibiotics

Skin burn after RFA

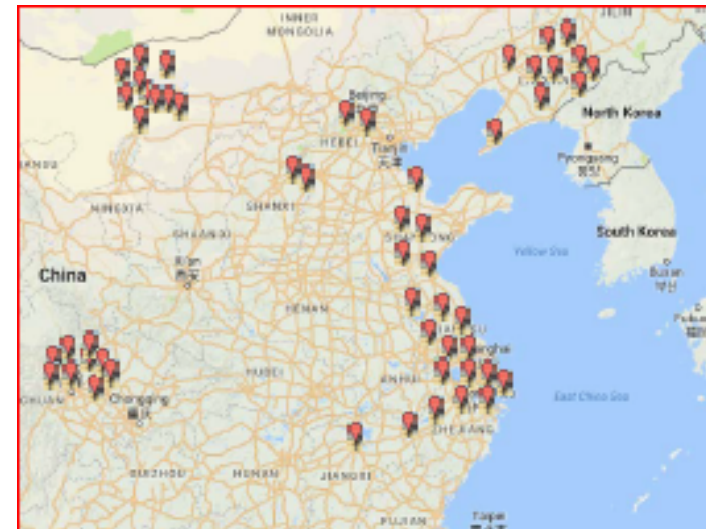
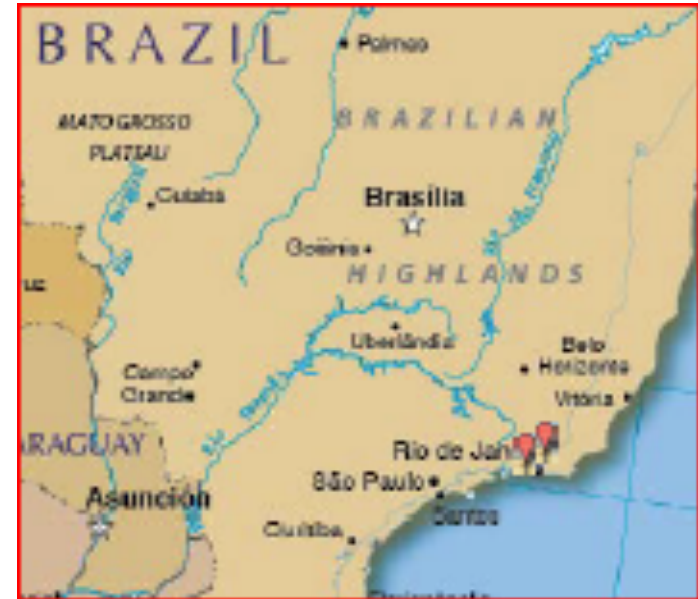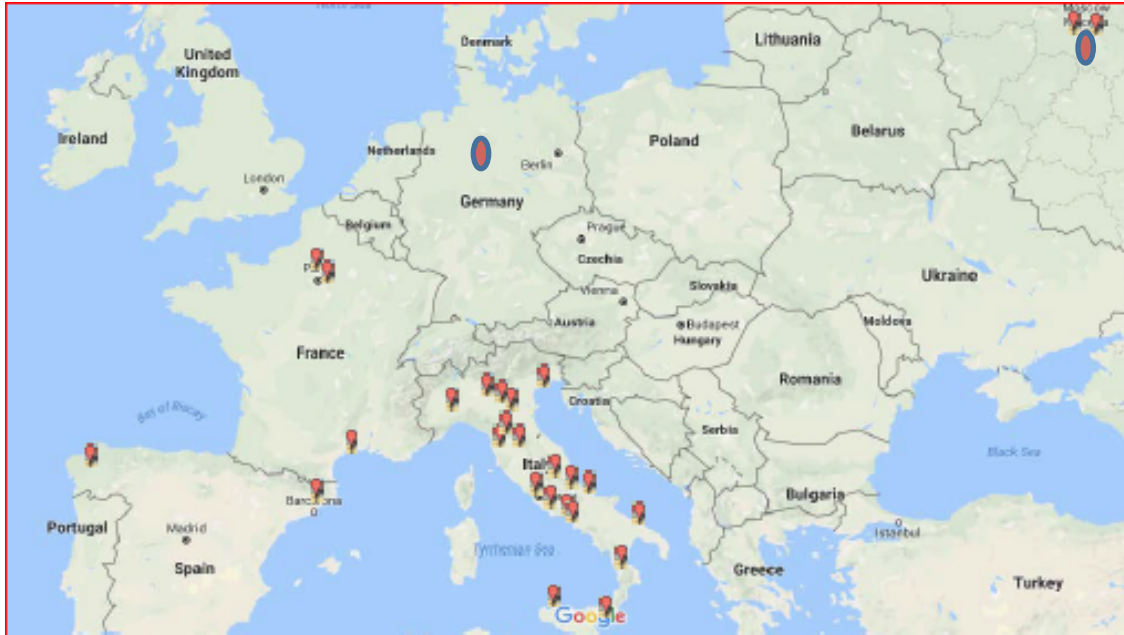


HIFU Complications

Same patient after 24 hours: large area of oedema of soft tissues of the neck



THYROID LESIONS CENTERS FOR LASER TREATMENT



Conclusions (1)

- Minimally invasive procedures (MIT) are effective tools for symptomatic non-functioning thyroid nodules
- Malignancy should be ruled out with two cytological assessments; extended US follow-up is appropriate
- Use MITs in nodular goiters only when a well-defined dominant lesion results in pressure symptoms
- Use MITs in young patients only for small hyperfunctioning lesions or when ^{131}I and surgery are not suitable.

Conclusions (2)

- Thermal ablation results in significant volume decrease and improvement of pressure symptoms
- The procedure does not require anesthesia, is well tolerated, and at very low risk of complications and thyroid function abnormalities
- Treatment requires about 30 minutes and a short post-treatment observation in day hospital
- HIFU is a promising non invasive procedure but is still less effective than LA and RF ablation.

Conclusions (3)

- MIT may be used for local control of non radioiodine-avid neck recurrences of PTC in patients who are not candidate or refuse surgery
- MIT is specifically indicated in patients with previous repeat surgery or surgical complications
- MIT may be considered as an alternative to surveillance in PTMC who are at surgical risk
- Treatments should be performed after multi-disciplinary consultation and information of the patient.

Thank You & Ready for Comments

