



Roma, 8-11 novembre 2018

LG Italiane 2018 per il carcinoma differenziato tiroideo



ITALIAN CHAPTER



Minicorso 1 con SIE e AIT



Moderatori: F. Pacini, E. Papini, P. Vitti
Conduttore: A. Frasoldati

Rischio ecografico e indicazioni a FNA
C. Durante

Il trattamento chirurgico
R. Bellantone

Stratificazione dinamica del rischio
R. Elisei

Terapia ablativa con ¹³¹I
M. Salvatori

Il follow-up
L. Fugazzola



Roma, 8-11 novembre 2018

Conflitti di interesse



ITALIAN CHAPTER

Ai sensi dell'art. 3.3 sul conflitto di interessi, pag 17 del Regolamento Applicativo Stato-Regioni del 5/11/2009, dichiaro che negli ultimi 2 anni **non ho** avuto rapporti diretti di finanziamento con portatori di interessi commerciali in campo sanitario



Roma, 8-11 novembre 2018

2015 ATA guidelines



ITALIAN CHAPTER



“A major goal of these guidelines is to minimize potential harm from overtreatment in a majority of patients at low risk for disease-specific mortality and morbidity, while appropriately treating and monitoring those patients at higher risk”.

Haugen et al., THYROID Volume 26, Number 1, 2016



Roma, 8-11 novembre 2018

Le Linee Guida ATA non vengono dal pianeta Marte



ITALIAN CHAPTER



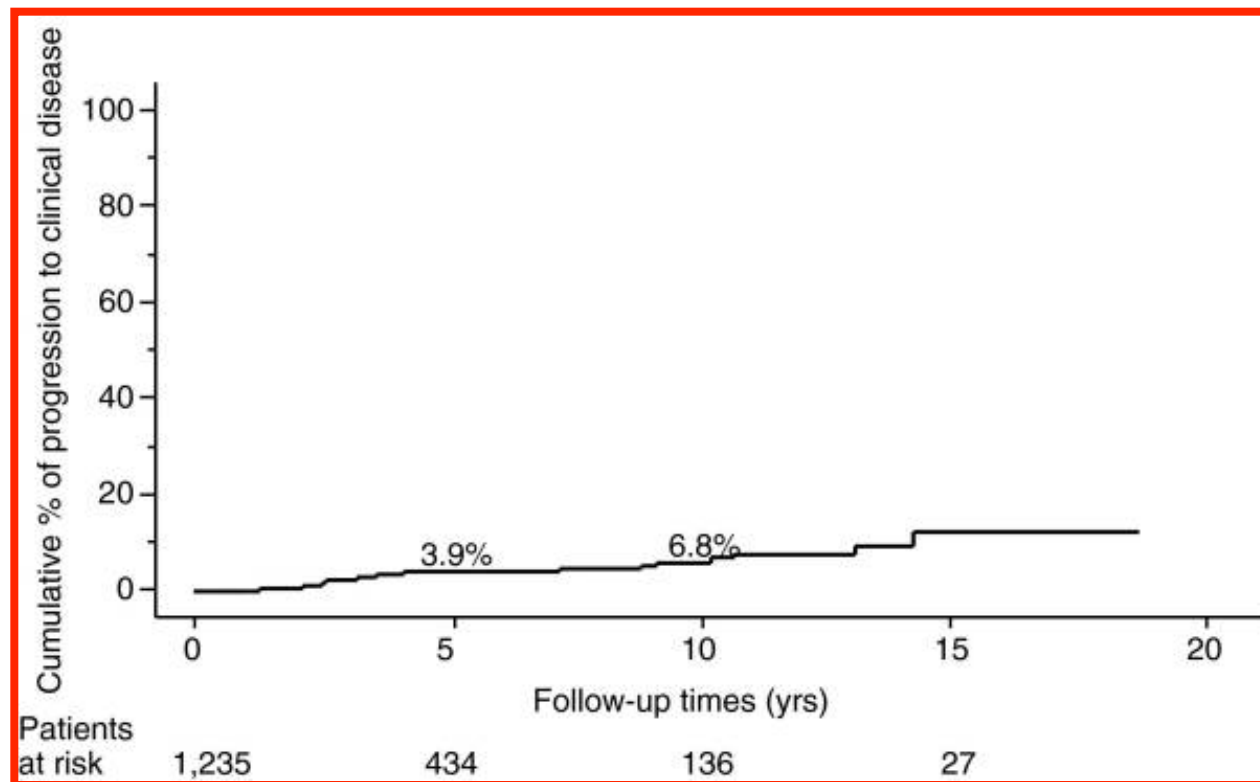


Roma, 8-11 novembre 2018

Patients in the entire series whose PTMC developed into clinical disease



ITALIAN CHAPTER



1235 patients with low-risk PTMC followed with ultrasound
Observation period: 18-227 months (average 75 months)



Roma, 8-11 novembre 2018

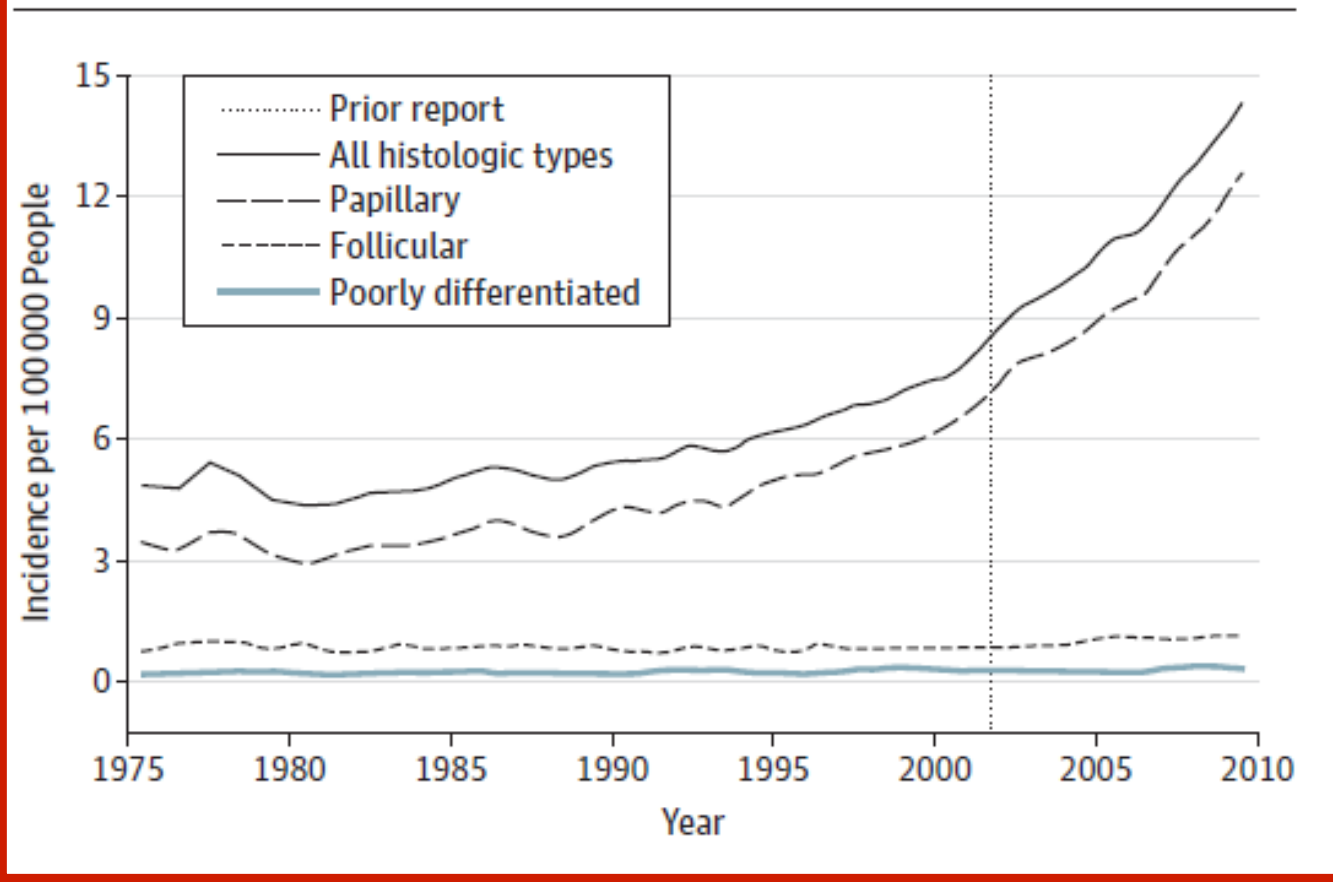
Epidemiology of thyroid carcinoma



ITALIAN CHAPTER



Figure 2. Thyroid Cancer Incidence by Histologic Type, 1975 to 2009





Roma, 8-11 novembre 2018

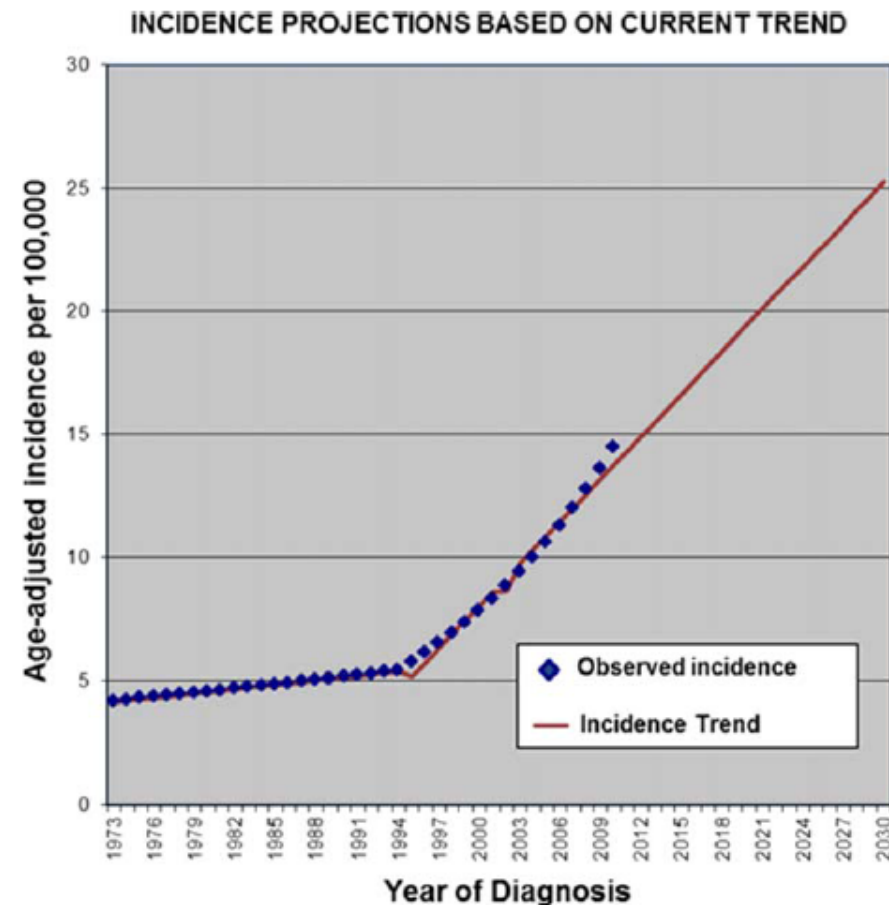
Annual Financial Impact of Well-Differentiated Thyroid Cancer Care in the United States



ITALIAN CHAPTER

The care of patients with WDTC has significant economic and societal impact.

Total estimated costs associated with DTC :
2013 : ~\$1,6 billion
2030 : ~\$3,5 billion





Roma, 8-11 novembre 2018



EDITORIALS

Winding back the harms of too much medicine



ITALIAN CHAPTER



- *The BMJ's Too Much Medicine campaign aims to highlight the threat to human health posed by overdiagnosis and the waste of resources on unnecessary care.*
- *There is growing evidence that many people are overdiagnosed and overtreated for a wide range of conditions, such as prostate and thyroid cancers, asthma, and chronic kidney disease.*

BMJ

BMJ 2013;346:f1271



Roma, 8-11 novembre 2018

PTC Incidence

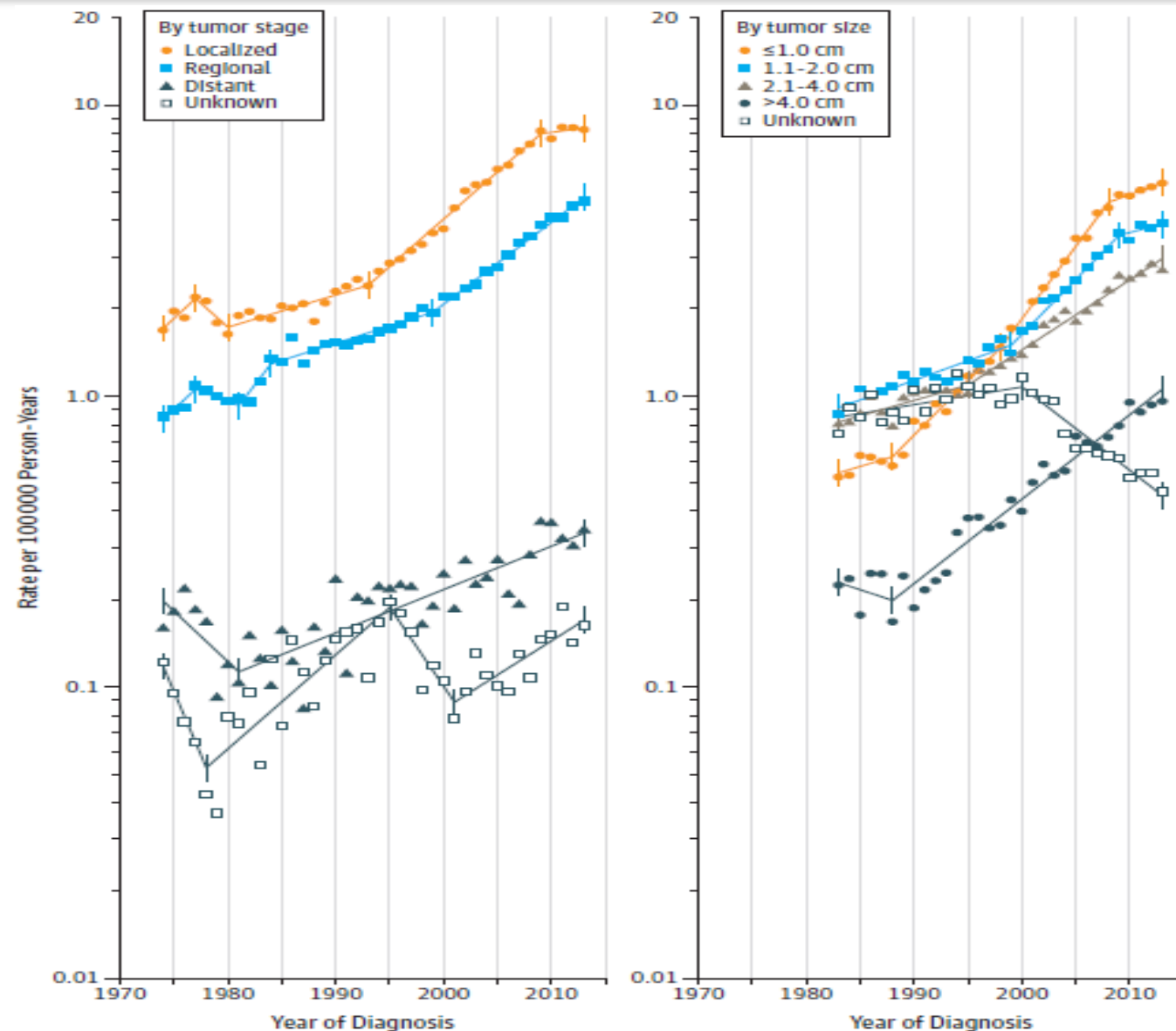


ITALIAN CHAPTER

Advanced-stage and larger PTC incidence rates have increased.

Overdiagnosis may not be solely responsible for the changing trends in PTC incidence

Lin et al., JAMA April 4, 2017 Volume 317





PTC Mortality

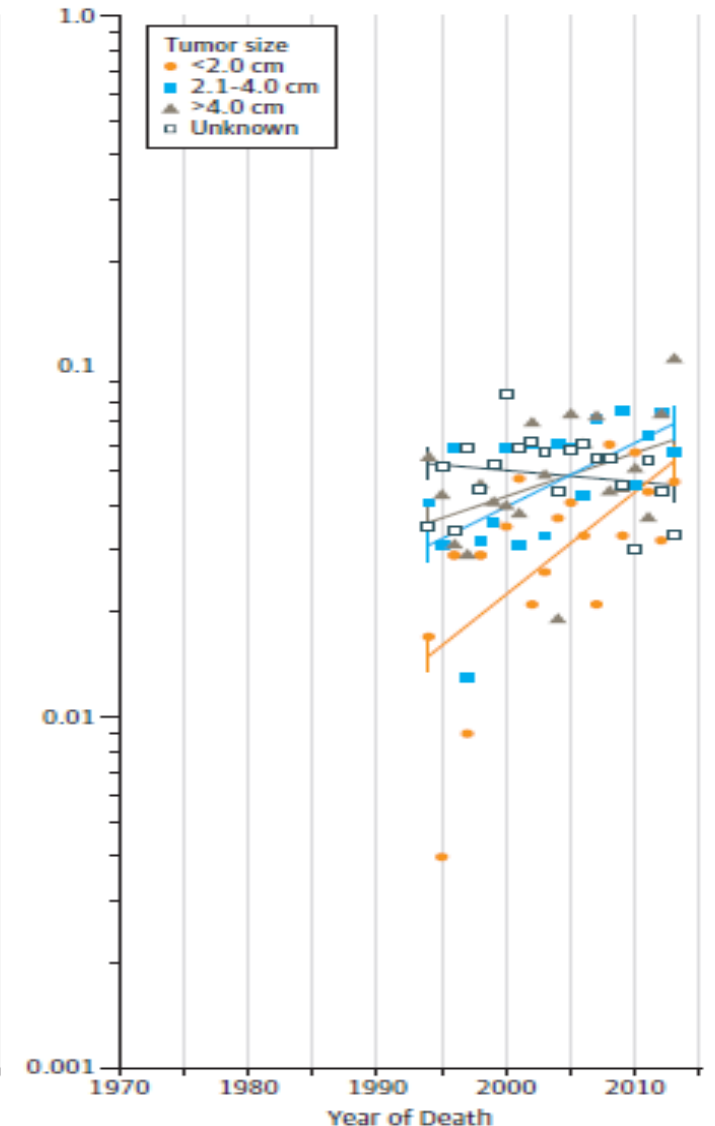
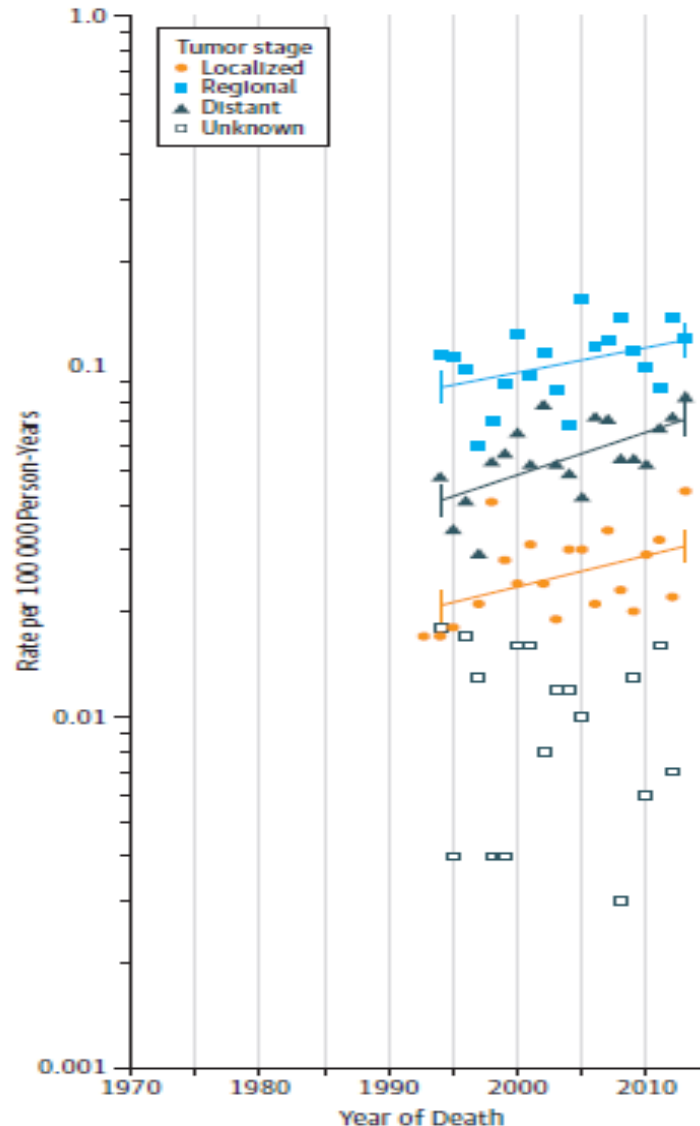


Mortality rates among patients with advanced-stage PTC are increasing.

Hence, there should be renewed focus on aggressive management for the 5%-10% of patients who develop progressive disease.

JAMA April 4, 2017 Volume 317, Number 13

B Papillary thyroid cancer Incidence-based mortality





Roma, 8-11 novembre 2018

Is the Pendulum Swinging Too Far?



ITALIAN CHAPTER



If the explanation for the rise in thyroid cancer is, indeed, not just overdiagnosis, and if mortality from thyroid cancer is also increasing, then enthusiasm for this (non)screening recommendation should be more muted.

Sosa et al., JAMA Surgery 2017 Volume 152, Number 8



Roma, 8-11 novembre 2018

Clinical Guidelines: Angels or Devils?



ITALIAN CHAPTER



Woolf et al. BMJ, vol. 318 20 Feb 1999



Roma, 8-11 novembre 2018

I limiti delle linee guida



ITALIAN CHAPTER

- **Firstly, scientific evidence about what to recommend is often lacking.** Guideline development groups often lack the time, resources, and skills to gather and scrutinise every last piece of evidence.
- **Secondly, recommendations are influenced by the opinions and clinical experience and composition of the guideline development group.** The beliefs to which experts subscribe can be based on misconceptions.
- **Patients' needs may not be the only priority in making recommendations.** Practices that are sub-optimal from the patient's perspective may be recommended to help control costs, serve societal needs, or protect special interests.

Woolf SH et al. *BMJ: British Medical Journal*. 1999;318(7182):527-530.



Roma, 8-11 novembre 2018

Questo significa che ...



ITALIAN CHAPTER

The value judgment made by a guideline development group may be the wrong choice for individual patients.

Woolf SH, Grol R, Hutchinson A, Eccles M, Grimshaw J. Potential benefits, limitations, and harms of clinical guidelines.
BMJ: British Medical Journal. 1999;318(7182):527-530.



Roma, 8-11 novembre 2018

The Italian consensus on differentiated thyroid cancer: joint statements of six Italian societies



ITALIAN CHAPTER



Background

- Differentiated thyroid cancer (DTC), mainly PTC, has emerged as the most rapidly increasing human cancer worldwide.
- The large majority of thyroid cancers detected nowadays is constituted by non-palpable small tumors escaping recognition in the previous years.
- These considerations dictate the need for the more effective, less invasive, and less expensive procedures able to guarantee the best management and the best quality of life for a disease that albeit having an intrinsic low mortality requires life-long follow-up

Pacini et al. Journal of Endocrinological Investigation (2018) 41:849–876



Roma, 8-11 novembre 2018

The Italian consensus on differentiated thyroid cancer: joint statements of six Italian societies



ITALIAN CHAPTER



Scope of the document

- Several countries have developed their own guidelines or consensus reports, based on consolidated experience and cultural attitude of the country. Nevertheless, they differ in several, sometime important aspects.
- The text is not intended to represent classical guidelines, but rather a collection of practical statements on selected relevant issues, based on an adaptation of current guidelines (mainly the ATA) according to the Italian situation and the expert opinion of the multidisciplinary panel.



List of items



- Pre-operative staging
 - Surgical treatment
 - Active surveillance in mPTC
 - Histological report
 - Post-surgical thyroid ablation with ^{131}I
 - Follow-up after initial treatment
 - Risk stratification based on treatment response
 - Metastatic disease treatment
 - RAI resistant disease
 - LT4 treatment
 - Legal Issue
- **Items 3-7**
- **Items 8-11**
- **Items 12-16**
- **Items 17-22**
- **Item 23**
- **Item 24**



Roma, 8-11 novembre 2018

Caso Clinico 1 - Giulia



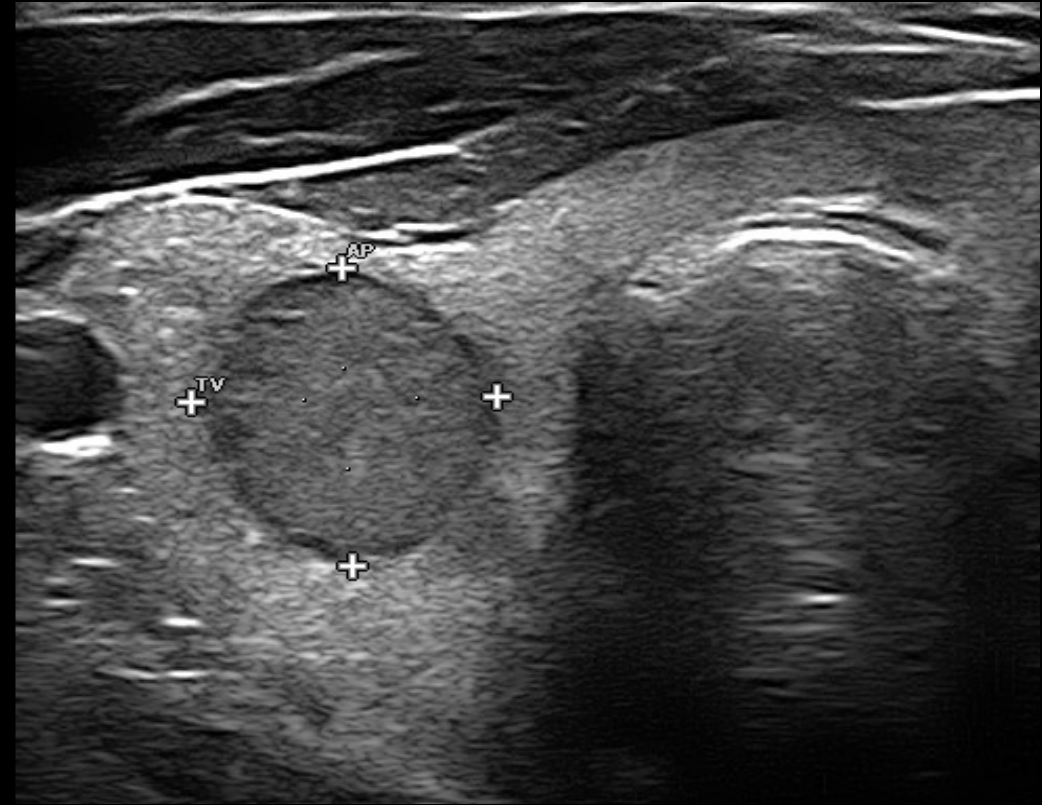
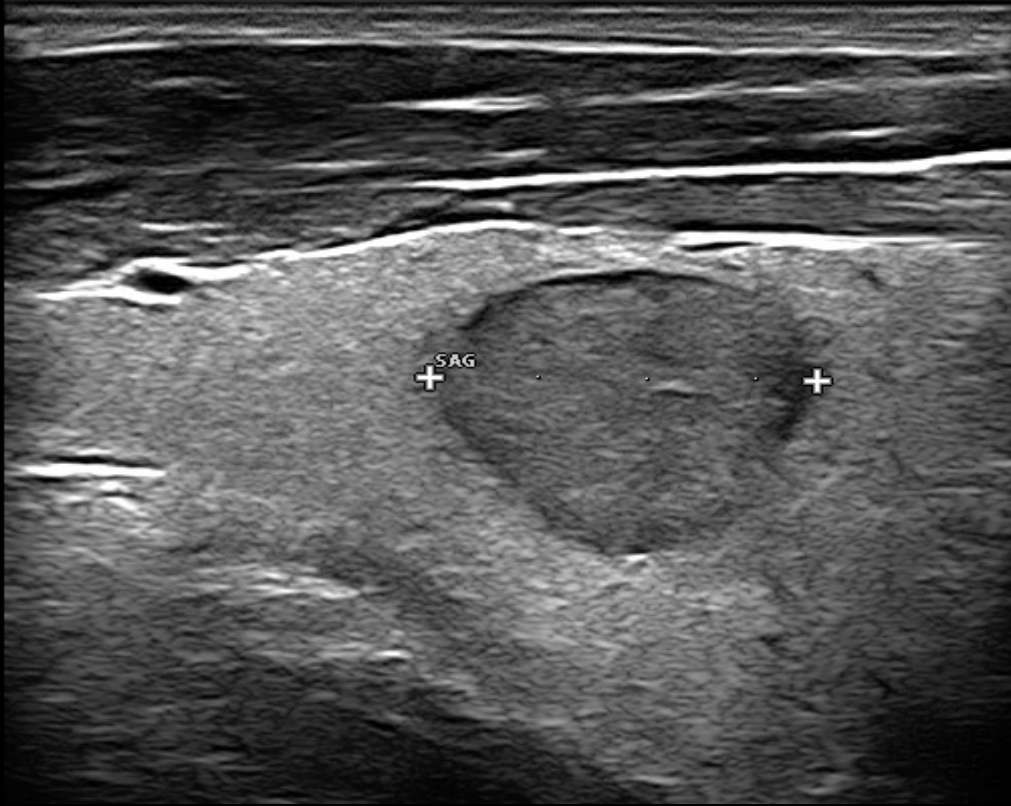
ITALIAN CHAPTER



- Giulia 33 anni. Architetto
- Sposata. Una bimba di 2 anni. Non familiarità per patologia tiroidea
- Anamnesi negativa. Non assume farmaci
- Ecografia tiroidea perché una carissima amica è stata recentemente operata alla tiroide
- TSH 2.2 μ U/ml



Caso Clinico 1 - Giulia



1.77 CM
1.48 CM
1.35 CM
1.9 ml

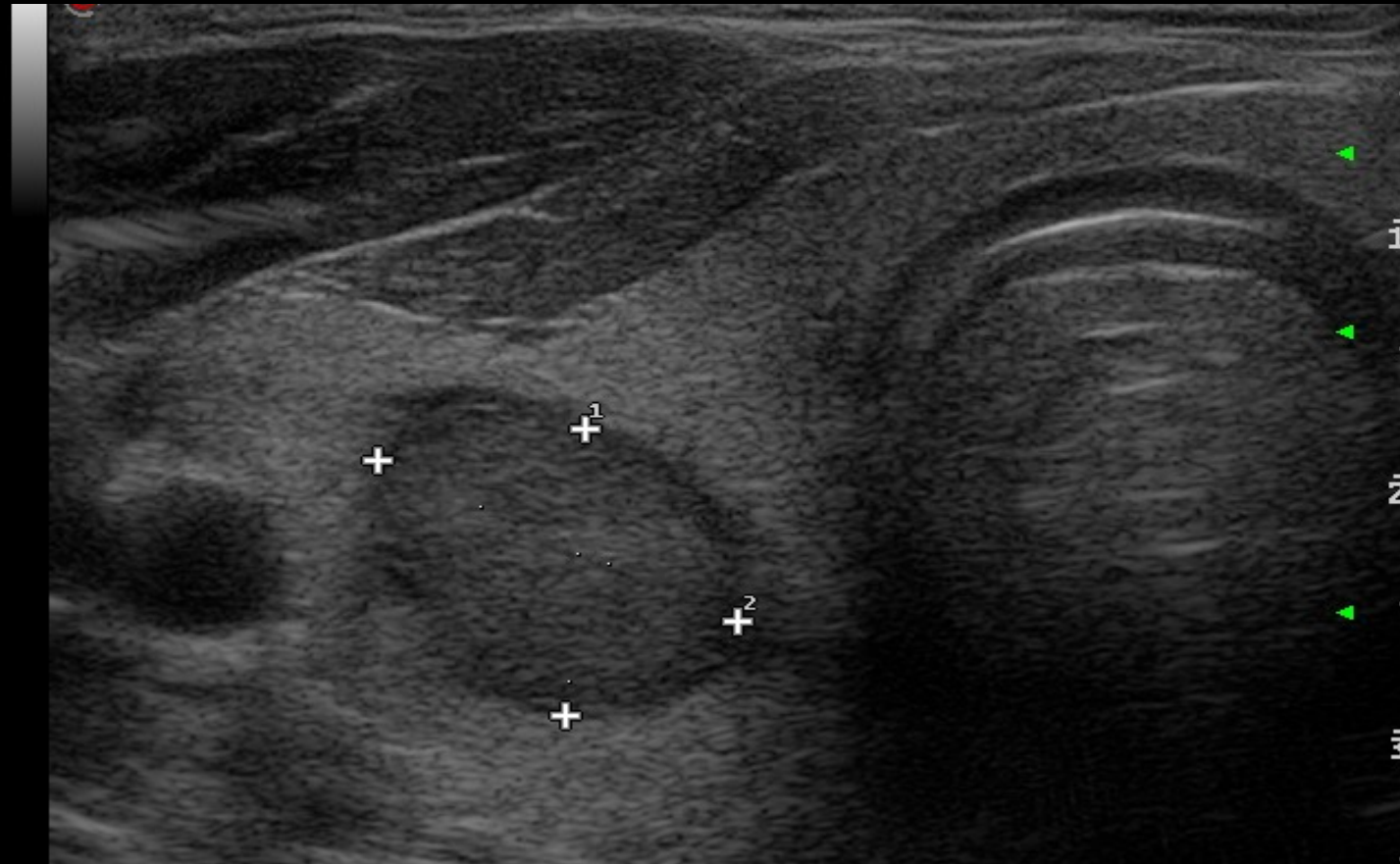


Caso Clinico 1 - Giulia



ITALIAN CHAPTER

D1 1.13 cm
D2 1.40 cm





Roma, 8-11 novembre 2018

Giulia - Report ecografico



ITALIAN CHAPTER



- Tiroide nei limiti per ecostruttura e dimensioni
- Lobo tiroideo dx: nodulo solido ipoecogeno **15 x 13 x 17.5 mm Ø, margini netti e regolari**
- Lobo sinistro indenne da noduli
- Non linfadenomegalie sospette in sede cervicale



Roma, 8-11 novembre 2018

Come classificare il nodulo di Giulia?



ITALIAN CHAPTER



- **Probabilmente benigno**
- **Dubbio**
- **Sospetto/Maligno**



Roma, 8-11 novembre 2018

FNA o wait and see?



ITALIAN CHAPTER



Sottoporreste Giulia a FNA?

- Si
- No



Roma, 8-11 novembre 2018

Caso Clinico 2 - Teresa

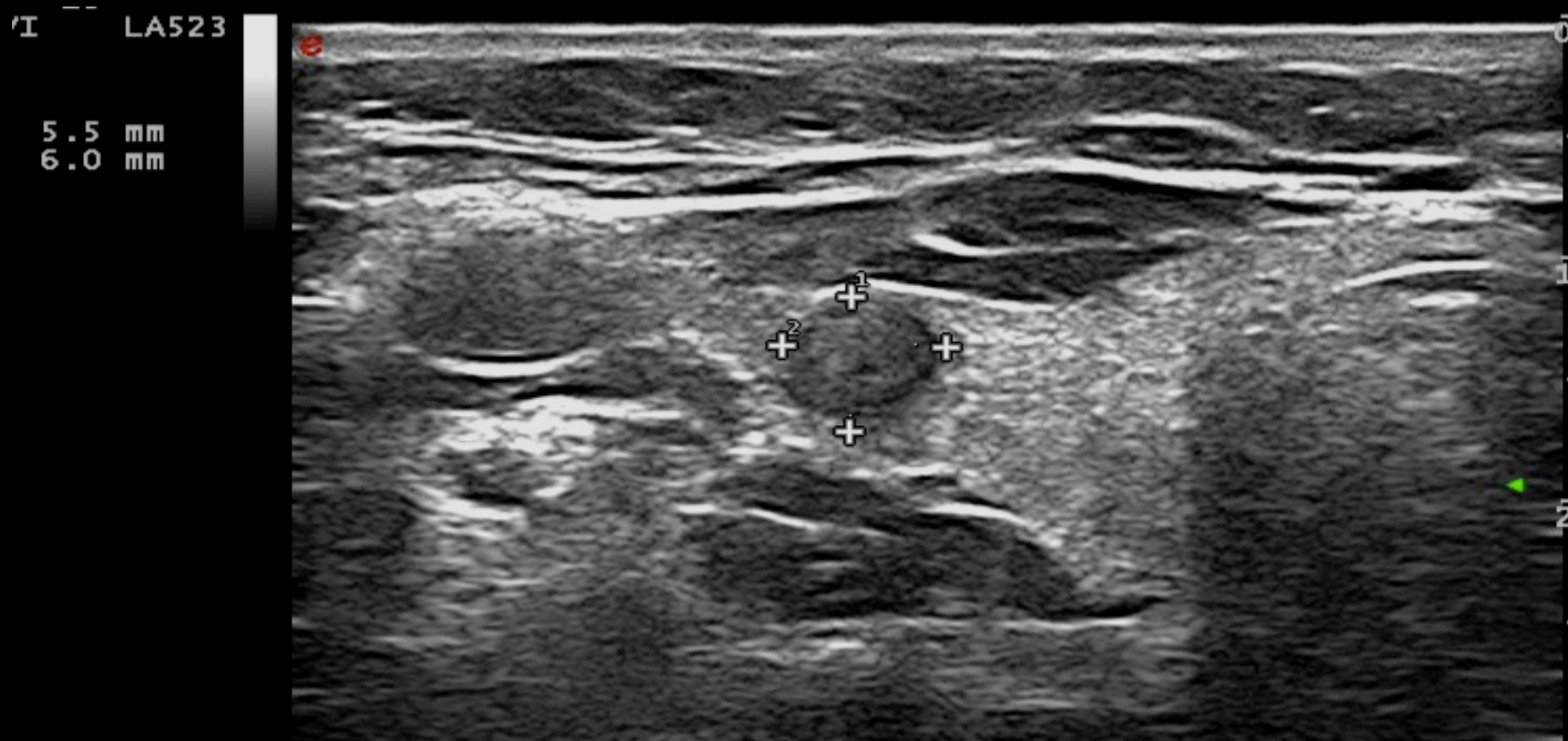


ITALIAN CHAPTER

- Teresa 55 anni. Barista
- Colectomia all'età di 45 anni. Un fratello operato per "tumore tiroideo"
- Non assume farmaci
- Si sottopone ad ecografia tiroidea per persistente "fastidio" alla deglutizione
- TSH 1.1 μ U/ml.

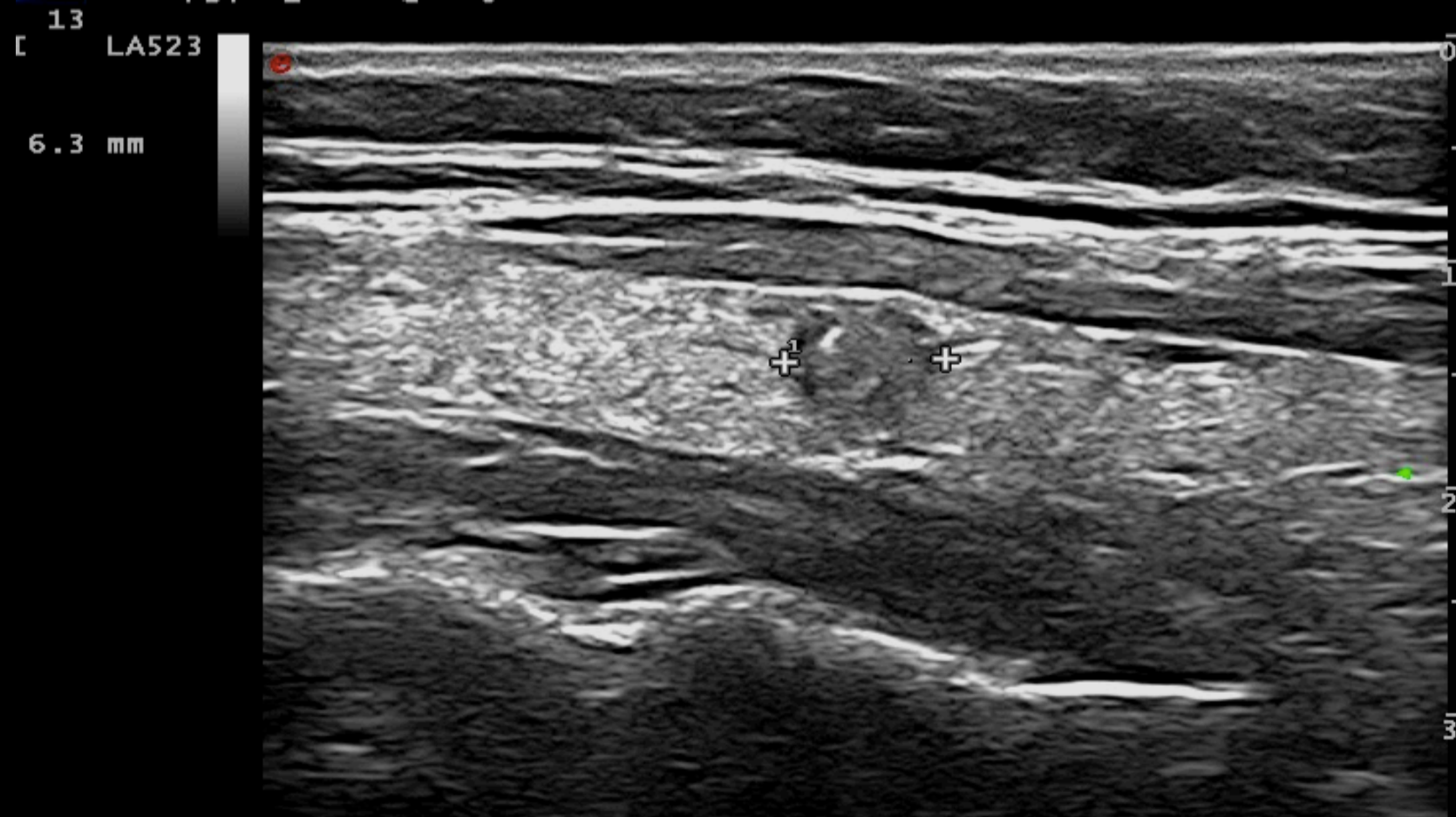


Caso Clinico 2 - Teresa



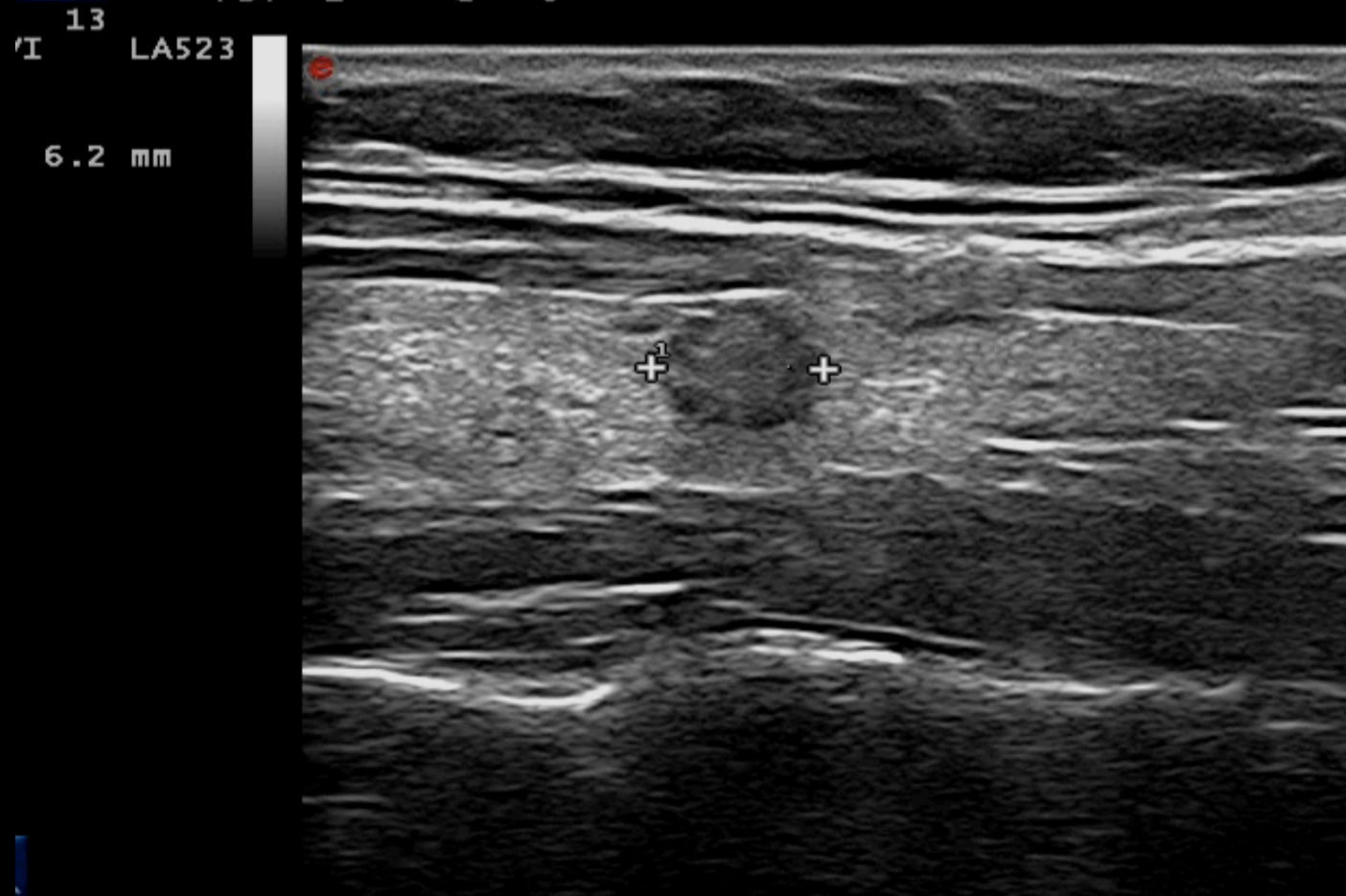


Caso Clinico 2 - Teresa



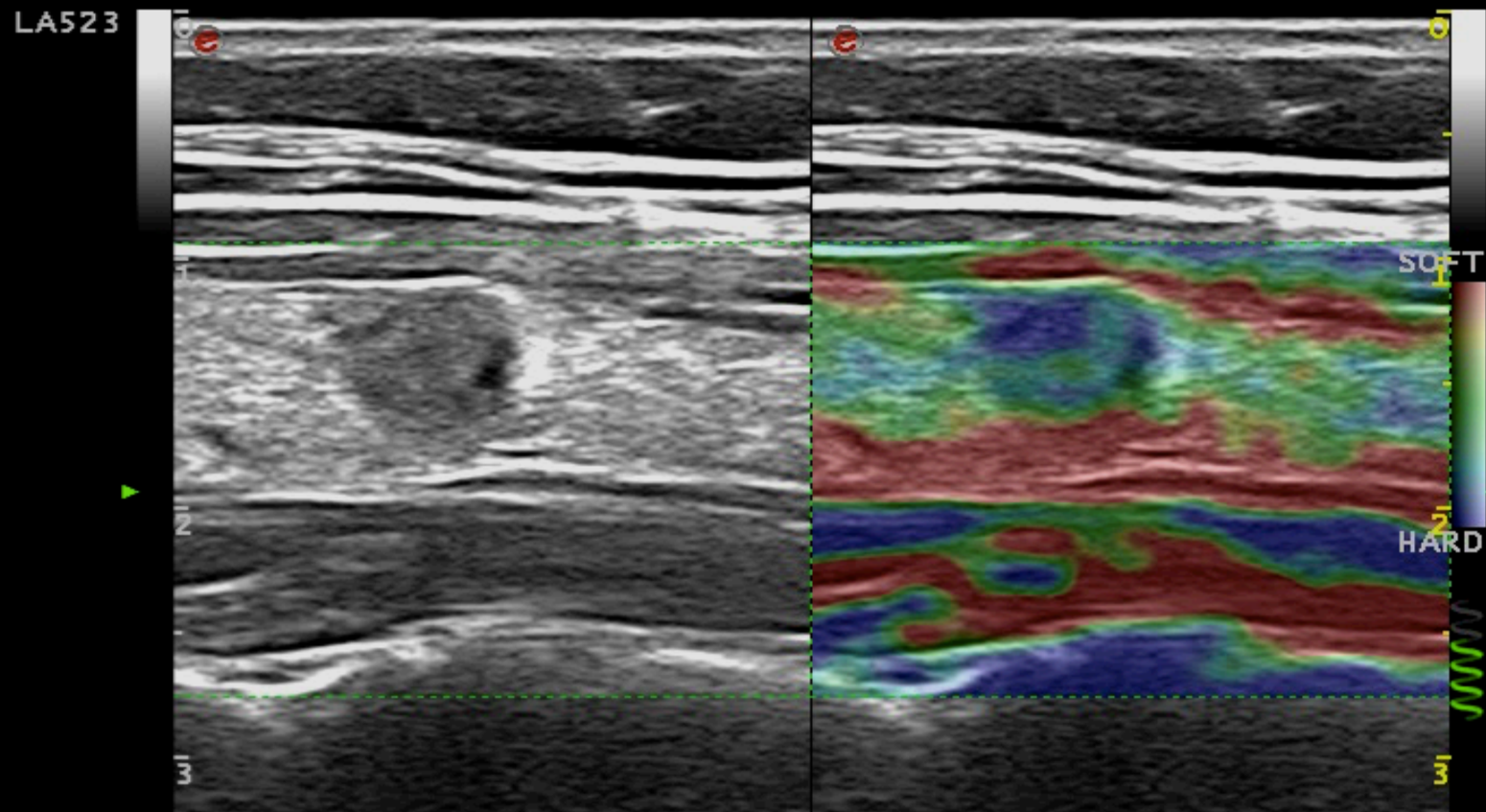


Caso Clinico 2 - Teresa





Caso Clinico 2 - Teresa





Roma, 8-11 novembre 2018

Teresa - Report ecografico



ITALIAN CHAPTER



- Tiroide nei limiti per ecostruttura e dimensioni
- Lobo tiroideo dx: nodulo solido marcatamente ipoecogeno 6.3 x 6.0 x 5.5 mm Ø localizzato nella porzione più laterale del lobo. Margini modicamente irregolari. Presenza di uno spot iperecogeno suggestivo per microcalcificazione. Vascolarizzazione intra- e perinodulare scarsa/ assente
- Pattern elastosonografico indicativo di ridotta elasticità del tessuto nodulare rispetto al parenchima circostante
- Lobo tiroideo sx indenne da noduli
- Non linfoadenomegalie sospette in sede cervicale



Roma, 8-11 novembre 2018

Come classificare il nodulo di Teresa?



ITALIAN CHAPTER



- **Probabilmente benigno**
- **Dubbio**
- **Sospetto/Maligno**



Roma, 8-11 novembre 2018

FNA o wait and see?



ITALIAN CHAPTER



Sottoporreste Teresa a FNA?

- Si
- No



Roma, 8-11 novembre 2018

LG Italiane 2018 per il carcinoma differenziato tiroideo



ITALIAN CHAPTER



Rischio ecografico e indicazioni a FNA *Cosimo Durante*



Roma, 8-11 novembre 2018

Definizione ecografica del rischio di malignità e indicazioni alla FNA



ITALIAN CHAPTER



Journal of Endocrinological Investigation (2018) 41:849–876

<https://doi.org/10.1007/s40618-018-0884-2>

ORIGINAL ARTICLE



CrossMark

Italian consensus on diagnosis and treatment of differentiated thyroid cancer: joint statements of six Italian societies

F. Pacini¹ · F. Basolo² · R. Bellantone³ · G. Boni⁴ · M. A. Cannizzaro⁵ · M. De Palma⁶ · C. Durante⁷ · R. Elisei⁸ · G. Fadda⁹ · A. Frasoldati¹⁰ · L. Fugazzola^{11,12} · R. Guglielmi¹³ · C. P. Lombardi³ · P. Miccoli² · E. Papini¹³ · G. Pellegriti¹⁴ · L. Pezzullo¹⁵ · A. Pontecorvi¹⁶ · M. Salvatori¹⁷ · E. Seregini¹⁸ · P. Vitti⁸

* Italian Thyroid Association (**AIT**), Medical Endocrinology Association (**AME**), Italian Society of Endocrinology (**SIE**), Italian Association of Nuclear Medicine and Molecular Imaging (**AIMN**), Italian Society of Unified Endocrine Surgery (**SIUEC**), Italian Society of Anatomic Pathology and Diagnostic Cytology (**SIAPEC**)



Definizione ecografica del rischio di malignità e indicazioni alla FNA



ITEM 1: Selection of thyroid nodules to be submitted to cytological evaluation

Class 1. Low-risk

[ROM: $\leq 1\%$]

- Purely cystic nodules.
- Mostly cystic (> 80%) nodules with reverberating artifacts.
- Spongiform, isoechoic or hyperechoic nodules not associated with suspicious US findings.

Class 2. Intermediate-risk

[ROM: 5-15%]

- Slightly hypo- or isoechoic nodules, ovoid-to-round shape, smooth or ill-defined margins.
- May be present:
 - ✓ intranodular vascularization
 - ✓ macro- or continuous rim calcifications
 - ✓ increased stiffness (elastography)
 - ✓ hyperechoic spots of uncertain significance

Class 3. High-risk

[ROM: 50-90%]

Nodules with at least one of the suspicious findings:

- marked hypoechogenicity
- spiculated or microlobulated margins
- micro-calcifications
- taller-than-wide shape
- extrathyroidal growth or lymphadenopathy



Definizione ecografica del rischio di malignità e indicazioni alla FNA



ITEM 1: Selection of thyroid nodules to be submitted to cytological evaluation

Class 1. Low-risk

[ROM: $\leq 1\%$]

FNA for nodules ≥ 20 mm in diameter **only when**

- symptomatic
- increasing in size
- associated with high-risk factors
- before surgery or local percutaneous therapy

Class 2. Intermediate-risk

[ROM: 5-15%]

FNA for nodules ≥ 20 mm in diameter

Class 3. High-risk

[ROM: 50-90%]

Diameter ≥ 10 mm: FNA is recommended



Definizione ecografica del rischio di malignità e indicazioni alla FNA



ITEM 1: Selection of thyroid nodules to be submitted to cytological evaluation

Class 1. Low-risk

[ROM: $\leq 1\%$]

FNA for nodules ≥ 20 mm in diameter **only when**

- symptomatic
- increasing in size
- associated with high-risk factors
- before surgery or local percutaneous therapy

Class 2. Intermediate-risk

[ROM: 5-15%]

FNA for nodules ≥ 20 mm in diameter

Class 3. High-risk

[ROM: 50-90%]

Diameter 5–9 mm: FNA or US monitoring on the basis of clinical setting and patient preference. FNA is recommended for subcapsular, posterior or paratracheal lesions, suspicious lymph nodes, extrathyroid spread, clinical thyroid cancer risk factors.



Roma, 8-11 novembre 2018

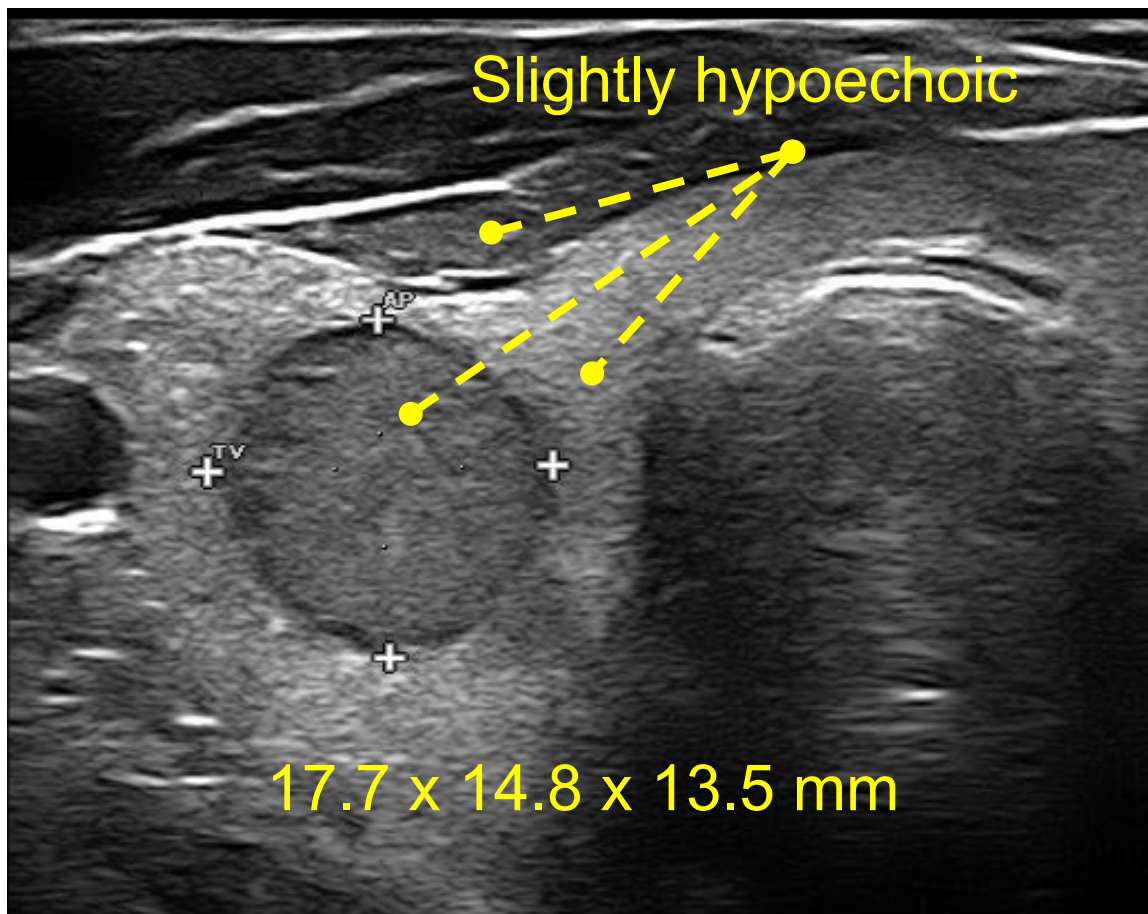
Definizione ecografica del rischio di malignità e indicazioni alla FNA



ITALIAN CHAPTER



Caso clinico 1 - Giulia



Steps

1. Look at the echogenicity
Slightly hypoechoic



Roma, 8-11 novembre 2018

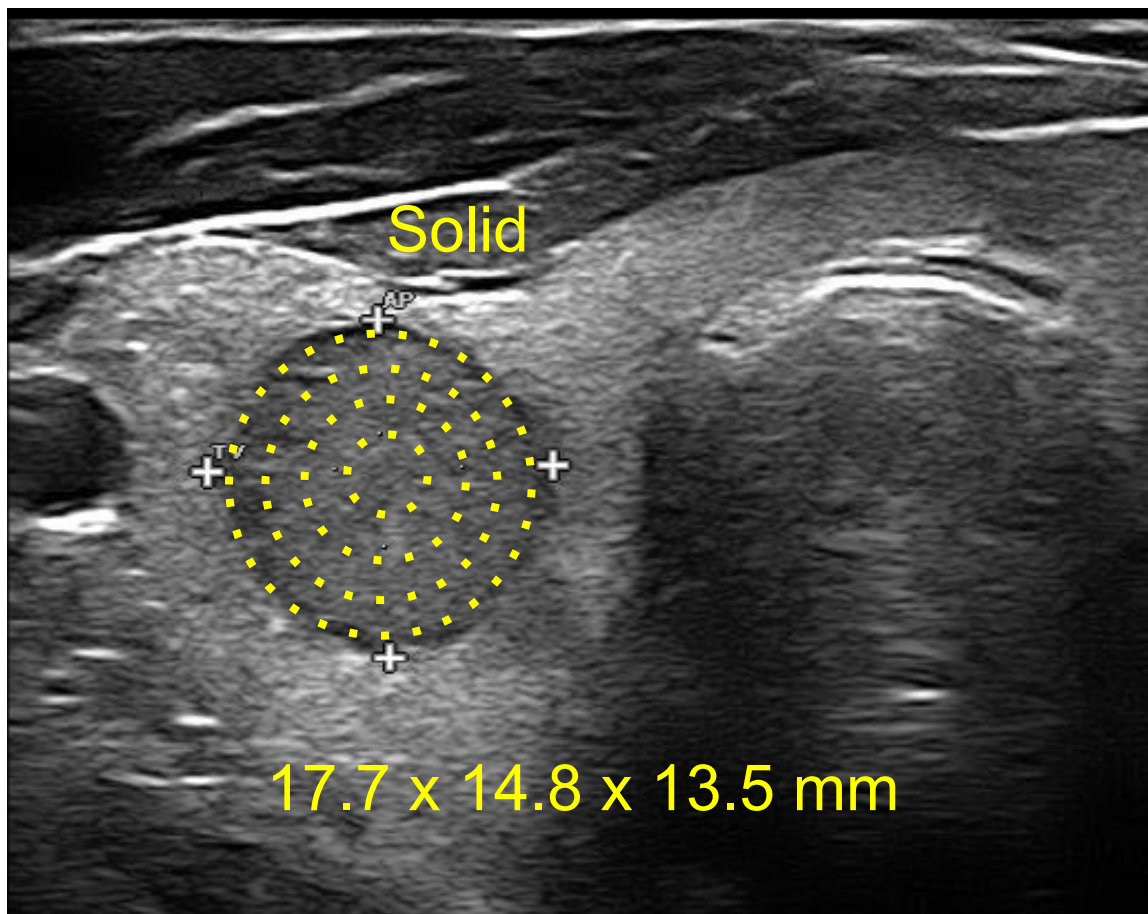
Definizione ecografica del rischio di malignità e indicazioni alla FNA



ITALIAN CHAPTER



Caso clinico 1 - Giulia



Steps

1. Look at the echogenicity
Slightly hypoechoic
2. Look at the echotexture
Solid



Roma, 8-11 novembre 2018

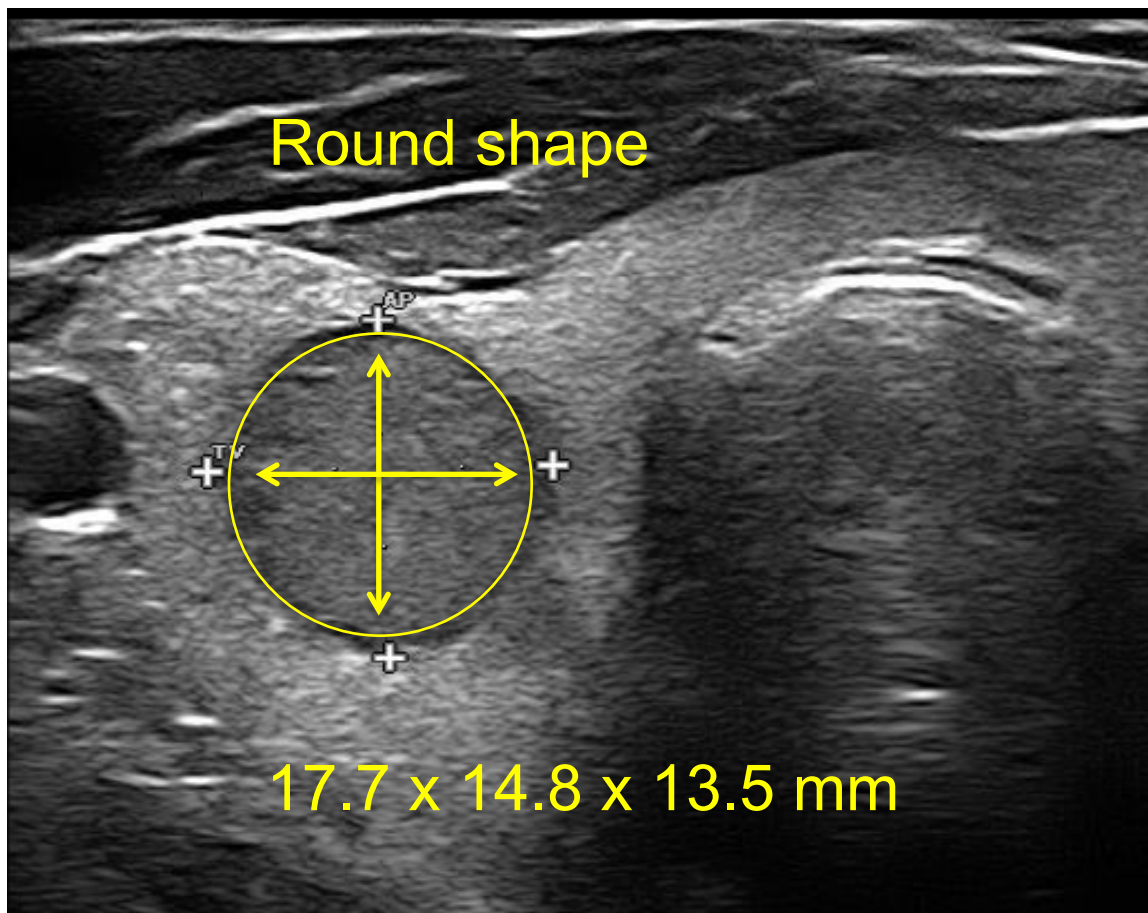
Definizione ecografica del rischio di malignità e indicazioni alla FNA



ITALIAN CHAPTER



Caso clinico 1 - Giulia



Steps

1. Look at the echogenicity
Slightly hypoechoic
2. Look at the echotexture
Solid
3. Look at the shape
Round



Roma, 8-11 novembre 2018

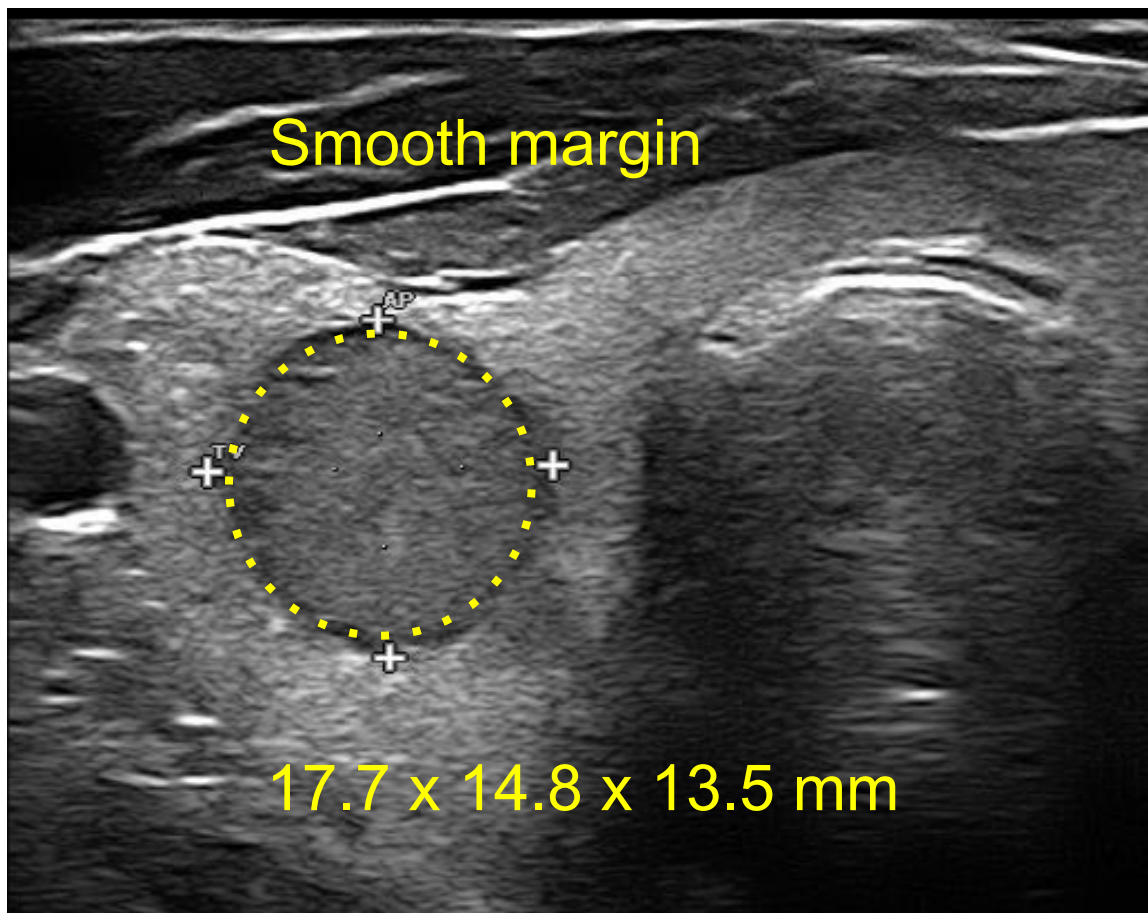
Definizione ecografica del rischio di malignità e indicazioni alla FNA



ITALIAN CHAPTER



Caso clinico 1 - Giulia



Steps

1. Look at the echogenicity
Slightly hypoechoic
2. Look at the echotexture
Solid
3. Look at the shape
Round
4. Look at the margins
Smooth



Roma, 8-11 novembre 2018

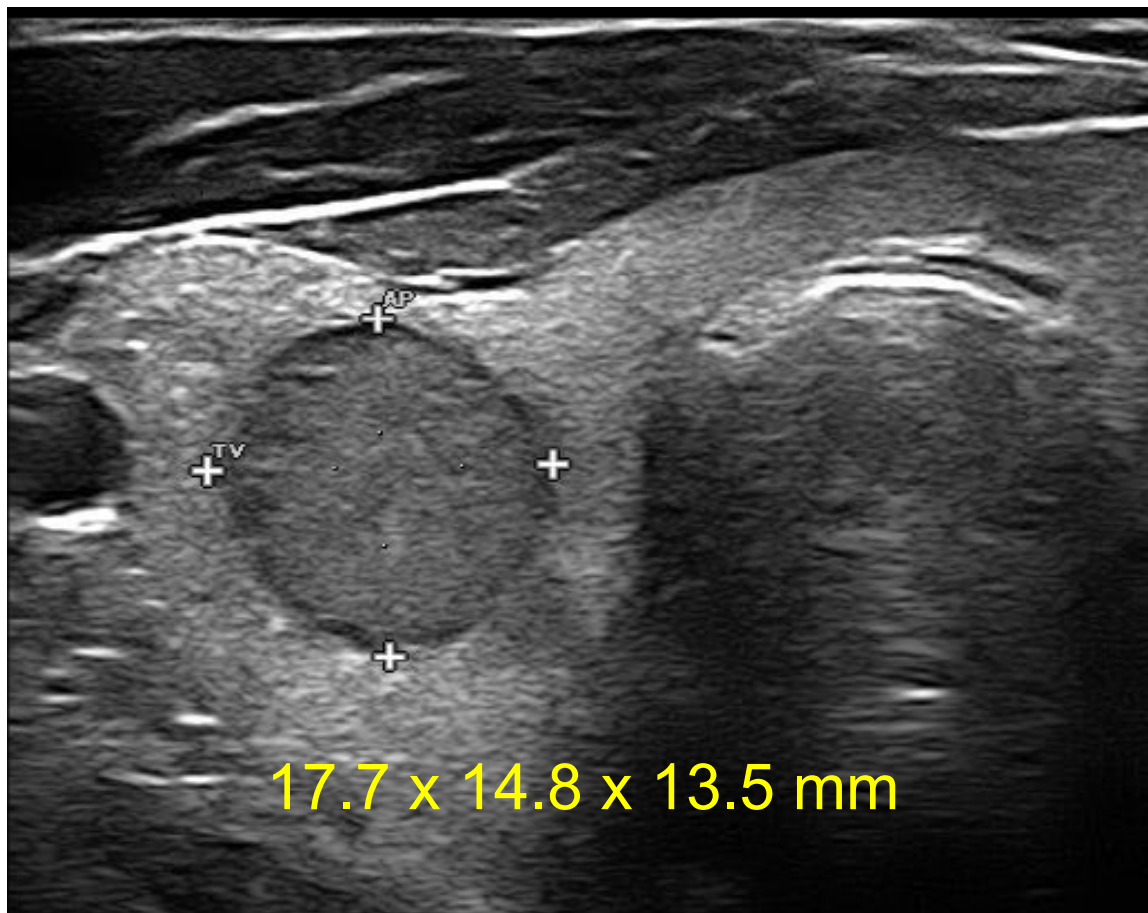
Definizione ecografica del rischio di malignità e indicazioni alla FNA



ITALIAN CHAPTER



Caso clinico 1 - Giulia



Steps

1. Look at the echogenicity
Slightly hypoechoic
2. Look at the echotexture
Solid
3. Look at the shape
Round
4. Look at the margins
Smooth
5. Look for suspicious findings
None



Roma, 8-11 novembre 2018

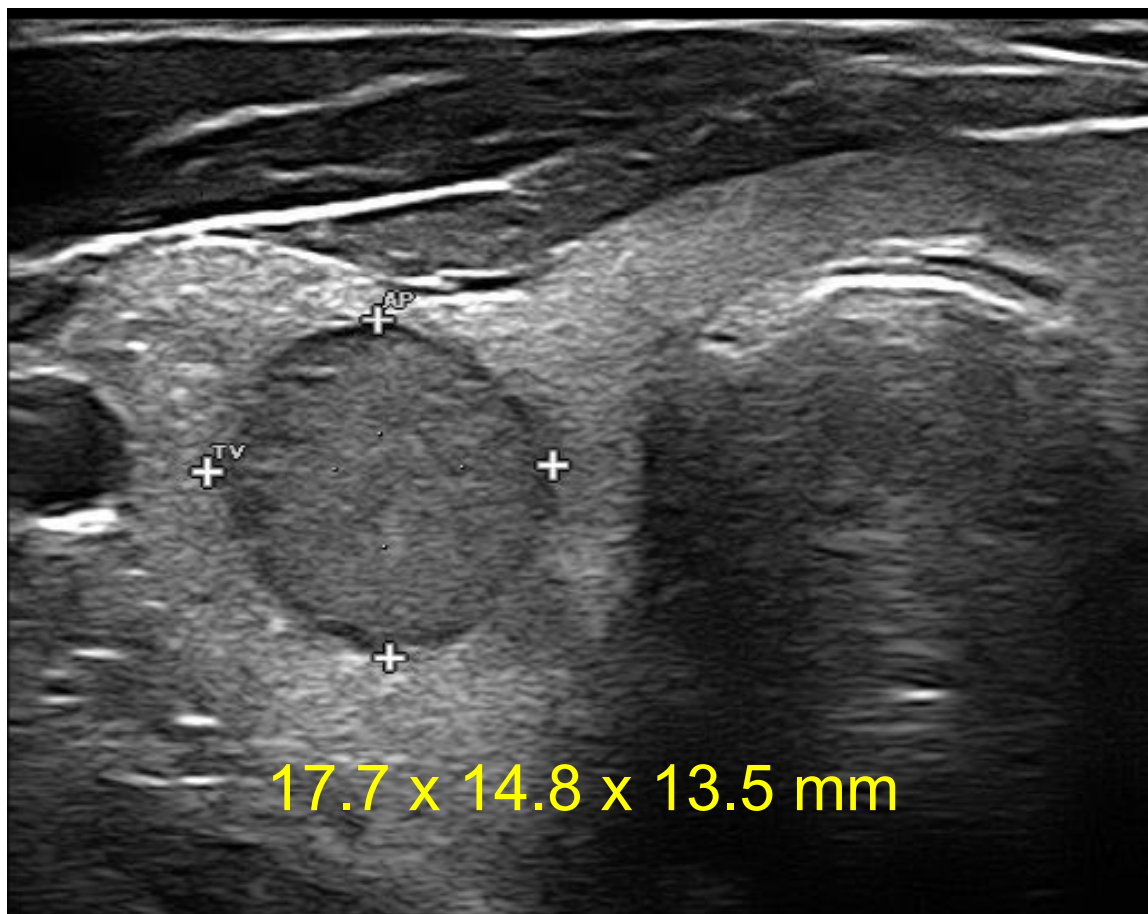
Definizione ecografica del rischio di malignità e indicazioni alla FNA



ITALIAN CHAPTER



Caso clinico 1 - Giulia



Risk of malignancy:

Class 2 - Intermediate-risk
[ROM: 5-15%]

FNA:

NO

[FNA for nodules ≥ 20 mm in diameter]



Roma, 8-11 novembre 2018

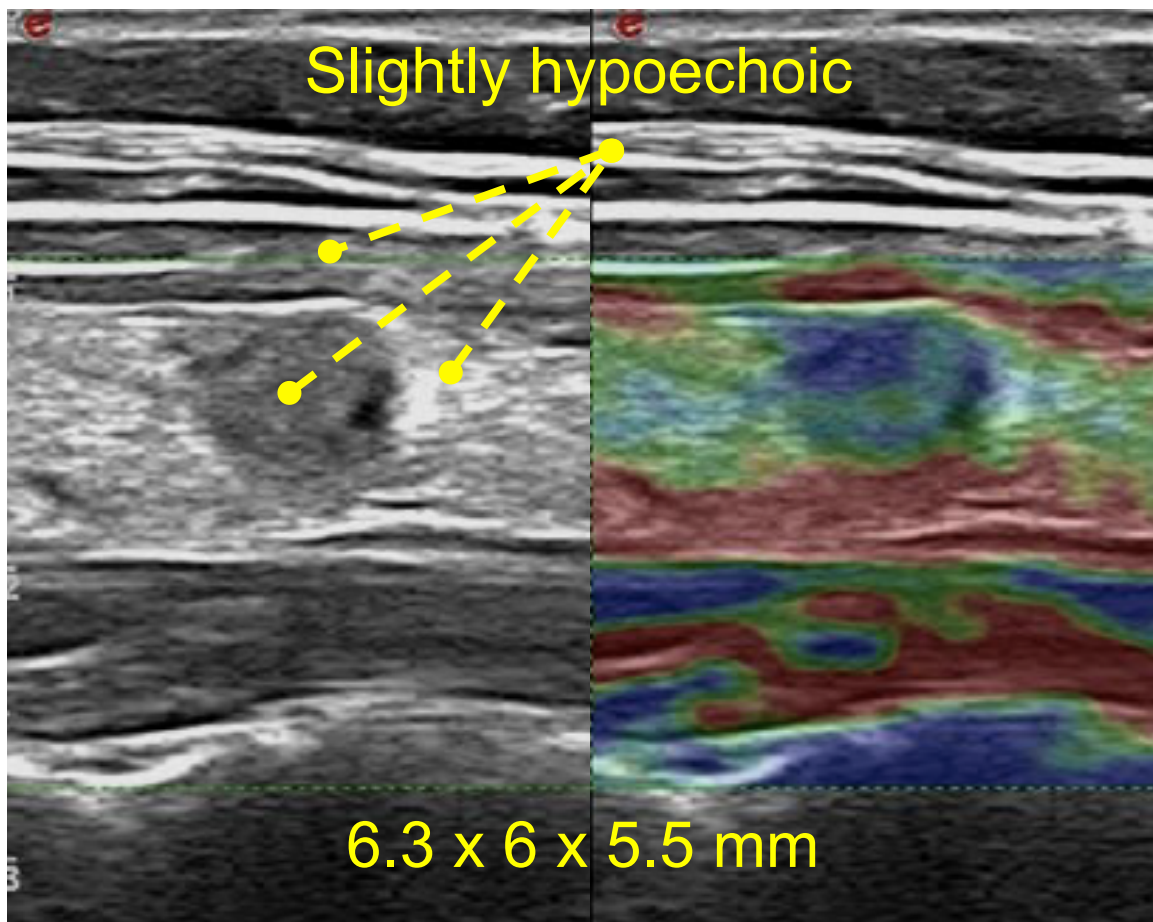
Definizione ecografica del rischio di malignità e indicazioni alla FNA



ITALIAN CHAPTER



Caso clinico 2 - Teresa



Steps

1. Look at the echogenicity
Slightly hypoechoic



Roma, 8-11 novembre 2018

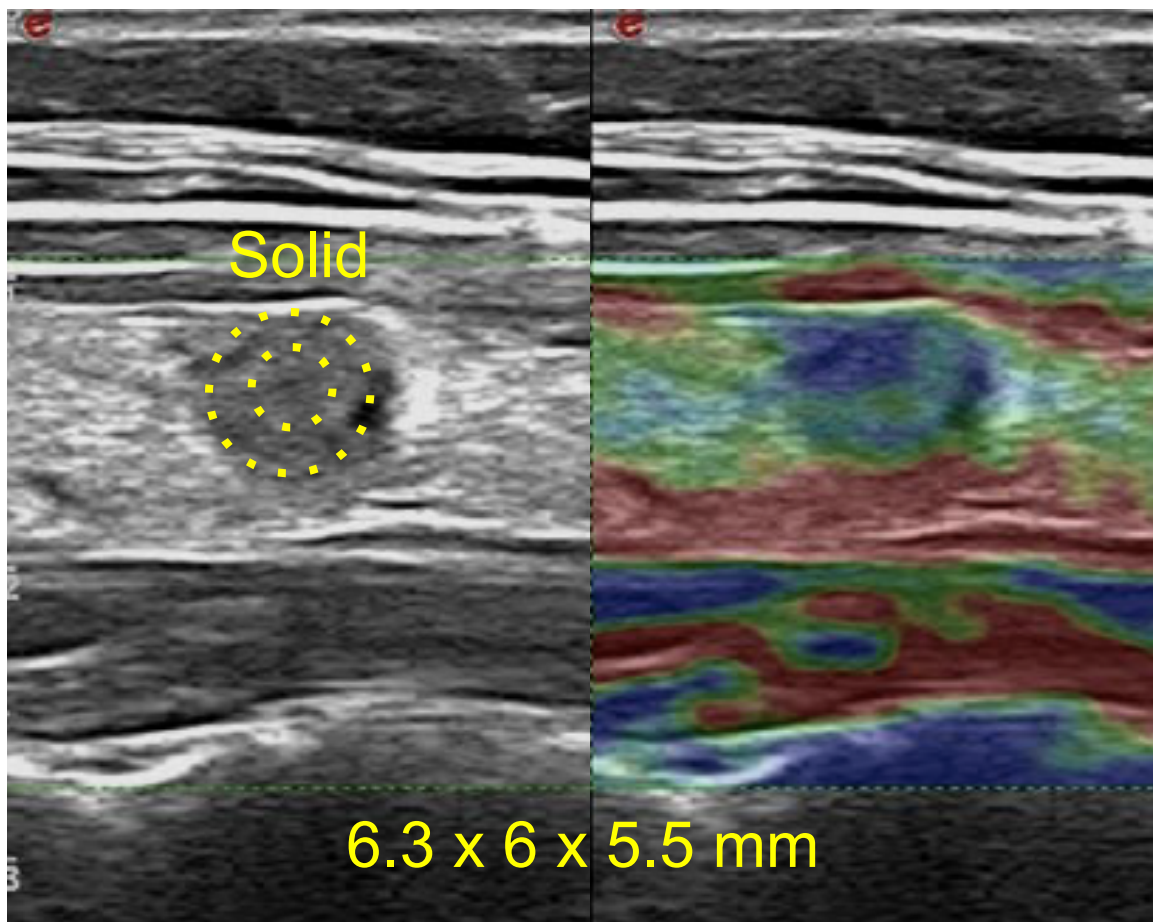
Definizione ecografica del rischio di malignità e indicazioni alla FNA



ITALIAN CHAPTER



Caso clinico 2 - Teresa



Steps

1. Look at the echogenicity
Slightly hypoechoic
2. Look at the echotexture
Solid



Roma, 8-11 novembre 2018

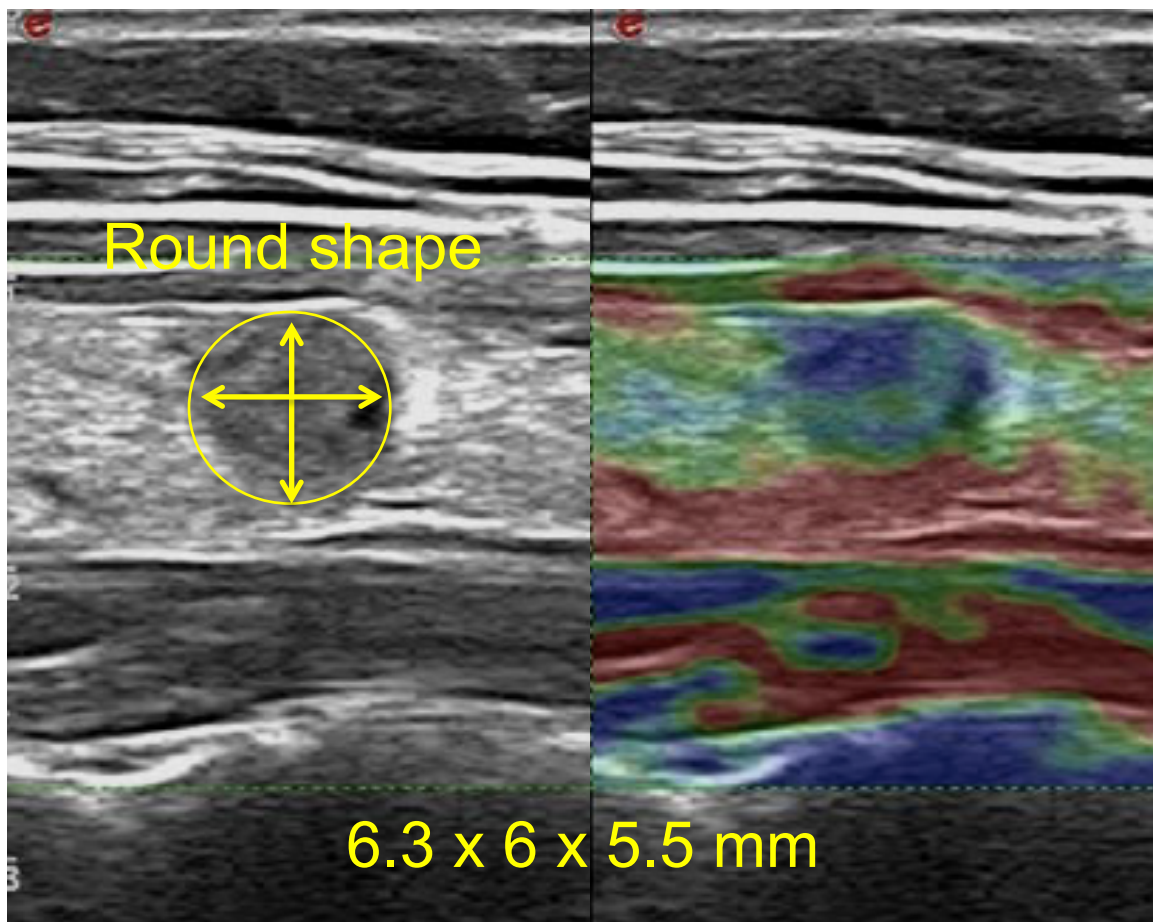
Definizione ecografica del rischio di malignità e indicazioni alla FNA



ITALIAN CHAPTER



Caso clinico 2 - Teresa



Steps

1. Look at the echogenicity
Slightly hypoechoic
2. Look at the echotexture
Solid
3. Look at the shape
Round



Roma, 8-11 novembre 2018

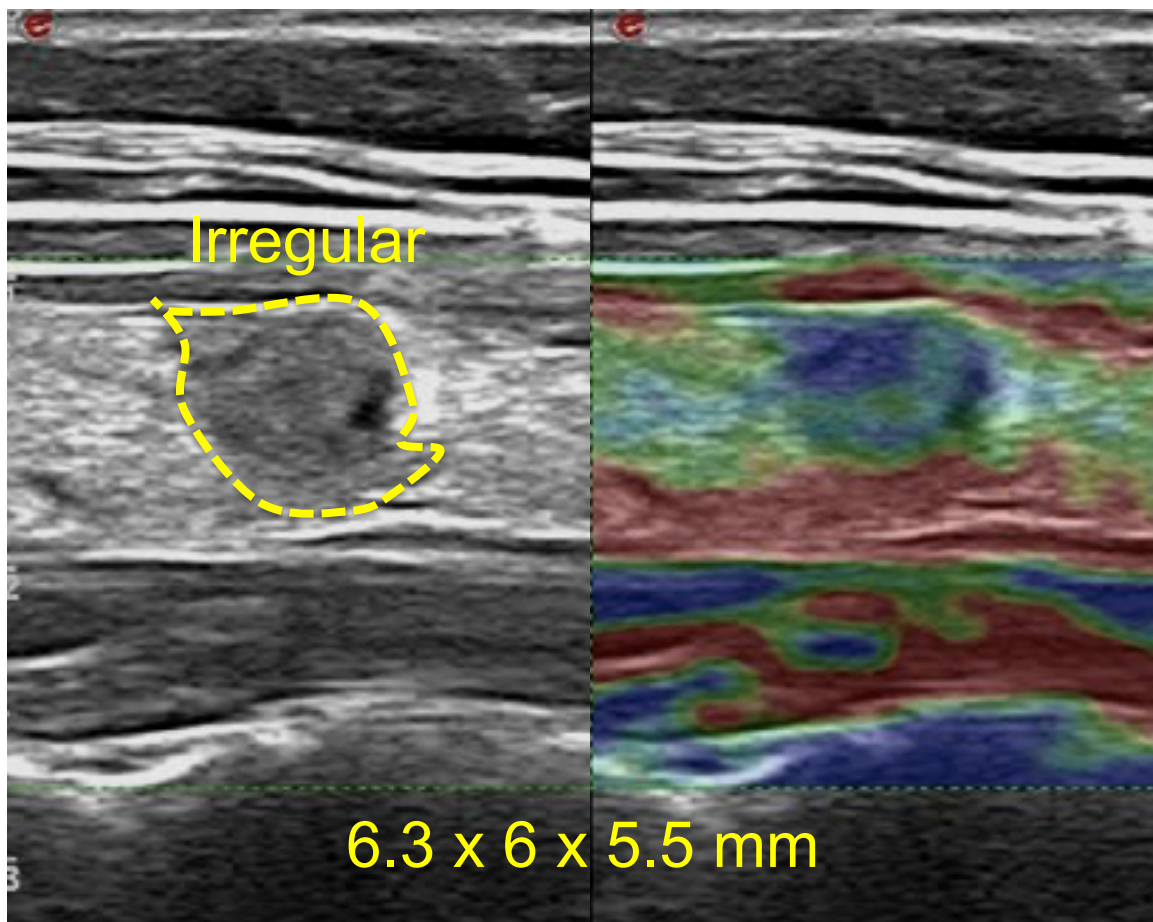
Definizione ecografica del rischio di malignità e indicazioni alla FNA



ITALIAN CHAPTER



Caso clinico 2 - Teresa



Steps

1. Look at the echogenicity
Slightly hypoechoic
2. Look at the echotexture
Solid
3. Look at the shape
Round
4. Look at the margins
Irregular



Roma, 8-11 novembre 2018

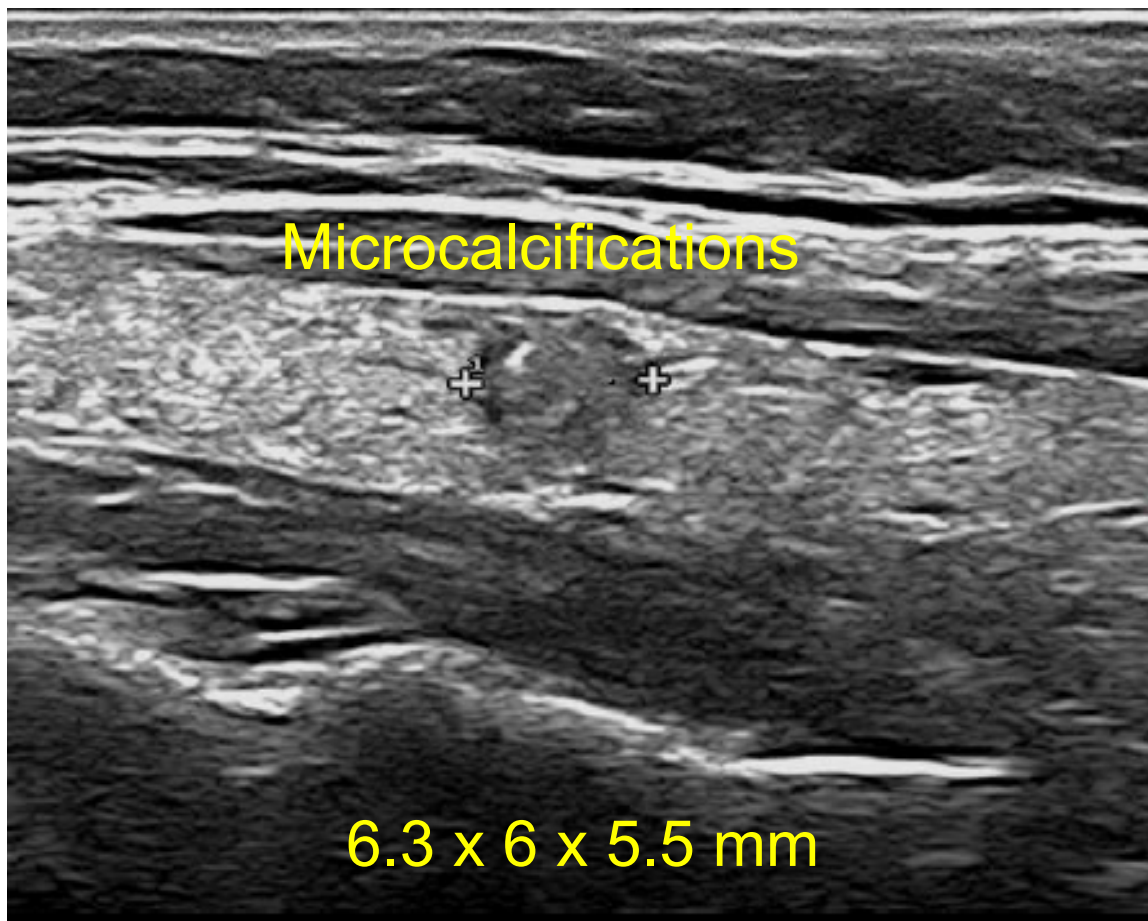
Definizione ecografica del rischio di malignità e indicazioni alla FNA



ITALIAN CHAPTER



Caso clinico 2 - Teresa



Steps

1. Look at the echogenicity
Slightly hypoechoic
2. Look at the echotexture
Solid
3. Look at the shape
Round
4. Look at the margins
Irregular
5. Look for suspicious findings
Microcalcifications



Roma, 8-11 novembre 2018

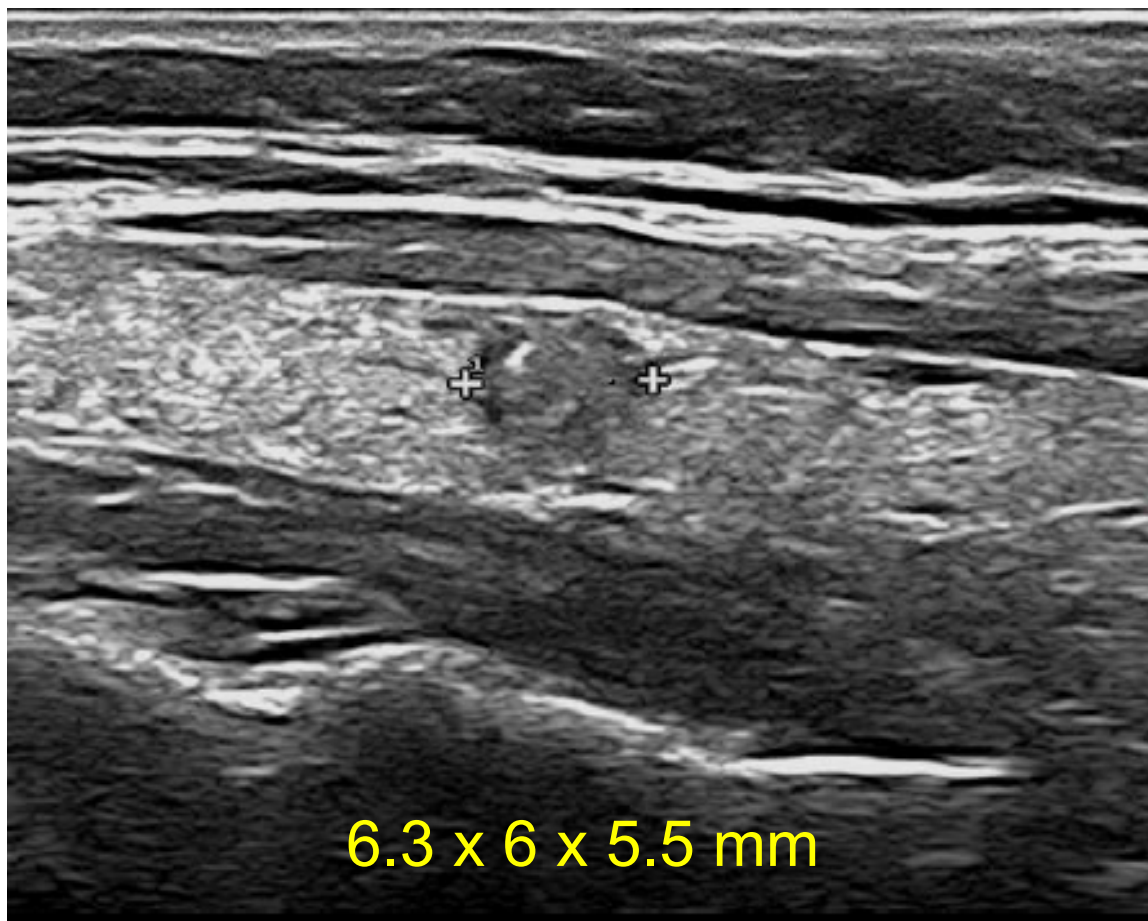
Definizione ecografica del rischio di malignità e indicazioni alla FNA



ITALIAN CHAPTER



Caso clinico 2 - Teresa



Risk of malignancy:

Class 3 – High

[ROM: 50-90%]

FNA:

FNA or US monitoring

[for nodules of 5-9 mm in diameter]



Roma, 8-11 novembre 2018

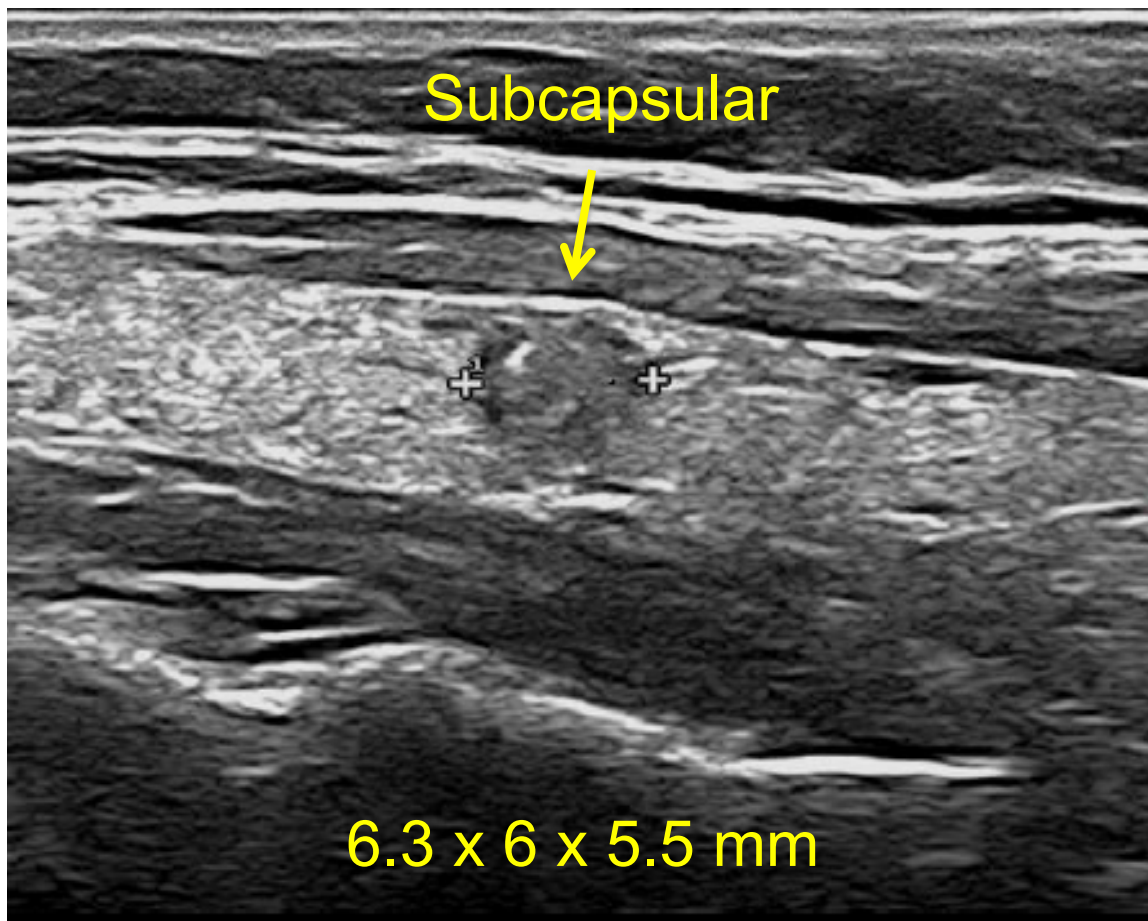
Definizione ecografica del rischio di malignità e indicazioni alla FNA



ITALIAN CHAPTER



Caso clinico 2 - Teresa



Risk of malignancy:

Class 3 – High

[ROM: 50-90%]

FNA:

FNA or US monitoring

[for nodules of 5-9 mm in diameter]

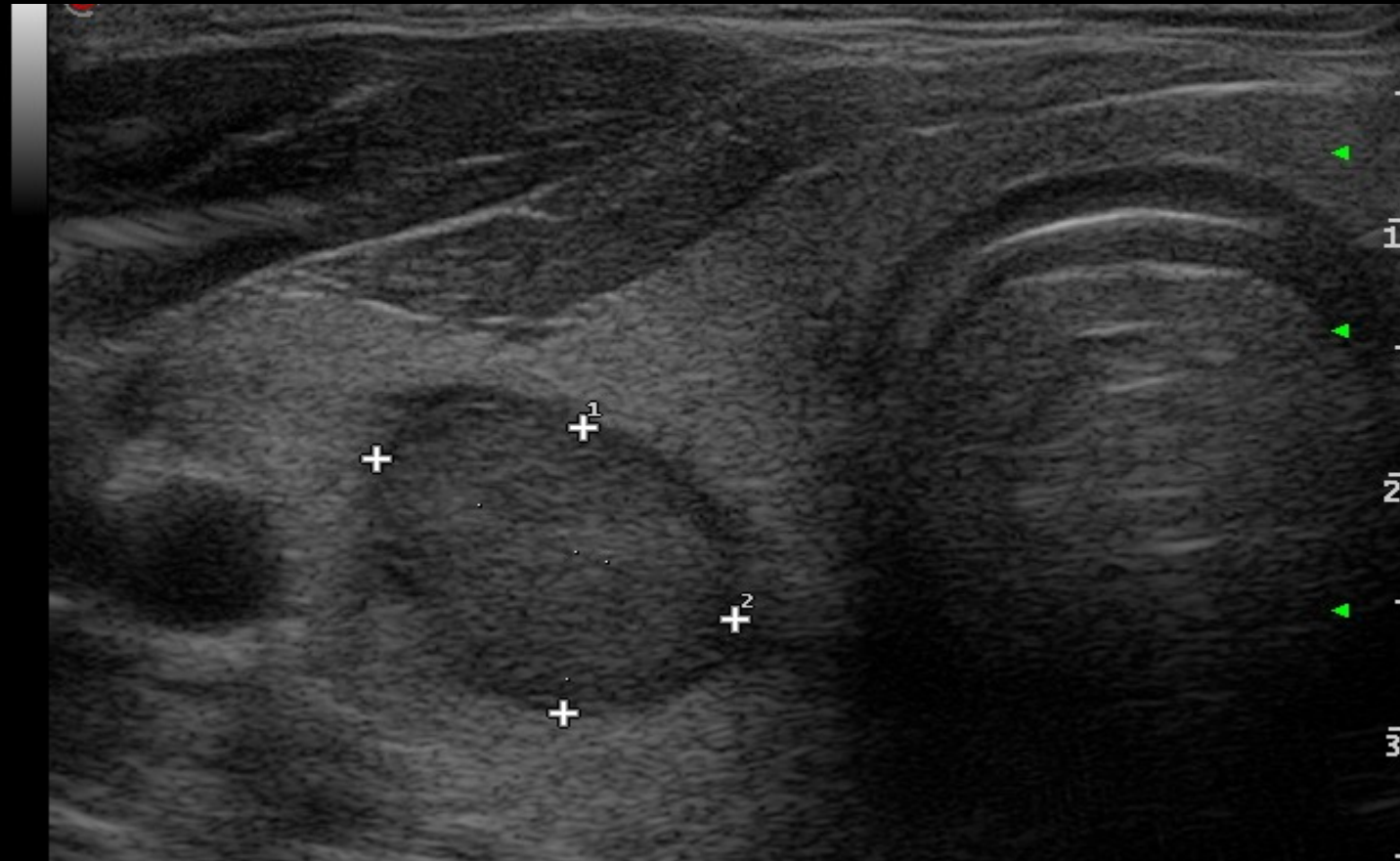


Caso Clinico 1 - Giulia



ITALIAN CHAPTER

D1 1.13 cm
D2 1.40 cm



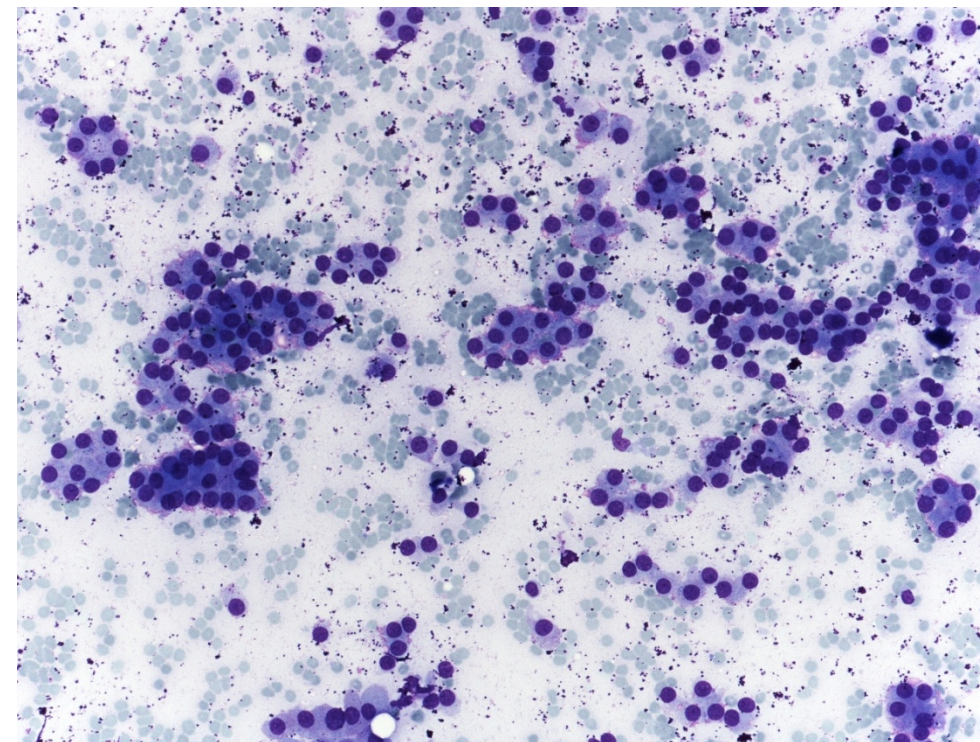
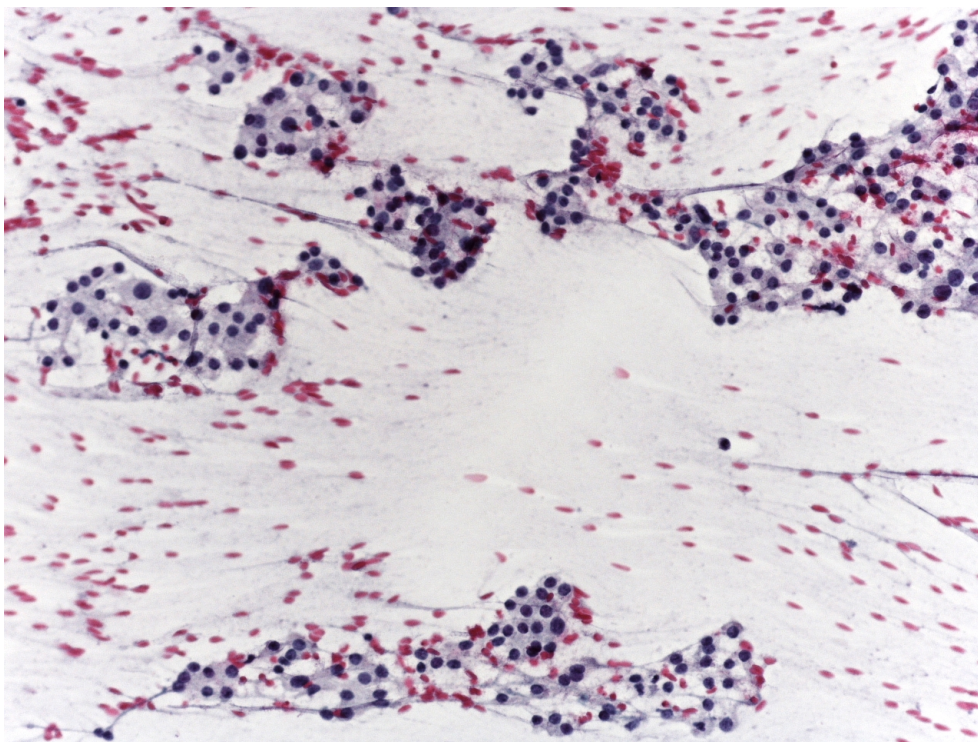


Giulia – Report Citologico



ITALIAN CHAPTER

Roma, 8-11 novembre 2018



Aggregati solidi e follicolari di tireociti con lieve anisocariosi. Colloide scarsa.

Quadro citologico di neoformazione follicolare, Tir3b SIAPEC; Thy3f secondo BTA, classe IV Bethesda



Roma, 8-11 novembre 2018

Chirurgia o “Wait and see” per Giulia?



ITALIAN CHAPTER



- **Chirurgia**
- **Ecografia di controllo a 6-12 mesi**



Roma, 8-11 novembre 2018

Quale chirurgia per Giulia?



ITALIAN CHAPTER



Quale indicazione chirurgica per Giulia?

- Lobectomia dx
- Tiroidectomia totale

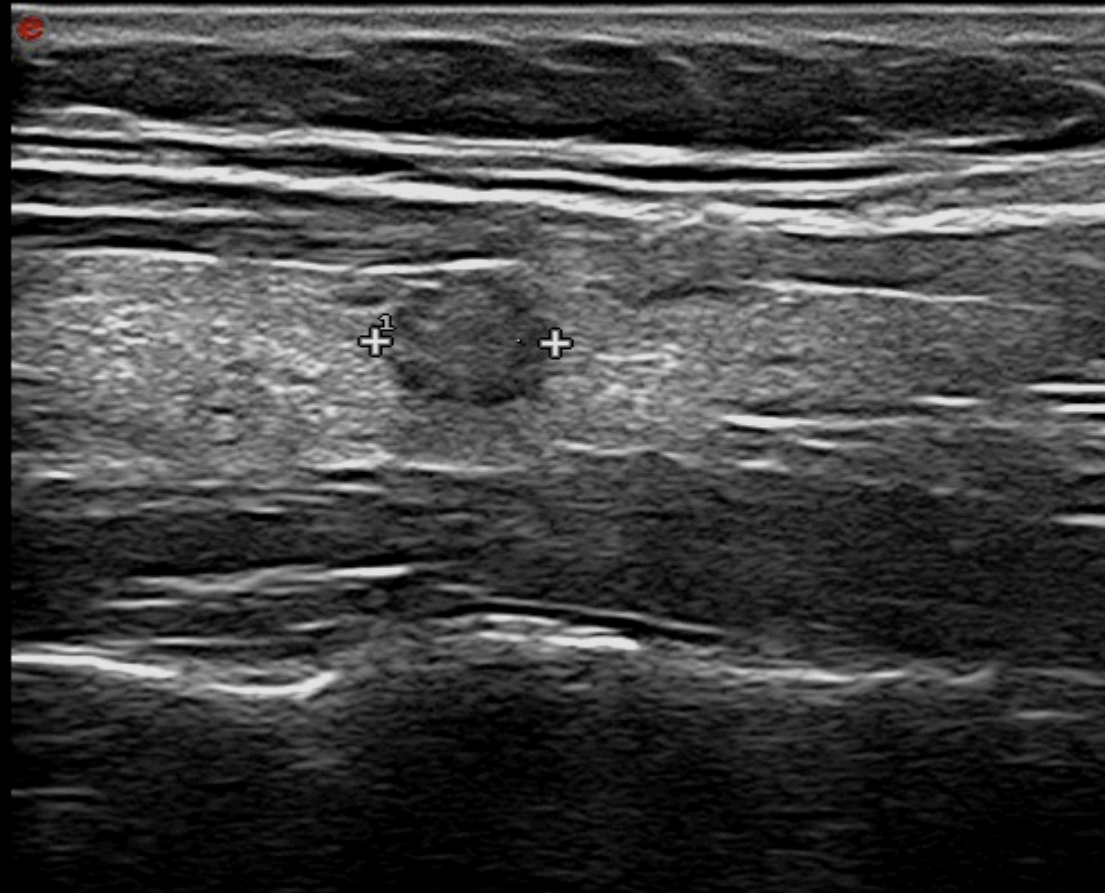


Caso Clinico 2 - Teresa



13
LA523

6.2 mm



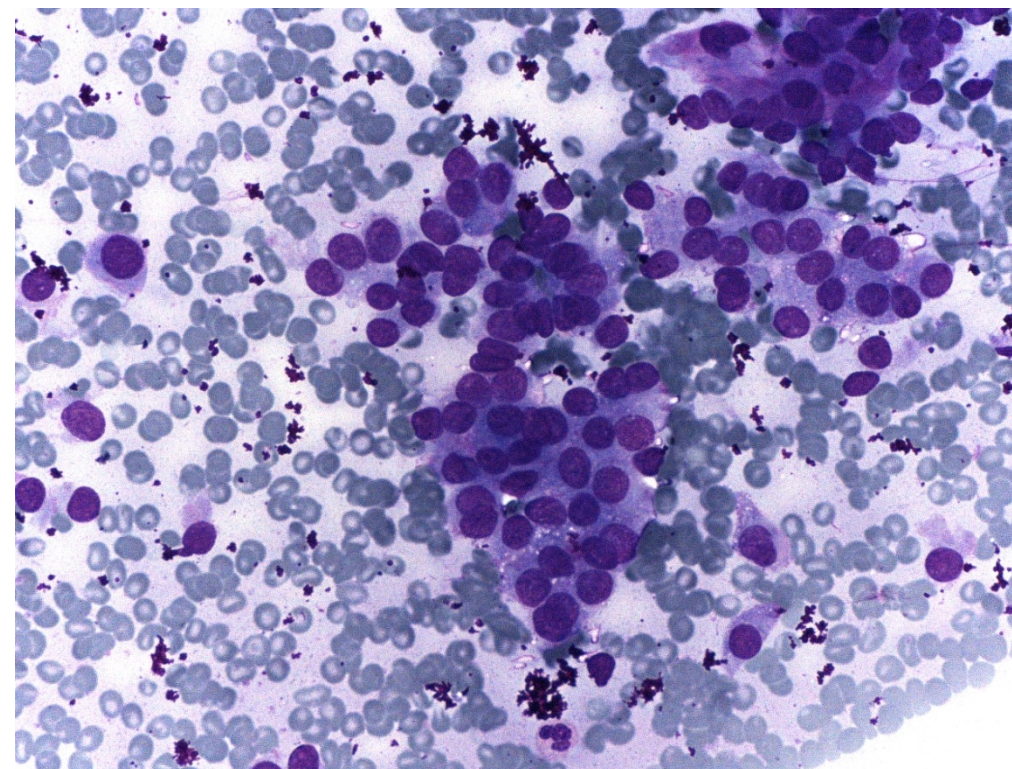
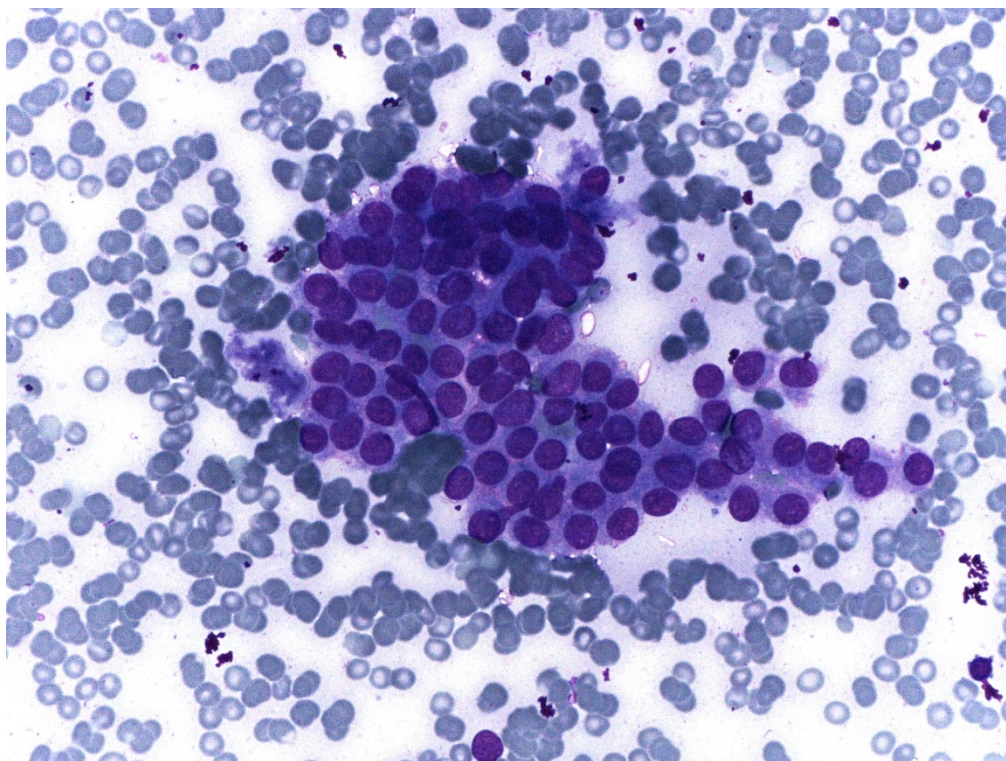


Roma, 8-11 novembre 2018

Teresa – Report citologico



ITALIAN CHAPTER



Materiale ematico, rara colloide in fiocchi,
ricca cellularità con tireociti talora dismetrici e con incisure nucleari:

Categoria diagnostica Tir 3b SIAPEC, Thy3a BTA, classe IV Bethesda



Roma, 8-11 novembre 2018


Biologia Molecolare



ITALIAN CHAPTER



- Su parte del materiale citologico viene eseguita ricerca della mutazione **BRAF V600E** con esito **positivo**



- Teresa viene informata del risultato, indicativo di carcinoma papillare.



Roma, 8-11 novembre 2018

“Sorveglianza attiva” per Teresa?



ITALIAN CHAPTER



Candidereste Teresa ad un protocollo di sorveglianza attiva?

- **Si**
- **No**



Roma, 8-11 novembre 2018

Quale chirurgia per Teresa?



ITALIAN CHAPTER



Quale indicazione chirurgica per Teresa?

- Lobectomia dx
- Tiroidectomia totale



Roma, 8-11 novembre 2018

LG Italiane 2018 per il carcinoma differenziato tiroideo



Il trattamento chirurgico *R. Bellantone*



Roma, 8-11 novembre 2018

17° Congresso Nazionale AME

Associazione Medici Endocrinologi

Joint Meeting with AACE Italian Chapter



ITALIAN CHAPTER



Le Linee Guida Italiane 2018 per il carcinoma differenziato tiroideo

Il trattamento chirurgico

Prof. Rocco Bellantone



Preside della Facoltà di Medicina e Chirurgia
Direttore del Governo Clinico
Università Cattolica del Sacro Cuore - Roma
Fondazione Policlinico Universitario "A. Gemelli" IRCCS





Roma, 8-11 novembre 2018

17° Congresso Nazionale AME

Associazione Medici Endocrinologi

Joint Meeting with AACE Italian Chapter



ITALIAN CHAPTER

Nessun conflitto di interesse

Prof. Rocco Bellantone



Roma, 8-11 novembre 2018

Linee guida italiane per il carcinoma differenziato della tiroide



ITALIAN CHAPTER



- 1. When thyroidectomy is indicated which strategy should be performed: total thyroidectomy or lobo-isthmectomy?**
- 2. No intervention for papillary thyroid microcarcinoma**
- 3. Indication for completion thyroidectomy after lobectomy**
- 4. The role of central and lateral compartment neck dissection in the management of differentiated thyroid carcinoma**



Roma, 8-11 novembre 2018

Linee guida italiane per il carcinoma differenziato della tiroide



ITALIAN CHAPTER



- 1. When thyroidectomy is indicated which strategy should be performed: total thyroidectomy or lobo-isthmectomy?**
2. No intervention for papillary thyroid microcarcinoma
3. Indication for completion thyroidectomy after lobectomy
4. The role of central and lateral compartment neck dissection in the management of differentiated thyroid carcinoma



Roma, 8-11 novembre 2018

When thyroidectomy is indicated which strategy should be performed: total thyroidectomy or lobo-isthmectomy?



ITALIAN CHAPTER



Total Thyroidectomy
("definitive surgical resolution")

Lobectomy

Surveillance
("it would not be too late to perform surgical treatment")



**Tailored
Surgery**

1. Definition of LOW RISK

2. Preoperative work up
Vs
Histologic diagnosis

(Histologic subtypes?, pT3?,
N1a?, multifocal disease?,
bilateral multifocal disease?)



Lobectomy vs Total Thyroidectomy



ITALIAN CHAPTER

Roma, 8-11 novembre 2018

Extent of Surgery for Papillary Thyroid Cancer Is Not Associated With Survival

An Analysis of 61,775 Patients

Mohamed Abdelgadir Adam, MD,* John Pura, MPH,† Lin Gu, MS,‡ Michaela A. Dinan, PhD,‡
Douglas S. Tyler, MD,* Shelby D. Reed, PhD,‡ Randall Scheri, MD,* Sanziana A. Roman, MD,*
and Julie A. Sosa, MD, MA*‡



Lobectomy Vs Total Thyroidectomy

=

Overall Survival

Disease free survival?

Disease specific overall survival?

Conclusions: Current guidelines suggest total thyroidectomy for PTC tumors > 1 cm. However, we did not observe a survival advantage associated with total thyroidectomy compared with lobectomy. These findings call into question whether tumor size should be an absolute indication for total thyroidectomy.

TABLE 1. Patient Demographic, Clinical, and Pathologic Characteristics by Extent of Surgery (1998–2006)

	Lobectomy (%) [N = 6,849]	Total Thyroidectomy (%) [N = 54,926]	P
Female	5,556 (81.1)	43,242 (78.7)	<0.01
Age			<0.01
<45 yr	3,498 (51.1)	29,044 (52.9)	
45–64 yr	2,500 (36.5)	20,183 (36.7)	
≥65 yr	851 (12.4)	5,699 (10.4)	
Race			<0.01
White	5,886 (87.6)	47,471 (88.2)	
Black	463 (6.9)	2,972 (5.5)	
Asian	270 (4.0)	2,599 (4.8)	
Other	97 (1.4)	786 (1.5)	
Annual income			<0.01
<\$35,000	1,880 (29.1)	12,594 (24.4)	
≥\$35,000	4,572 (70.9)	38,992 (75.6)	
Insurance status			NS
Not insured	196 (2.9)	1,384 (2.6)	
Insured	6,450 (97.1)	51,926 (97.4)	
Comorbidity*			NS
0	2,796 (88.4)	26,476 (89.3)	
1	311 (9.8)	2,764 (9.3)	
≥2	56 (1.8)	408 (1.4)	
Tumor size			NS
1.0–2.0 cm	4,092 (59.7)	32,541 (59.2)	
2.1–4.0 cm	2,757 (40.3)	22,385 (40.8)	
Multifocality†			<0.01
No	1,609 (71.5)	12,664 (56.2)	
Yes	642 (28.5)	9,879 (43.8)	
Extrathyroidal extension‡			<0.01
No	3,167 (94.7)	24,759 (84.5)	
Yes	177 (5.3)	4,545 (15.5)	
Nodal metastasis			<0.01
Absent‡	6,189 (90.4)	39,468 (71.9)	
Present	479 (7.2)	14,655 (27.1)	
Distant metastasis			<0.01
Absent	6,823 (99.6)	54,368 (99.0)	
Present	26 (0.4)	558 (1.0)	
Margin status			<0.01
Negative	1,413 (21.2)	14,191 (26.2)	
Positive	479 (7.2)	14,655 (27.1)	
RAI administered	2,165 (33.2)	33,756 (65.3)	<0.01
Annual hospital case volume, median (IQR)	8 (4–16)	12 (6–22)	<0.01



Lobectomy vs Total Thyroidectomy



ITALIAN CHAPTER

Roma, 8-11 novembre 2018

Thyroid Lobectomy for Papillary Thyroid Cancer: Long-term Follow-up Study of 1,088 Cases

Kenichi Matsuzu · Kiminori Sugino · Katsuhiko Masudo · Mitsuji Nagahama ·
Wataru Kitagawa · Hiroshi Shibuya · Keiko Ohkuwa · Takashi Uruno ·
Akifumi Suzuki · Syunsuke Magoshi · Junko Akaishi · Chie Masaki ·
Michikazu Kawano · Nobuyasu Sukanuma · Yasushi Rino · Munetaka Masuda ·
Kaori Kameyama · Hiroshi Takami · Koichi Ito



2014

Mean follow-up: 17.6 years

Lobectomy is a valid alternative to total thyroidectomy in selected cases:

- **Age <45 years**
- **Tumor size ≤ 40 mm**
- **No lymph node metastases**
- **No extrathyroidal invasion**



Roma, 8-11 novembre 2018

Lobectomy advantages



ITALIAN CHAPTER

VS Total Thyroidectomy

- **Reduced inferior laryngeal nerve injury (- 50%)**
- **No hypoparathyroidism**
- **Decreased operative time**
- **Decreased operating costs**
- **LT4 supplement (no substitutive LT4)**
- **Residual thyroid function**



Roma, 8-11 novembre 2018

Complications



ITALIAN CHAPTER

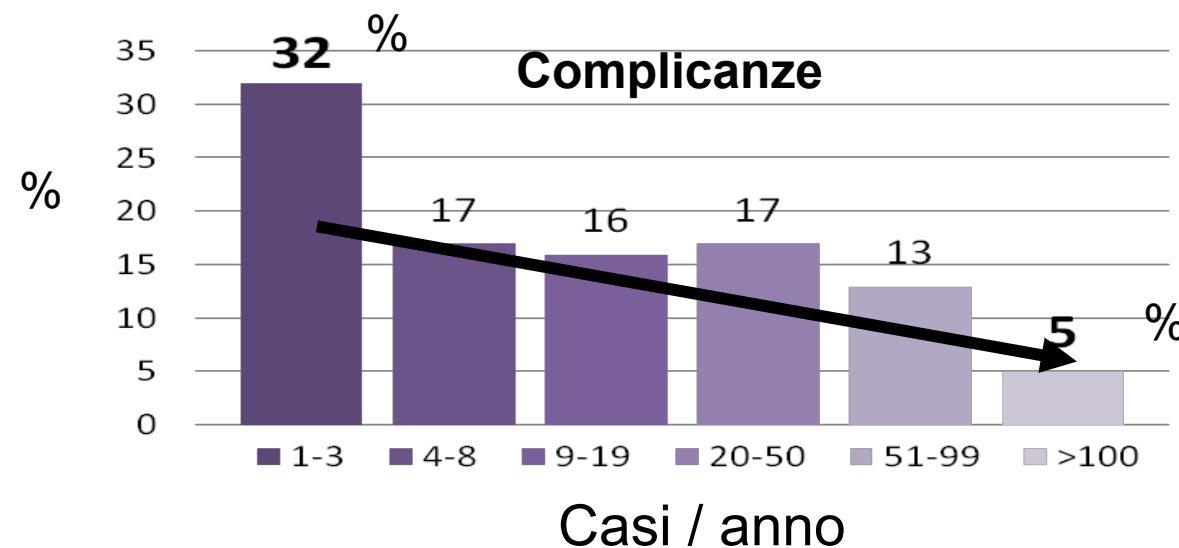
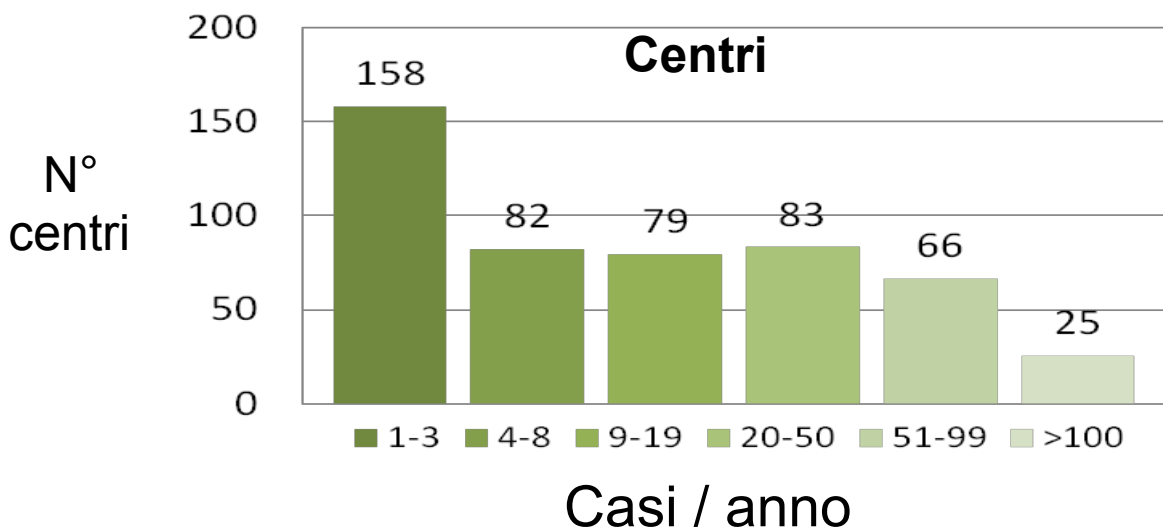


Surgeon volume as a predictor of outcomes in inpatient and outpatient endocrine surgery

13997 pazienti NY-FL 2002



Alexandra I. Stavrakis, BS,^a Philip H.G. Ituarte, PhD, MPH,^a Clifford Y. Ko, MD, MS, MSHS, FACS,^{a,b} and Michael W. Yeh, MD,^a Los Angeles, Calif



Minori complicanze riportate da chirurghi con **volume >100** interventi annui



Roma, 8-11 novembre 2018

Complications



ITALIAN CHAPTER



REQUISITI PER L'ACCREDITAMENTO

- **Volume minimo di attività assunto: >50 interventi/anno**. Indicatori di qualità per un Centro di Riferimento I parametri, relativamente alle principali sequele o complicanze post-tiroidectomia totale, si possono attualmente così riassumere, assumendo come base quelli pubblicati dal Club delle UEC5 e come range i dati della letteratura internazionale:
 - Lesione ricorrente permanente monolaterale 1.3% (range 0.4-4.6 %)
 - Ipoparatiroidismo definitivo 2.2% (range 0.2-7.2 %)
 - Sanguinamento post-operatorio 1.6% (range 0.5-4.0 %)
 - Infezione ferita 0.4%



Linee guida italiane per il carcinoma differenziato della tiroide



ITALIAN CHAPTER

Roma, 8-11 novembre 2018

1. When thyroidectomy is indicated which strategy should be performed: total thyroidectomy or lobo-isthmectomy?

- a) **Thyroid lobo-isthmectomy** alone is an adequate initial surgical treatment for patients with suspicious cancer ≤ 1 cm, clinically limited to one lobe, with no evidence of extrathyroidal extension or metastatic disease to nodes (cN0b) or prior head and neck irradiation.
- b) **Total thyroidectomy** is recommended with at least one of the following parameters: patients with differentiated thyroid carcinoma >4 cm, unilateral or multifocal disease, with at least one of the following: clinically (or intraoperative) detected cervical nodal metastases, gross extrathyroidal extension or metastatic disease to distant sites.
- c) **Lobo-isthmectomy or total thyroidectomy** may be proposed to patients with differentiated thyroid carcinoma >1 and <4 cm without clinical (or intraoperative) evidence of extrathyroidal extension and lymph node metastases (N0b). Total thyroidectomy may be preferred to enable radioiodine treatment and to enhance follow-up accuracy, or for preference of the patient.



Linee guida italiane per il carcinoma differenziato della tiroide



ITALIAN CHAPTER

Roma, 8-11 novembre 2018

1. When thyroidectomy is indicated which strategy should be performed: total thyroidectomy or lobo-isthmectomy?

a) Thyroid lobo-isthmectomy alone is an adequate initial surgical treatment for patients with suspicious cancer ≤ 1 cm, clinically limited to one lobe, with no evidence of extrathyroidal extension or metastatic disease to nodes (cN0b) or prior head and neck irradiation.



Roma, 8-11 novembre 2018

Linee guida italiane per il carcinoma differenziato della tiroide



ITALIAN CHAPTER



1. When thyroidectomy is indicated which strategy should be performed: total thyroidectomy or lobo-isthmectomy?

b) Total thyroidectomy is recommended with at least one of the following parameters: patients with differentiated thyroid carcinoma >4 cm, unilateral or multifocal disease, with at least one of the following: clinically (or intraoperative) detected cervical nodal metastases, gross extrathyroidal extension or metastatic disease to distant sites.



Linee guida italiane per il carcinoma differenziato della tiroide



ITALIAN CHAPTER

Roma, 8-11 novembre 2018

1. When thyroidectomy is indicated which strategy should be performed: total thyroidectomy or lobo-isthmectomy?

c) Lobo-isthmectomy or total thyroidectomy may be proposed to patients with differentiated thyroid carcinoma >1 and <4 cm without clinical (or intraoperative) evidence of extrathyroidal extension and lymph node metastases (N0b). Total thyroidectomy may be preferred to enable radioiodine treatment and to enhance follow-up accuracy, or for preference of the patient.



Roma, 8-11 novembre 2018

Linee guida italiane per il carcinoma differenziato della tiroide



ITALIAN CHAPTER



1. When thyroidectomy is indicated which strategy should be performed: total thyroidectomy or lobo-isthmectomy?
- 2. No intervention for papillary thyroid microcarcinoma**
3. Indication for completion thyroidectomy after lobectomy
4. The role of central and lateral compartment neck dissection in the management of differentiated thyroid carcinoma



Linee guida italiane per il carcinoma differenziato della tiroide



ITALIAN CHAPTER

Roma, 8-11 novembre 2018

2. No intervention for papillary thyroid microcarcinoma (PTMC)

- a) Even **if surgery is the treatment of choice**, “no immediate intervention” and **active surveillance** may be considered for very low-risk PTMC in the following setting:
1. patients at high surgical risk;
 2. patients who refuse surgical treatment;
 3. patients willing to enter into controlled clinical trials.
- b) A **personal decision making** is recommended as well as an accurate discussion with the patient to explain pro and cons of the active surveillance vs. surgical treatment.
- c) A **careful clinical and cytological evaluation** of risk factors for aggressive behaviour or recurrence of PTMC is recommended. A repeated “neck” sonographic evaluation after cytological suspicion of PTMC should be the first step to be carried out to exclude the presence of suspicious lymph nodes.



Roma, 8-11 novembre 2018

Linee guida italiane per il carcinoma differenziato della tiroide



ITALIAN CHAPTER



2. No intervention for papillary thyroid microcarcinoma (PTMC)

Risk factors for aggressive behavior and recurrence of PTMC

Previous neck irradiation

Extra-thyroidal extension at US

Subcapsular or posterior localization of PTMC

Multifocal or bilateral tumor

Coexistence of Graves' disease

Suspicious lymph node involvement

Aggressive cytological features and BRAF mutation (if available).



Papillary Thyroid Microcarcinoma



ITALIAN CHAPTER

Roma, 8-11 novembre 2018

Papillary Thyroid Microcarcinoma: Extrathyroidal Extension, Lymph Node Metastases, and Risk Factors for Recurrence in a High Prevalence of Goiter Area



2010

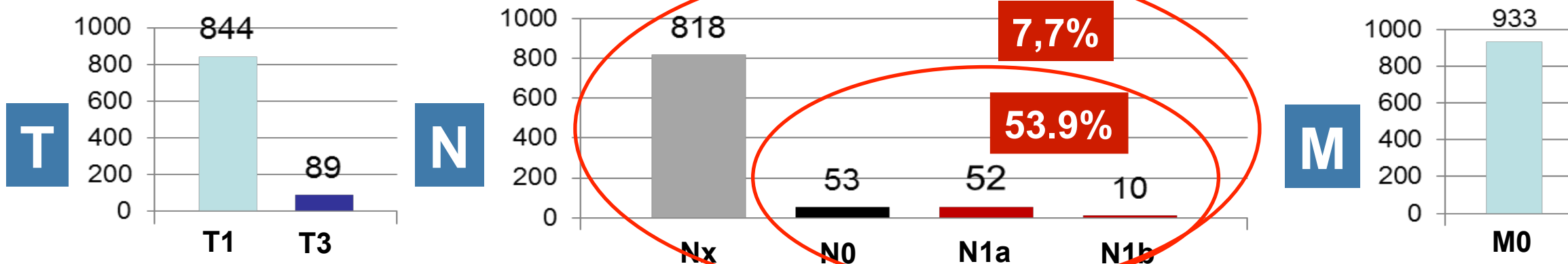


933 pts

Celestino P. Lombardi • Rocco Bellantone •
Carmela De Crea • Nunzia C. Paladino •
Guido Fadda • Massimo Salvatori • Marco Raffaelli

October 2002 – June 2007

Mean tumor size $5,5 \pm 3,0$ mm (1-10)



...not all micro PTC are indolent...



Roma, 8-11 novembre 2018

Linee guida italiane per il carcinoma differenziato della tiroide



ITALIAN CHAPTER



1. When thyroidectomy is indicated which strategy should be performed: total thyroidectomy or lobo-isthmectomy?
2. No intervention for papillary thyroid microcarcinoma
- 3. Indication for completion thyroidectomy after lobectomy**
4. The role of central and lateral compartment neck dissection in the management of differentiated thyroid carcinoma



Linee guida italiane per il carcinoma differenziato della tiroide



ITALIAN CHAPTER

Roma, 8-11 novembre 2018

3. Indication for completion thyroidectomy after lobectomy.

- a) Completion thyroidectomy is indicated to those patients for whom a total thyroidectomy would be suggested as the initial surgical treatment in case of primary diagnosis of differentiated thyroid cancer.
- b) Completion thyroidectomy is mandatory for differentiated thyroid carcinoma >4 cm, or any differentiated thyroid carcinoma with extrathyroidal extension and/or with histological evidence of lymph node metastases or aggressive variants.
- c) In the other cases, completion thyroidectomy is not routinely indicated, but the final decision should be taken based on a tailored strategy involving a careful discussion with the patient.

Completion thyroidectomy is not indicated for a final histology of NIFT-P.



Roma, 8-11 novembre 2018

Linee guida italiane per il carcinoma differenziato della tiroide



ITALIAN CHAPTER



1. When thyroidectomy is indicated which strategy should be performed: total thyroidectomy or lobo-isthmectomy?
2. No intervention for papillary thyroid microcarcinoma
3. Indication for completion thyroidectomy after lobectomy
- 4. The role of central and lateral compartment neck dissection in the management of differentiated thyroid carcinoma**



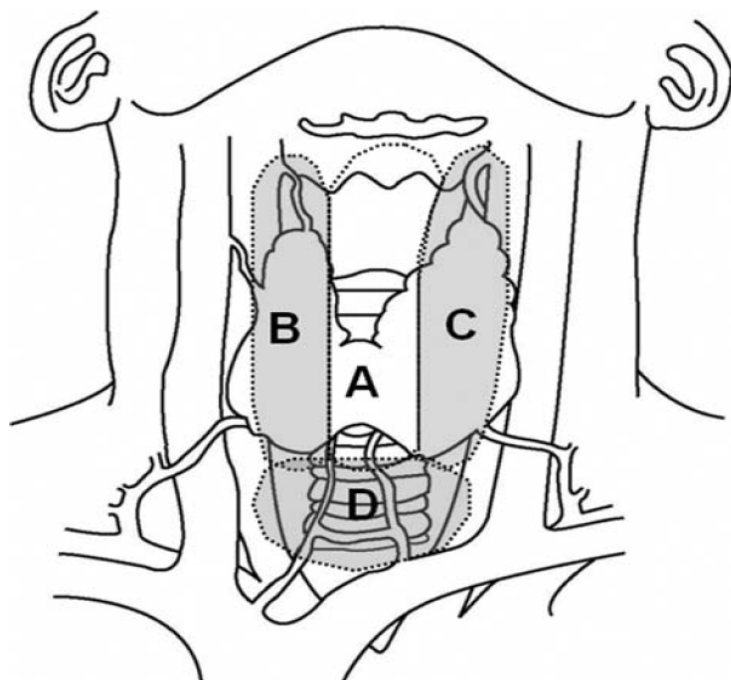
Linee guida italiane per il carcinoma differenziato della tiroide



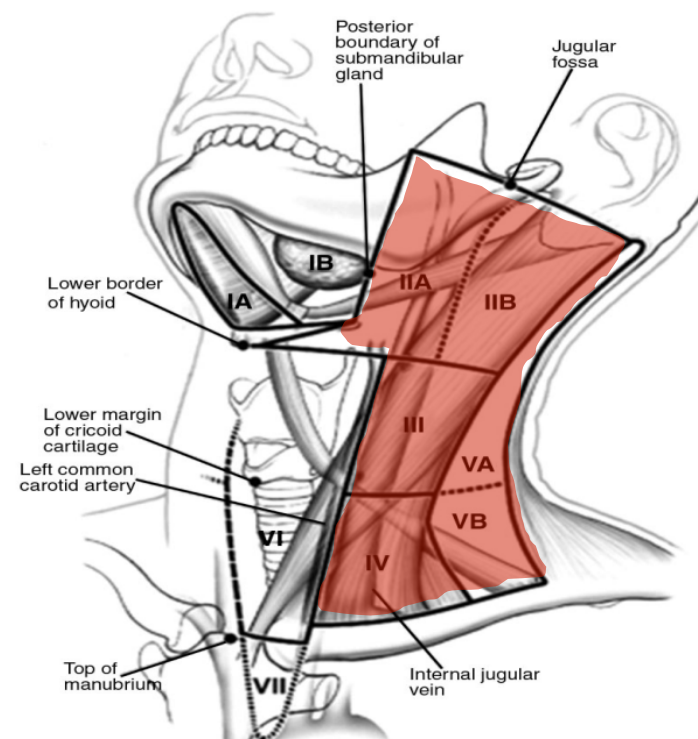
ITALIAN CHAPTER

Roma, 8-11 novembre 2018

4. The role of central and lateral compartment neck dissection in the management of differentiated thyroid carcinoma.



CENTRAL



LATERAL



Linee guida italiane per il carcinoma differenziato della tiroide



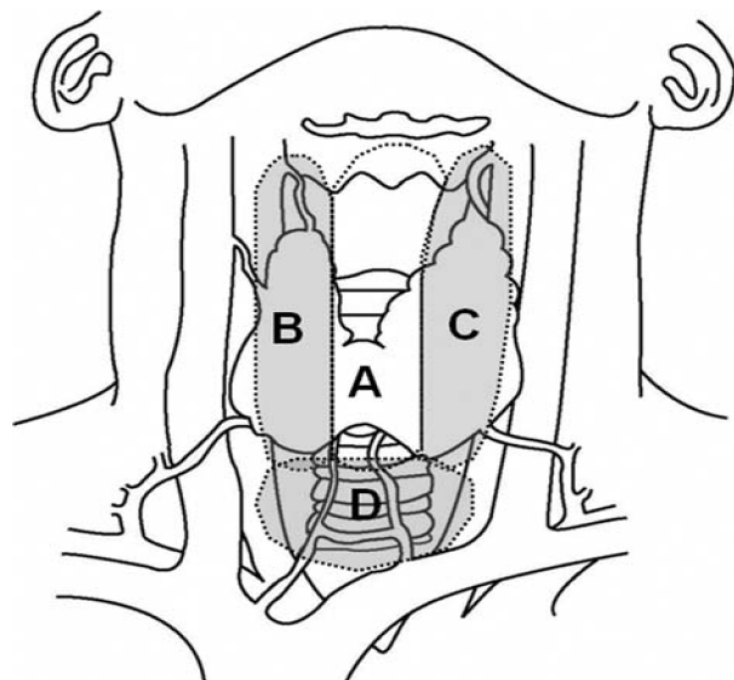
ITALIAN CHAPTER

Roma, 8-11 novembre 2018

4. The role of central and lateral compartment neck dissection in the management of differentiated thyroid carcinoma.

THYROID
Volume 19, Number 11, 2009
© Mary Ann Liebert, Inc.
DOI: 10.1089/thy.2009.0159

REVIEW ARTICLE



CENTRAL

Consensus Statement on the Terminology and Classification of Central Neck Dissection for Thyroid Cancer

The American Thyroid Association Surgery Working Group
with Participation from the American Association of Endocrine Surgeons,
American Academy of Otolaryngology—Head and Neck Surgery, and American Head and Neck Society

Boundaries

The central neck compartment is bounded superiorly by the hyoid bone, laterally by the carotid arteries, anteriorly by the superficial layer of the deep cervical fascia, and posteriorly by the deep layer of the deep cervical fascia. Because the location of the thyroid gland is low in the neck near the thoracic inlet, the lymphatic drainage is contiguous with the anterior superior mediastinum that is accessible via a cervical approach. As a result, the inferior border of the central compartment is defined as the innominate artery on the right and the corresponding axial plane on the left (Fig. 2).

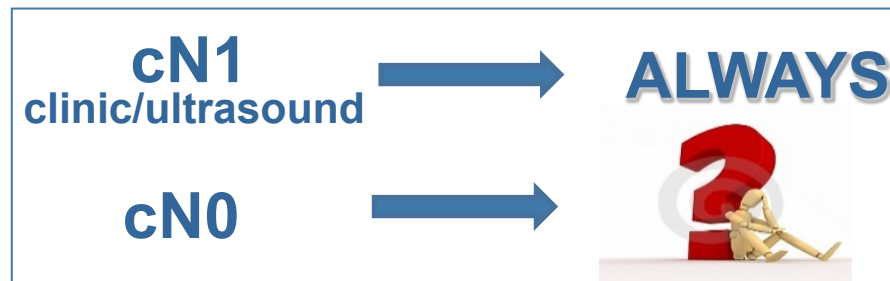


Roma, 8-11 novembre 2018

Linfadenectomia del compartimento centrale



ITALIAN CHAPTER



Controversy surrounding the role for routine central lymph node dissection for differentiated thyroid cancer

Tobias Carling, William D. Long III and Robert Udelsman

Current Opinion in Oncology 2010, 22:30-34

FOR

- Difficulty to pre- (with ultrasound and clinical examination) and intra-operatively evaluate lymph node involvement
- To improve accuracy in staging
- To decrease postoperative serum thyroglobulin levels
- To allow a better selection of patients for radioiodine treatment
- To reduce the recurrence rate in patients with cN0 PTC



Absence of any significant data confirming its advantages, especially in terms of recurrence and survival rate, in patients with occult lymph node involvement

AGAINST

- Higher risk of transient and permanent hypoparathyroidism
- Higher risk of unintentional laryngeal nerve injury



Roma, 8-11 novembre 2018

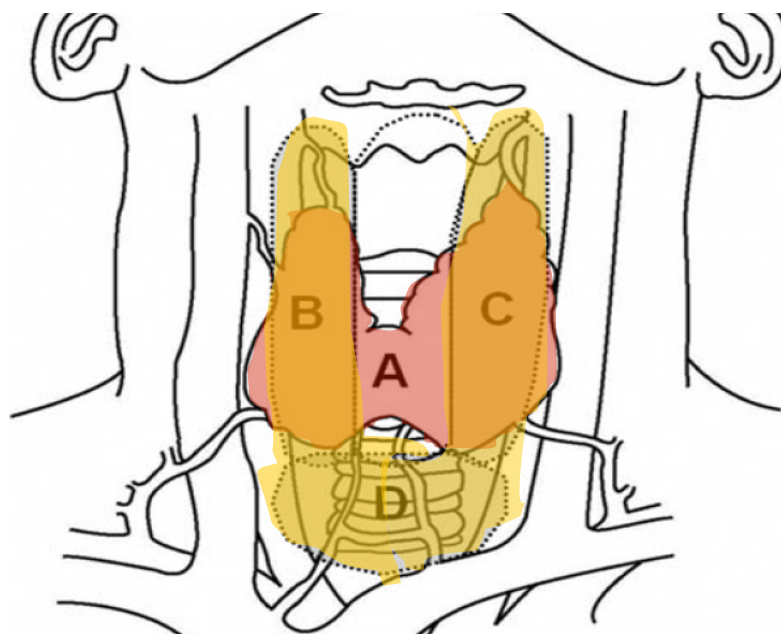
Papillary Thyroid Carcinoma



ITALIAN CHAPTER



Surgical Options



Nx

Ipsi-PCND

Bi-PCND



Roma, 8-11 novembre 2018

Linfadenectomia del compartimento centrale



ITALIAN CHAPTER



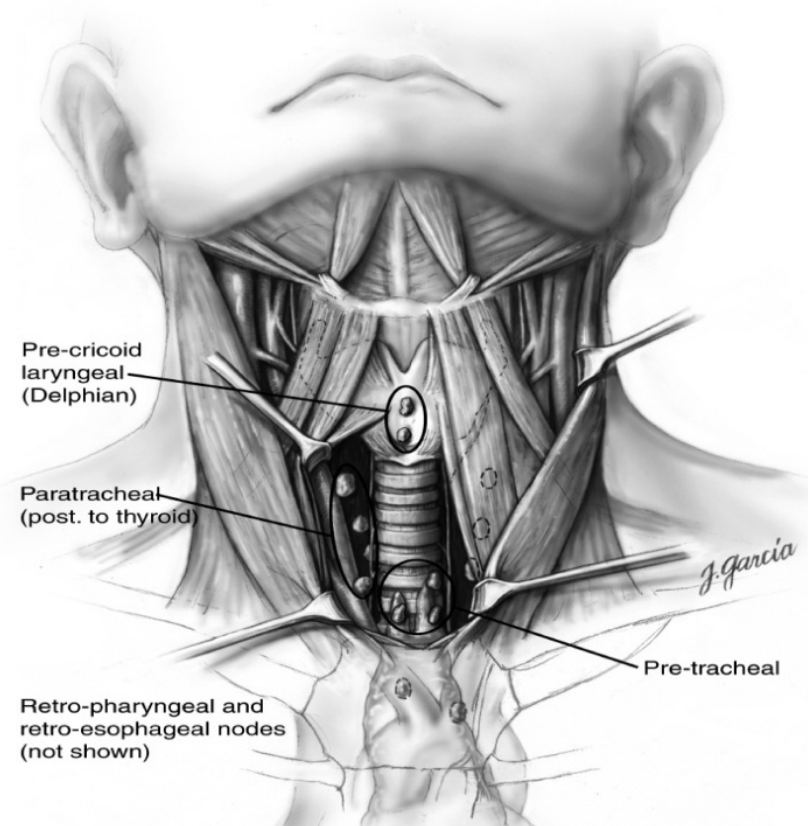
THYROID
Volume 19, Number 11, 2009
© Mary Ann Liebert, Inc.
DOI: 10.1089/thy.2009.0159

REVIEW ARTICLE

Consensus Statement on the Terminology and Classification of Central Neck Dissection for Thyroid Cancer

The American Thyroid Association Surgery Working Group
with Participation from the American Association of Endocrine Surgeons,
American Academy of Otolaryngology—Head and Neck Surgery, and American Head and Neck Society

- *Central neck dissection, bilateral:* Removal of the pre-laryngeal, pretracheal, and both the right and left paratracheal nodal basins.
- *Central neck dissection, unilateral:* Removal of the pre-laryngeal, pretracheal, and one paratracheal nodal basin.



Isolated contralateral central compartment nodal metastases are **exceptional** (0-3.6%)

Koo BS et al, Ann Surg 2009



Linee guida italiane per il carcinoma differenziato della tiroide



ITALIAN CHAPTER

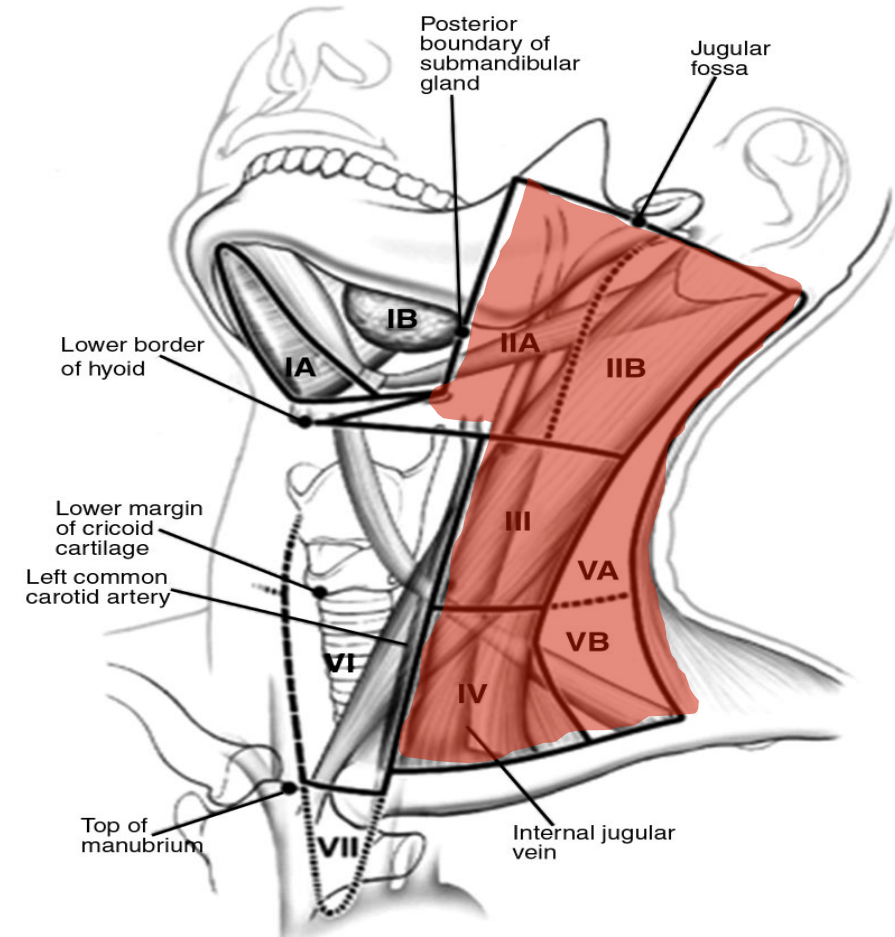
Roma, 8-11 novembre 2018

American Thyroid Association Consensus Review and Statement Regarding the Anatomy, Terminology, and Rationale for Lateral Neck Dissection in Differentiated Thyroid Cancer

Brendan C. Stack, Jr. (Chair),¹ Robert L. Ferris,² David Goldenberg,³ Megan Haymart,⁴ Ashok Shaha,⁵ Sheila Sheth,⁶ Julie Ann Sosa,⁷ and Ralph P. Tufano,^{6,*} for the American Thyroid Association Surgical Affairs Committee

- **Level I:** All nodes above the hyoid bone, below the mylohyoid muscle, and anterior to a transverse line drawn on each axial image through the posterior edge of the submandibular gland.
- **Level II:** Extends from the skull base at the lower level of the bony margin of the jugular fossa, to the level of the lower body of the hyoid bone. Level IIA nodes are level II nodes that surround the internal jugular vein (IJV). Level IIB nodes lie posterior to the spinal accessory cranial nerve (CN) deep to the SCM and are separated from the IJV by a fat plane.
- **Level III** nodes lie between the level of the lower body of the hyoid bone and the level of the lower margin of the cricoid cartilage.
- **Level IV** nodes lie between the level of the lower margin of the cricoid cartilage arch and the level of the clavicle on each side, as seen on axial CT scan.
- **Level V** nodes extend from the skull base at the posterior border of the attachment of the SCM to the level of the clavicle. Level Va nodes lie between the skull base and the level of the lower margin of the cricoid cartilage arch, behind the posterior edge of the SCM. Level Vb nodes lie between the level of the lower margin of the cricoid cartilage and the level of the clavicle (31).

THYROID
Volume 22, Number 5, 2012
© Mary Ann Liebert, Inc.
DOI: 10.1089/thy.2011.0312



LATERAL



Roma, 8-11 novembre 2018

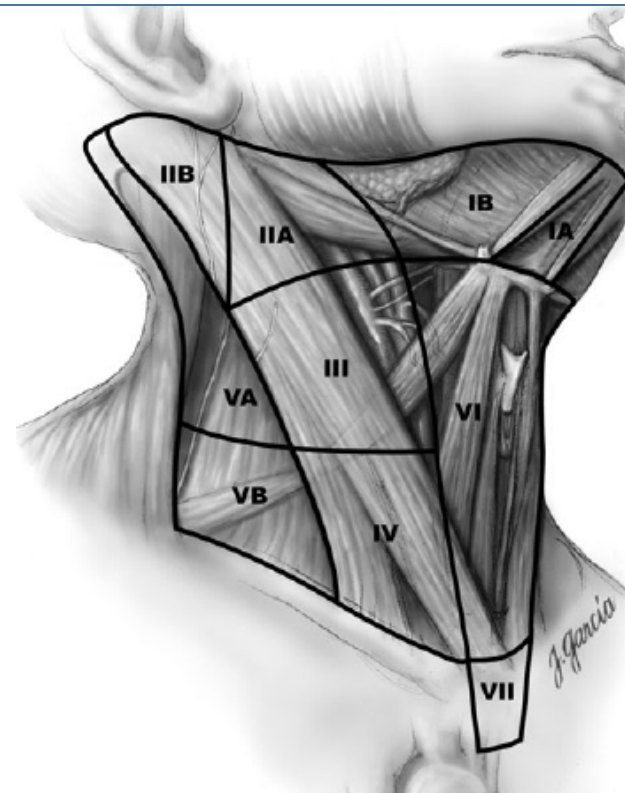
Linfadenectomia laterocervicale



ITALIAN CHAPTER

cN1 **→** **ALWAYS**

cN0 **→** **NEVER**





Linee guida italiane per il carcinoma differenziato della tiroide



ITALIAN CHAPTER

Roma, 8-11 novembre 2018

4. The role of central and lateral compartment neck dissection in the management of differentiated thyroid carcinoma.

- a) Prophylactic central compartment neck dissection (CCND) is not routinely indicated.
- b) CCND is appropriate for patients with differentiated thyroid carcinomas in the presence of clinically involved lymph nodes (cN1) either in the central compartment or in the lateral neck.
- c) Lateral neck dissection is appropriate for patients with differentiated thyroid carcinomas in the presence of metastatic lymph nodes (cN1) in the lateral neck.
- d) Intraoperative surgeon judgement is critical to decision making on whether central neck dissection is to be performed.



Roma, 8-11 novembre 2018

Linfadenectomia del compartimento centrale nel carcinoma papillare della tiroide



ITALIAN CHAPTER

Prospective evaluation of total thyroidectomy versus ipsilateral versus bilateral central neck dissection in patients with clinically node-negative papillary thyroid carcinoma

Marco Raffaelli, MD, Carmela De Crea, MD, Luca Sessa, MD, Piero Giustacchini, MD, Luca Revelli, MD, Chiara Bellantone, and Celestino Pio Lombardi, MD, Rome, Italy



- Outcome oncologico a breve termine simile tra i tre gruppi
- Linfadenectomia del compartimento centrale completa
 - pro** migliore stadiazione dei pazienti
 - contro** aumentato rischio di ipocalcemia transitoria
- Linfadenectomia dell' emicompartimento centrale omolaterale
 - pro** ridotta ipocalcemia transitoria
 - contro** ¼ dei pz ha metastasi linfonodali bilaterali



Linfadenectomia del compartimento centrale nel carcinoma papillare della tiroide



ITALIAN CHAPTER

Roma, 8-11 novembre 2018

Langenbecks Arch Surg (2013) 398:383–388
DOI 10.1007/s00423-012-1036-3

ORIGINAL ARTICLE

Can intraoperative frozen section influence the extension of central neck dissection in cN0 papillary thyroid carcinoma?

Marco Raffaelli · Carmela De Crea · Luca Sessa ·
Piero Giustacchini · Rocco Bellantone ·
Celestino Pio Lombardi



Settembre 2010 - Settembre 2011

195 CPT



48 pazienti inclusi

ESAME ISTOLOGICO ESTEMPORANEO SU LINFADENECTOMIA
DELL'EMICOMPARTIMENTO CENTRALE OMOLATERALE AL TUMORE

Sensibilità 75%

Specificità 100%

Accuratezza diagnostica 89%



Linfadenectomia del compartimento centrale nel carcinoma papillare della tiroide



ITALIAN CHAPTER

Roma, 8-11 novembre 2018

Ann Surg Oncol
DOI 10.1245/s10434-015-4383-9

Annals of
SURGICAL ONCOLOGY
OFFICIAL JOURNAL OF THE SOCIETY OF SURGICAL ONCOLOGY

ORIGINAL ARTICLE – ENDOCRINE TUMORS

Ipsilateral Central Neck Dissection Plus Frozen Section Examination Versus Prophylactic Bilateral Central Neck Dissection in cN0 Papillary Thyroid Carcinoma

2015



Marco Raffaelli, MD¹, Carmela De Crea, MD¹, Luca Sessa, MD¹, Guido Fadda, MD², Chiara Bellantone, MD¹, and Celestino P. Lombardi, MD¹

- **Il riscontro di metastasi linfonodali occulte** del compartimento centrale è frequente nei CPT unifocali cN0
- **L'esame istologico estemporaneo** può essere **utile nel determinare l'estensione della linfadenectomia** del compartimento centrale
- Il riscontro di **falsi negativi** è più frequente in caso di presenza di **micrometastasi** linfonodali che generalmente hanno minori implicazioni cliniche
- Nei CPT clinicamente unifocali, cN0, **l'ipsiCCD con esame istologico estemporaneo potrebbe essere considerato il trattamento di scelta** nel tentativo di ridurre l'incidenza di ipocalcemia transitoria



Roma, 8-11 novembre 2018

Linfadenectomia del compartimento centrale nel carcinoma papillare della tiroide



ITALIAN CHAPTER



U.O.C. Chirurgia Endocrina e Metabolica U.C.S.C.

- cN1
- infiltrazione extracapsulare
- multifocalità



Linfadenectomia del Compartimento Centrale Bilaterale **SEMPRE**

cN0 clinicamente unifocale senza segni di infiltrazione extracapsulare



- Ispezione accurata del compartimento centrale
- Linfadenectomia emicompartimento centrale

Esame istologico estemporaneo

Positivo

Negativo

Linfadenectomia del CC bilaterale

STOP



Roma, 8-11 novembre 2018

Gemelli



Fondazione Policlinico Universitario Agostino Gemelli IRCCS
Università Cattolica del Sacro Cuore



ITALIAN CHAPTER



Thanks !



Roma, 8-11 novembre 2018

Giulia - Intervento ed esame istologico



ITALIAN CHAPTER



Giulia viene sottoposta a lobectomia dx

- Carcinoma tiroideo papillare var. classica e follicolare, 16 mm diametro massimo. Intracapsulare. Non evidenza di invasione vascolare.
- pT1Nx (AJCC/TNM 7ed.)
- **pT1N0 (AJCC/TNM 8ed.)**



Roma, 8-11 novembre 2018

Giulia - Chirurgia di completamento?



ITALIAN CHAPTER



- Sì
- No



Roma, 8-11 novembre 2018

Giulia. Stadiazione post-chirurgica



ITALIAN CHAPTER



- A 3 mesi dall'intervento Giulia viene sottoposta a controlli bioumorali e ad ecografia cervicale
- Tg 18.0 ng/ml, abTg 12 (vn < 4)
- TSH 3.6 μ U/ml
- Obiettività ecografica cervicale del tutto negativa



Roma, 8-11 novembre 2018

Teresa - Intervento ed esame istologico



ITALIAN CHAPTER



Teresa viene sottoposta a: **Tiroidectomia totale con esplorazione del compartimento centrale dx**

- Lobo destro: carcinoma tiroideo papillare var. classica 6 mm diametro massimo, con focale superamento della capsula tiroidea. La neoplasia raggiunge il margine di resezione chirurgica. Non evidenza di invasione vascolare. Nel restante parenchima altri 2 microfocolai di carcinoma tiroideo papillare, rispettivamente di 0.5 e 1 mm, intracapsulari.
- Lobo sinistro: indenne da focolai neoplastici.
- Due linfonodi di aspetto reattivo (area VI destra)
- **pT1Nx (AJCC/TNM 7ed.)**
- **pT1N0 (AJCC/TNM 8ed.)**



Roma, 8-11 novembre 2018

Indicazione a ¹³¹I?



ITALIAN CHAPTER



- Sì
- No



Roma, 8-11 novembre 2018

LG Italiane 2018 per il carcinoma differenziato tiroideo



Stratificazione dinamica del rischio *R. Guglielmi*



Roma, 8-11 novembre 2018

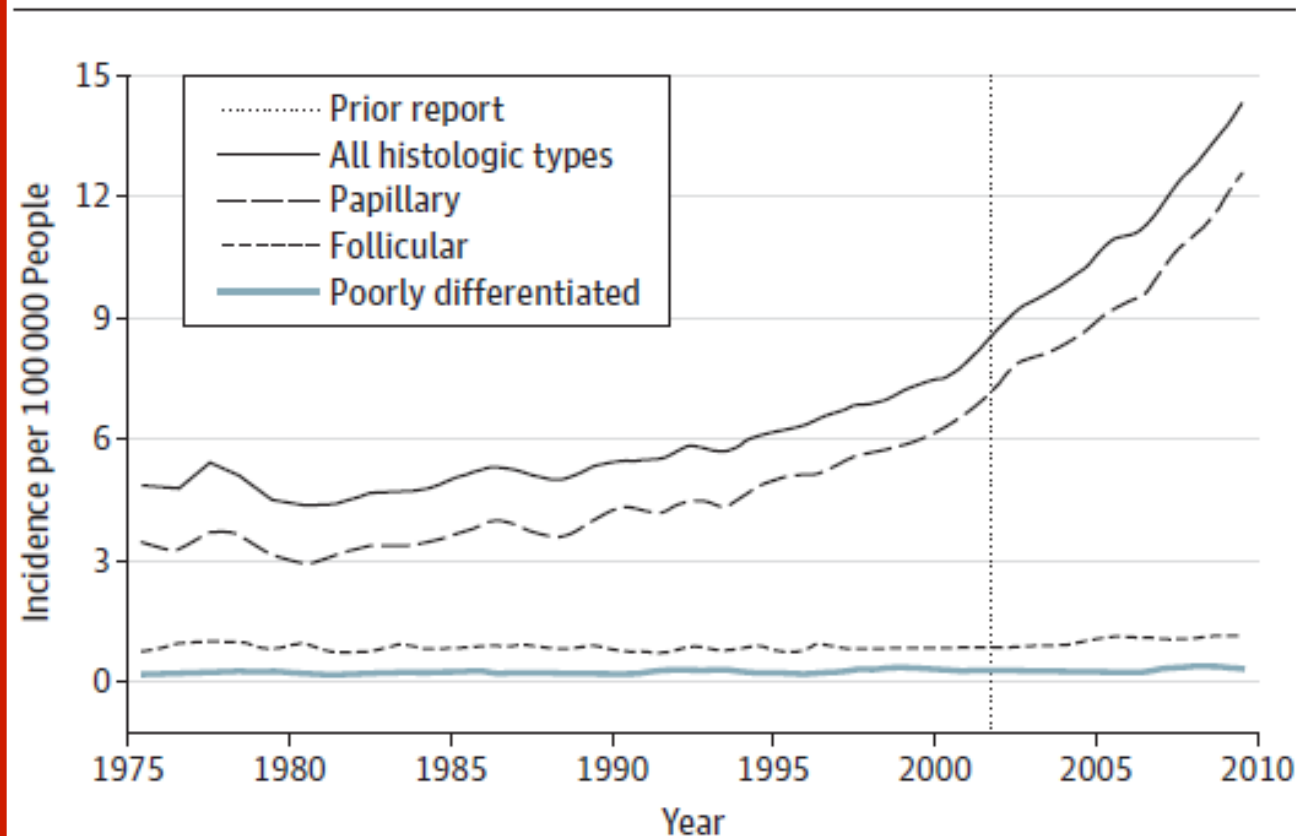
Epidemiology of thyroid carcinoma

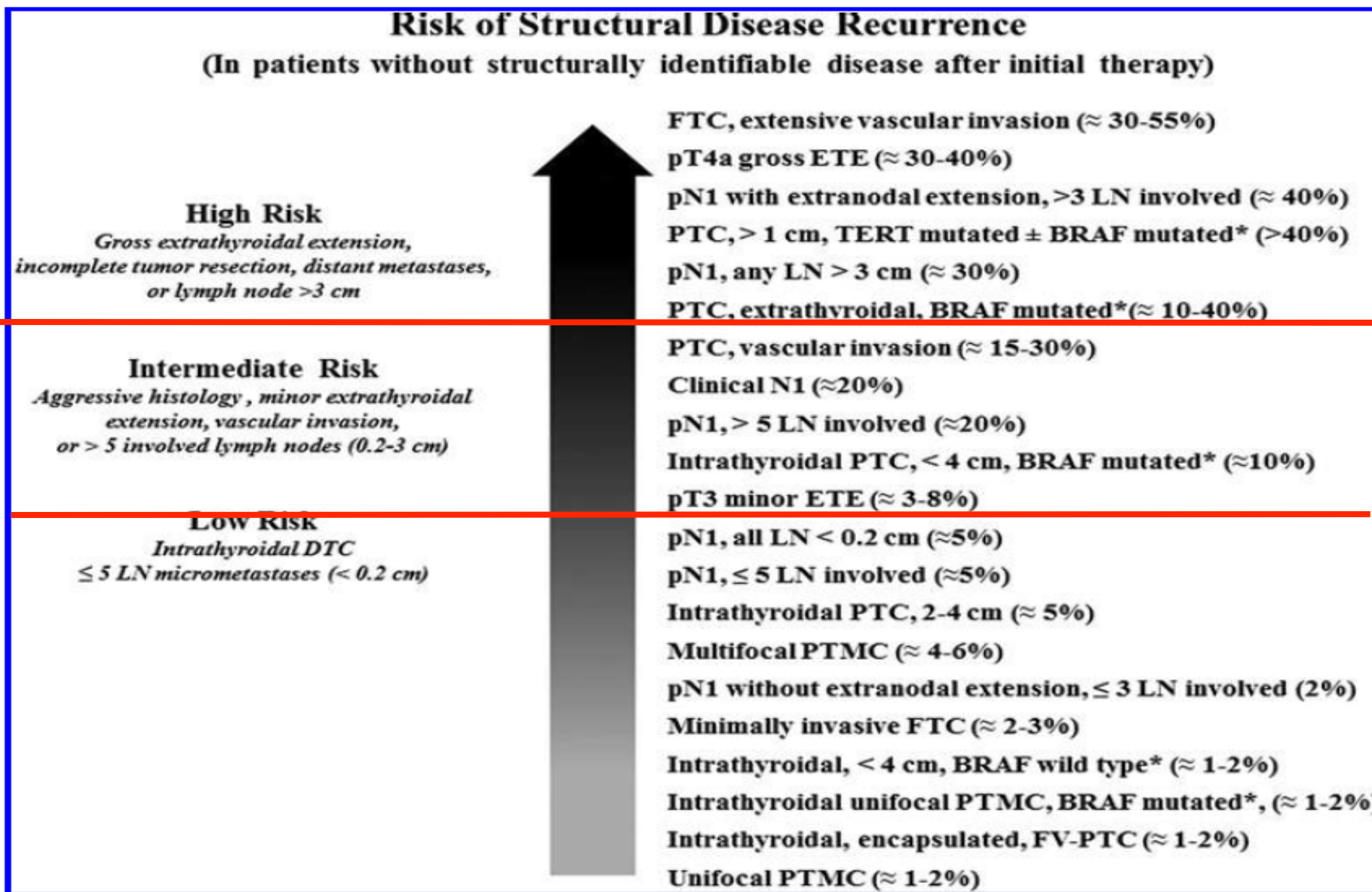


ITALIAN CHAPTER



Figure 2. Thyroid Cancer Incidence by Histologic Type, 1975 to 2009







Roma, 8-11 novembre 2018

AJCC Prognostic stage groups for differentiated carcinomas (TNM 8°Edition)



ITALIAN CHAPTER



Age at diagnosis	T	N	M	Stage
<55 years	Any T	Any N	M0	I
<55 years	Any T	Any N	M1	II
>=55 years	T1	N0/NX	M0	I
>=55 years	T1	N1	M0	II
>=55 years	T2	N0/NX	M0	I
>=55 years	T2	N1	M0	II
>=55 years	T3a/T3b	Any N	M0	II
>=55 years	T4a	Any N	M0	III
>=55 years	T4b	Any N	M0	IVA
>=55 years	Any T	Any N	M1	IVB



Primary tumor (T) category

TNM 8°Edition



Minor extrathyroidal extension was removed from the definition of T3 disease. As a result, minor extrathyroidal extension does not affect either T category or overall stage.

T3a is a new category and refers to a tumor >4 cm limited to thyroid.

T3b is a new category and is defined as a tumor of any size with **gross extrathyroid extension** invading **only strap muscles** (sternohyoid, sternothyroid, thyrohyoid or omohyoid).



Roma, 8-11 novembre 2018

Lymphnodes (N)

TNM 8°Edition



ITALIAN CHAPTER

N category	Criteria
NX	Regional nodes not assessed
N0	No evidence of regional node metastasis
N0a	One or more Isto-Cytologically confirmed negative nodes
N0b	No radiological or clinical evidence of node metastasis
N1	Metastasis to regional nodes
N1a	Metastasis to level VI or VII
N1b	Metastasis to lateral neck or retropharyngeal nodes



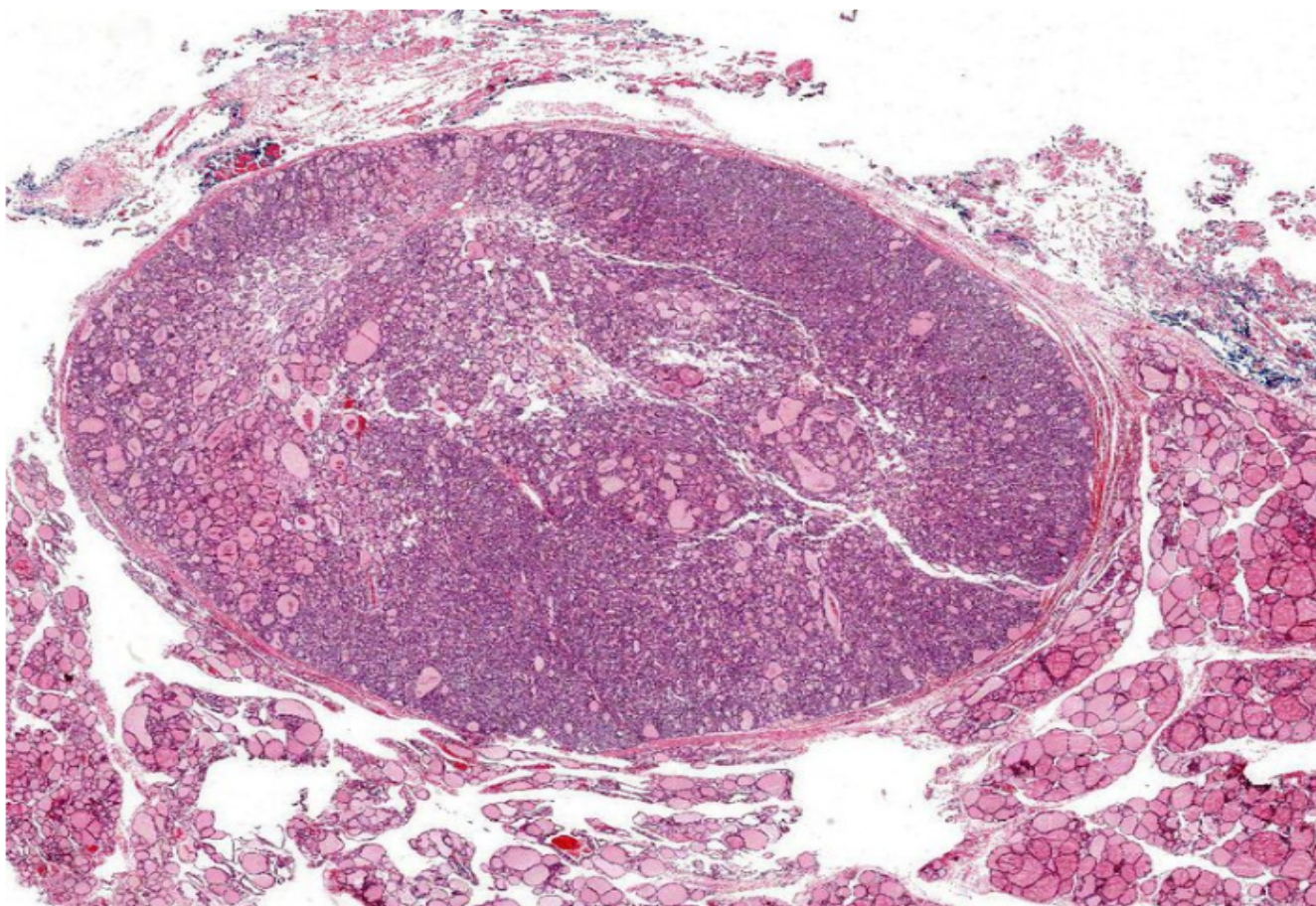
Roma, 8-11 novembre 2018

JAMA Oncology | Original Investigation

Nomenclature Revision for Encapsulated Follicular Variant of Papillary Thyroid Carcinoma

A Paradigm Shift to Reduce Overtreatment of Indolent Tumors

Yuri E. Nikiforov, MD, PhD; Raja R. Seethala, MD; Giovanni Tallini, MD; Zubair W. Baloch, MD, PhD; Fulvio Basolo, MD; Lester D. R. Thompson, MD; Justine A. Barletta, MD; Bruce M. Wenig, MD; Abir Al Ghuzlan, MD; Kennichi Kakudo, MD, PhD; Thomas J. Giordano, MD, PhD; Venancio A. Alves, MD, PhD; Elham Khanafshar, MD, MS; Sylvia L. Asa, MD, PhD; Adel K. El-Naggar, MD; William E. Gooding, MS; Steven P. Hodak, MD; Ricardo V. Lloyd, MD, PhD; Guy Maytal, MD; Ozgur Mete, MD; Marina N. Nikiforova, MD; Vania Nosé, MD, PhD; Mauro Papotti, MD; David N. Poller, MB, ChB, MD, FRCPath; Peter M. Sadow, MD, PhD; Arthur S. Tischler, MD; R. Michael Tuttle, MD; Kathryn B. Wall; Virginia A. LiVolsi, MD; Gregory W. Randolph, MD; Ronald A. Gosssein, MD



A noninvasive follicular thyroid neoplasm with papillary-like nuclear features, or Niftp, a type of tumor that was previously considered a kind of cancer, but has been downgraded by a panel of doctors. Yuri Nikiforov



Roma, 8-11 novembre 2018

THE "ON GOING" RISK STRATIFICATION: A NEW EMERGING CONCEPT



ITALIAN CHAPTER



Re-evaluation
of the risk of recurrence
at any step





Role of basal or stimulated Tg and imaging in predicting the outcome of DTC patients (7 years FU)



ITALIAN CHAPTER

Roma, 8-11 novembre 2018

TABLE 8. USING THYROGLOBULIN AND RESPONSE TO INITIAL THERAPY ASSESSMENTS AT THE 2-YEAR FOLLOW-UP TIME POINT TO PREDICT LIKELIHOOD OF BEING NO CLINICAL EVIDENCE OF DISEASE AT FINAL FOLLOW-UP

<i>Initial risk stratification</i>	<i>Response to therapy variables during first 2 years of follow-up</i>	<i>NED at final follow-up</i>
Low risk (<i>n</i> = 104)	Suppressed Tg < 1 ng/mL alone	84%
	Stimulated Tg < 1 ng/mL alone	89%
	Excellent response (imaging negative ^a and suppressed Tg < 1 ng/mL)	94%
	Excellent response (imaging negative ^a and stimulated Tg < 1 ng/mL)	97%
Intermediate risk (<i>n</i> = 241)	Suppressed Tg < 1 ng/mL alone	74%
	Stimulated Tg < 1 ng/mL alone	80%
	Excellent response (imaging negative ^a and suppressed Tg < 1 ng/mL)	90%
	Excellent response (imaging negative ^a and stimulated Tg < 1 ng/mL)	94%
High risk (<i>n</i> = 126)	Suppressed Tg < 1 ng/mL alone	39%
	Stimulated Tg < 1 ng/mL alone	55%
	Excellent response (imaging negative ^a and suppressed Tg < 1 ng/mL)	80%
	Excellent response (imaging negative ^a and stimulated Tg < 1 ng/mL)	82%

n = 471 with both suppressed and stimulated Tg values available for analysis.

^aNegative imaging: normal neck US in all patients. In addition, any other functional or cross-sectional imaging obtained at the discretion of the treating physician was interpreted as having no evidence of persistent/recurrent thyroid cancer.

NED, no clinical evidence of disease.



Same concept: Different series/group



ITALIAN CHAPTER

Roma, 8-11 novembre 2018

European Journal of Endocrinology (2011) 165 441–446

ISSN 0804-4643

CLINICAL STUDY

Delayed risk stratification, to include the response to initial treatment (surgery and radioiodine ablation), has better outcome predictivity in differentiated thyroid cancer patients

Maria Grazia Castagna¹, Fabio Maino¹, Claudia Cipri¹, Valentina Belardini¹, Alexandra Theodoropoulou¹, Gabriele Cevenini² and Furio Pacini¹

	Final outcome			
	Remission	Persistent disease	Recurrent	Mortality
ETA				
Low risk (<i>n</i> 231)	211* (91.4%)	14 (6.1%)	6 (2.5%)	0 (0%)
High risk (<i>n</i> 281)	173 [†] (61.6%)	92 [‡] (32.8%)	8 (2.8%)	8 (2.8%)
ATA				
Low risk (<i>n</i> 244)	221* (90.8%)	15 (6.0%)	8 (3.2%)	0 (0%)
Intermediate/high risk (<i>n</i> 268)	163 [†] (60.8%)	91 [‡] (33.9%)	6 (2.3%)	8 (3.1%)
DRS				
Low risk (<i>n</i> 353)	341* (96.6%)	0 (0%)	12 (3.4%)	0 (0%)
High risk (<i>n</i> 159)	43 [†] (27.1%)	106 [‡] (66.6%)	2 (4.0%) ^a	8 (5.1%)

* $P=0.005$; [†] $P<0.0001$; [‡] $P<0.0001$.

^aCalculated on the number of high-risk patients who achieved remission ($n=45$) at some point during the follow-up.

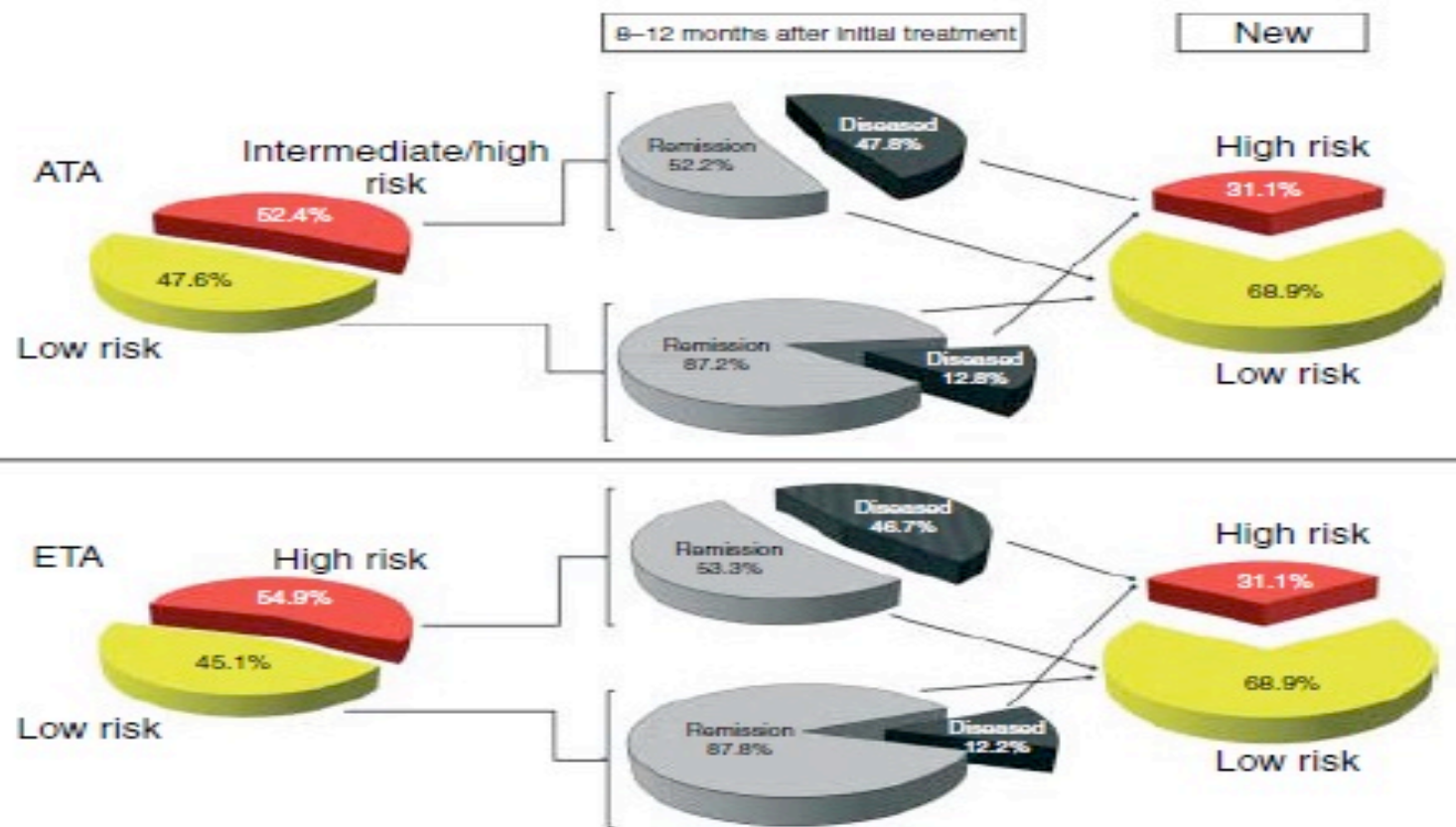


Figure 1 (Left side) Post-surgical risk stratification based on the ETA and ATA guidelines; (center) clinical status at the 8- to 12-month control after initial treatment; (right side) composition of the DRS system.



Why should we care about this re-stratification?



1) Patients want to know about their prognosis

The pathology can give us an idea but then we will see during FU ...

After the evidence of clinical remission we can better predict the risk of recurrence!!!

2) To decide the strategy of follow-up: frequency of controls



After clinical remission:

- Every 18 months when the risk of recurrence is low
- Every 8-12 months when the risk of recurrence is higher

Not cured patients:

- Every 12 months when there is a "biochemical" disease
- Every 6 months when there is a "structural" disease

3) To move from LT4 suppressive to LT4 substitutive therapy



A prolonged LT4 suppressive therapy increases the risk to develop cardiac problems and/or osteoporosis especially in older patients



Roma, 8-11 novembre 2018

Risk stratification incorporating the response to initial treatment



ITALIAN CHAPTER



Recommendation statement:

- The ATA Initial Risk Stratification System is recommended for all DTC patients treated with thyroidectomy
- The initial recurrence risk estimates should be modified to incorporate the response to initial therapy
- Risk estimates should be further modified during follow-up, as a function of the clinical course of the disease.



Response to initial therapy



- **Excellent response:** Negative or non-specific structural or functional imaging findings and either suppressed Tg <0.2 ng/mL
or
TSH-stimulated Tg <1 ng/mL
- **Biochemical incomplete response:** Detectable basal or stimulated Tg or rising anti-Tg antibody levels and negative imaging
- **Structural incomplete response:** Evidence of disease at structural or functional imaging, with any Tg level, with or without anti-Tg antibodies.



First Follow-up evaluation after initial treatment (surgery + ^{131}I)



- **First follow-up visit (→ response to primary treatment) at 6 -12 months**
- **Evaluation based on :**
 - **serum Tg on L-T4 with a sensitive Tg assay or after rhTSH**
 - **serum TgAb;**
 - **neck US**
- **Functional (^{131}I WBS, ^{18}F FDG PET) and/or morphologic (CT, MR) evaluation should be considered in patients at high risk of persistent disease**
- **In case of US evidence of suspicious neck lesions, FNA cytology + FNA-Tg recommended (if FNA results would change the management)**



Dynamic Risk Stratification in Patients with DTC Treated Without Radioactive Iodine

DP. Momesso, F Vaisman, SP. Yang, DA. Bulzico, R Corbo, M Vaisman, and RM Tuttle



ITALIAN CHAPTER

JCE&M, 2016

The definition of the response to initial treatment

Table 1. Response to Therapy Assessment Definitions Based on Initial Therapy

	TT Without RAI Ablation	Lobectomy
Excellent response: No clinical, biochemical or structural evidence of disease	Nonstimulated Tg < 0.2 ng/mL or stimulated Tg < 2 ng/mL and undetectable TgAb and negative imaging	Stable, nonstimulated Tg < 30 ng/mL and undetectable TgAb and negative imaging
Biochemical incomplete response: Abnormally elevated serum Tg or increasing TgAb levels in the absence of localizable disease	Nonstimulated Tg > 5 ng/mL or stimulated Tg > 10 ng/mL or increasing Tg values over time with similar TSH levels or increasing TgAb levels and negative imaging	Nonstimulated Tg > 30 ng/mL or increasing Tg values over time with similar TSH levels or increasing TgAb levels and negative imaging
Structural incomplete response: Persistent or newly identified locoregional or distant metastases with or without abnormal Tg or TgAb	Structural or functional evidence of disease regardless of Tg or TgAb	Structural or functional evidence of disease regardless of Tg or TgAb
Indeterminate response: Nonspecific biochemical or structural findings which cannot be confidently classified as either benign or malignant	Nonspecific findings on imaging studies or Faint uptake in thyroid bed on RAI scanning or nonstimulated Tg 0.2–5 ng/mL or stimulated Tg 2–10 ng/mL, or TgAb levels stable or declining in the absence of structural or functional disease	Nonspecific findings on imaging studies or TgAb levels stable or declining in the absence of structural or functional disease



Roma, 8-11 novembre 2018

Prolonged follow up in Clinical practice



ITALIAN CHAPTER

EXCELLENT RESPONSE: NEGATIVE NECK US, LOW AND STABLE LEVELS OF SERUM Tg,
(cured) NEGATIVE AbTg

On going risk stratification

Stable levels of serum Tg, negative neck US, negative AbTg: ***LOW RISK OF RECURRENCE, relaxed follow up with 12-18 months controls***

Increasing trend of serum Tg and negative neck US: ***INTERMEDIATE RISK OF RECURRENCE, need to carefully follow the serum Tg increase and calculation of DT***

Stable or increasing levels of serum Tg and evidence of suspicious lymphnode or suspicious nodule in the remnant lobe: ***HIGH RISK OF RECURRENCE, need of further investigation (i.e. FNAC)***



Roma, 8-11 novembre 2018

Stratificazione Rischio recidiva ATA per rifinire/personalizzare stima DSS AJCC 8°Ed



ITALIAN CHAPTER



- **4881 Pt DTC età < 55 aa** (arruolati dal 1980 al 2016 al Memorial SKCC)
- 73% femmine
- 96% PTC
- **FU mediano 6.6 aa (2-35)**
- **122 Pt (2.5%):** Decesso malattia-relata

Stadio AJCC	% Pt (Npt/tot Pt)	Categorie ATA Rischio recidiva		
		Bassa	Intermedia	Alta
I	98% (4797/4881)	38% (1799/4797)	56% (2692/4797) FTC e Hürthle	6% (306/4797) T3b/T4a/T4b Ogni N, M0
II	2% (84/4881)	--	--	100% (84/84) M1
Totale	4881	1799	2692	390

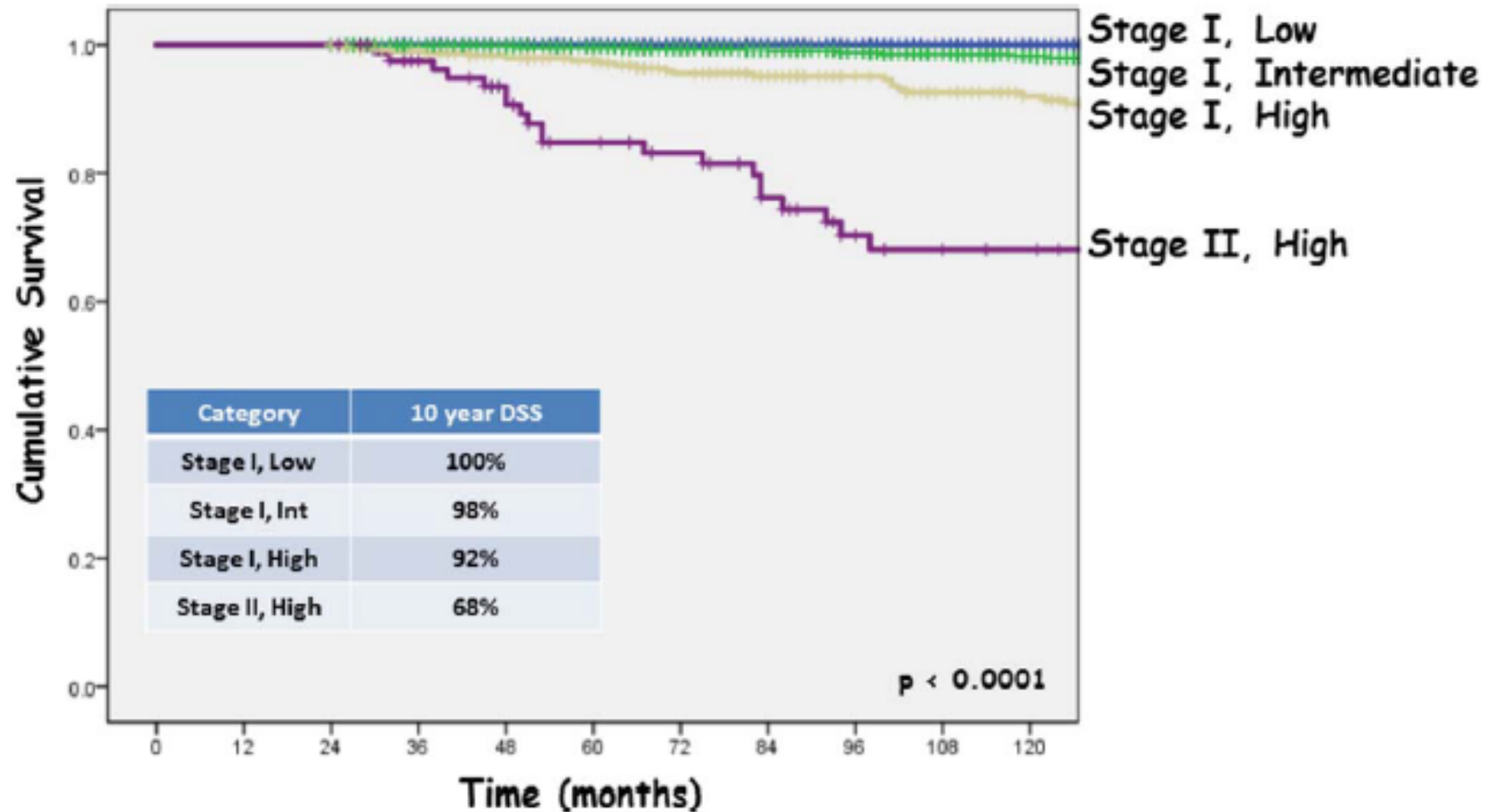
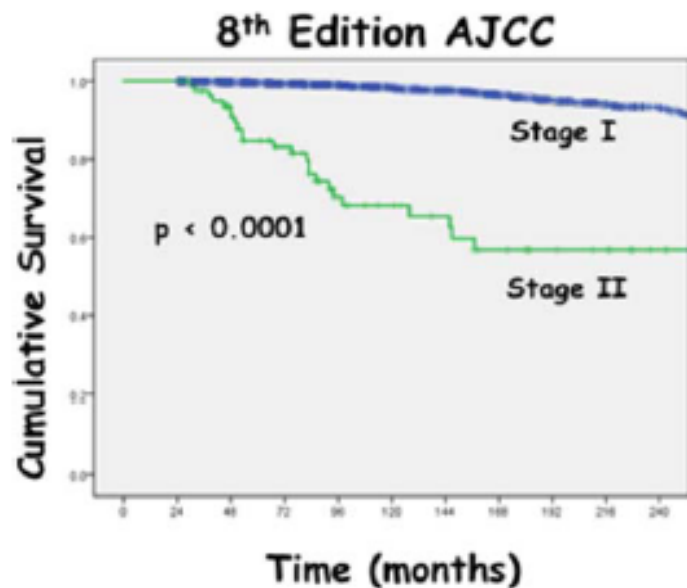


Roma, 8-11 novembre 2018

DTC Pt < 55 aa: DSS a 10 aa stadi AJCC 8° stratificati per rischio ATA



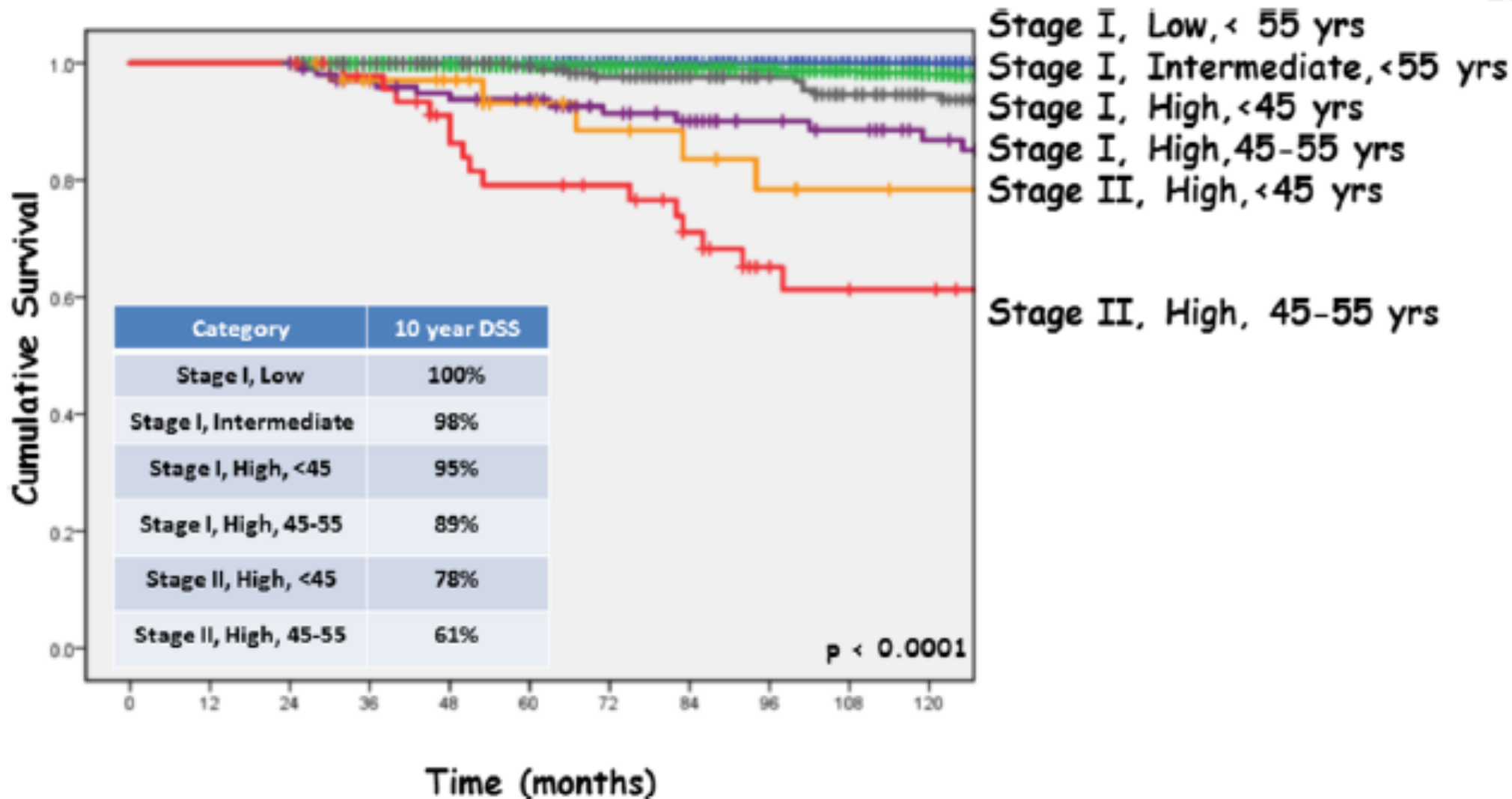
ITALIAN CHAPTER



Disease-specific Survival by Year		
Stage	5 yr	10 yr
I	100 %	98 %
II	85 %	68 %



DSS a 10 aa stadi AJCC 8° stratificati per rischio ATA ed età





THE "ON GOING" RISK STRATIFICATION

Tuttle M et al, Thyroid 2010



588 DTC restaged according to the results of serum Tg (basal and/or stimulated) and imaging 2 yrs after initial treatment (total thyroidectomy and 131-I)



% of cases with persistent or recurrent disease after a mean follow up of 7 years (range 1-15 yrs)

Risk stratification ATA	LOW	INTERMEDIATE	HIGH
Excellent rhTSH-Tg < 1 ng/ml, no structural disease	3%	21%	68%
Incomplete LT4 Tg >1 ng/mL, rhTSH-Tg > 10 ng/mL, rising Tg values, or structural disease	13%	41%	79%



Roma, 8-11 novembre 2018

LG Italiane 2018 per il carcinoma differenziato tiroideo



Terapia ablativa con ^{131}I *M. Salvatori*



Roma, 8-11 novembre 2018



ITALIAN CHAPTER

Journal of Endocrinological Investigation (2018) 41:849–876
<https://doi.org/10.1007/s40618-018-0884-2>

ORIGINAL ARTICLE



Italian consensus on diagnosis and treatment of differentiated thyroid cancer: joint statements of six Italian societies

F. Pacini¹ · F. Basolo² · R. Bellantone³ · G. Boni⁴ · M. A. Cannizzaro⁵ · M. De Palma⁶ · C. Durante⁷ · R. Elisei⁸ · G. Fadda⁹ · A. Frasoldati¹⁰ · L. Fugazzola^{11,12} · R. Guglielmi¹³ · C. P. Lombardi³ · P. Miccoli² · E. Papini¹³ · G. Pellegriti¹⁴ · L. Pezzullo¹⁵ · A. Pontecorvi¹⁶ · M. Salvatori¹⁷ · E. Seregini¹⁸ · P. Vitti⁸

Massimo Salvatori

*Istituto di Medicina Nucleare,
Fondazione Policlinico Universitario A. Gemelli IRCCS,
Università Cattolica S. Cuore-Roma
massimo.salvatori@unicatt.it*



Roma, 8-11 novembre 2018

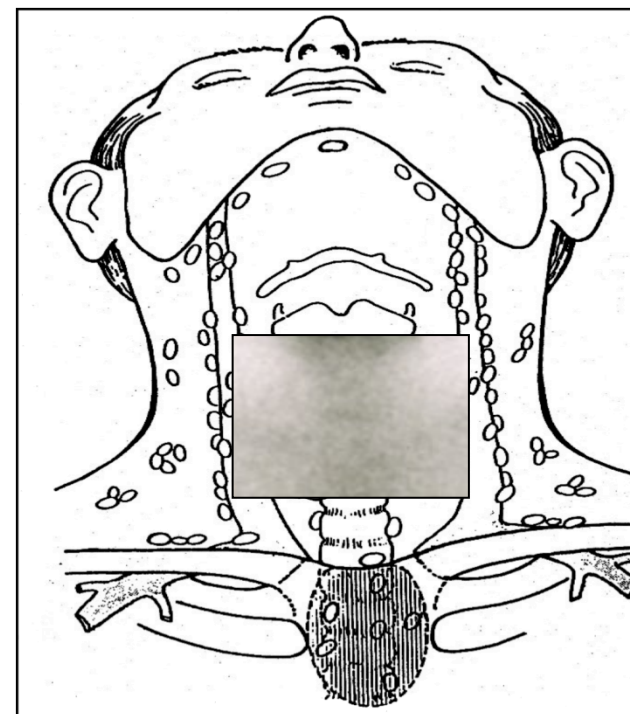
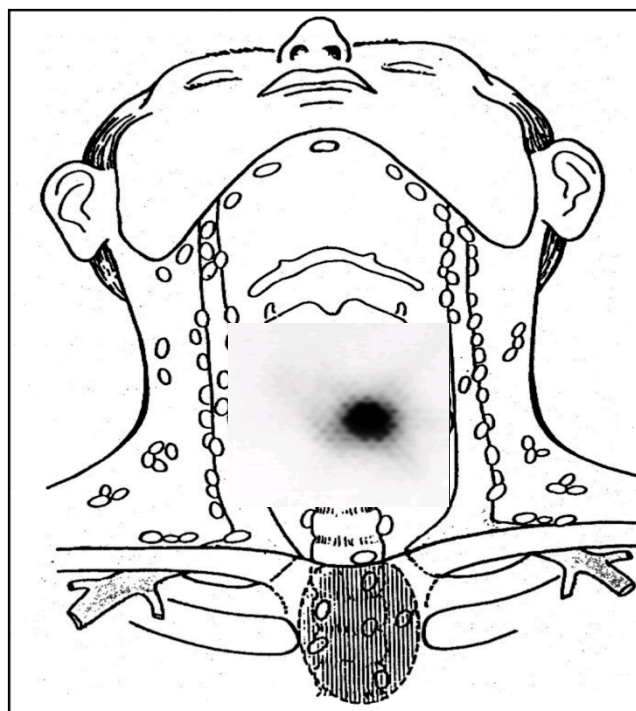
Item 9



ITALIAN CHAPTER



Post-surgical thyroid ablation with radioiodine:
routine or selective indication





Goals of RAI Therapy in DTC



RAI therapy type	Goal	Potential benefit
Remnant ablation	Destroy normal thyroid tissue remaining after total thyroidectomy	Improve initial staging; facilitate highly sensitive follow-up
Adjuvant treatment	Destroy subclinical microscopic tumor deposits that may be present	Decrease recurrence; improve disease-specific survival
Treatment of known residual/ recurrent disease	Destroy known residual/recurrent disease	Achieve excellent response (remission)
		Improve disease-specific survival
		Improve progression-free survival



Indication to RAI Remnant Ablation



- a) The indication ... should be established both on the basis of the **AJCC/UICC staging (VIII edition)** and the **Initial Risk Stratification System** proposed by **ATA**, useful to predict the risk of mortality and of disease recurrence/persistence, respectively.
- b) The indication should also be based on the postoperative disease status evaluated by **serum Tg** ... and **neck US**. In selected cases, other imaging procedures (including **diagnostic RAI WBS**) may be indicated.



ATA Initial Risk Stratification System

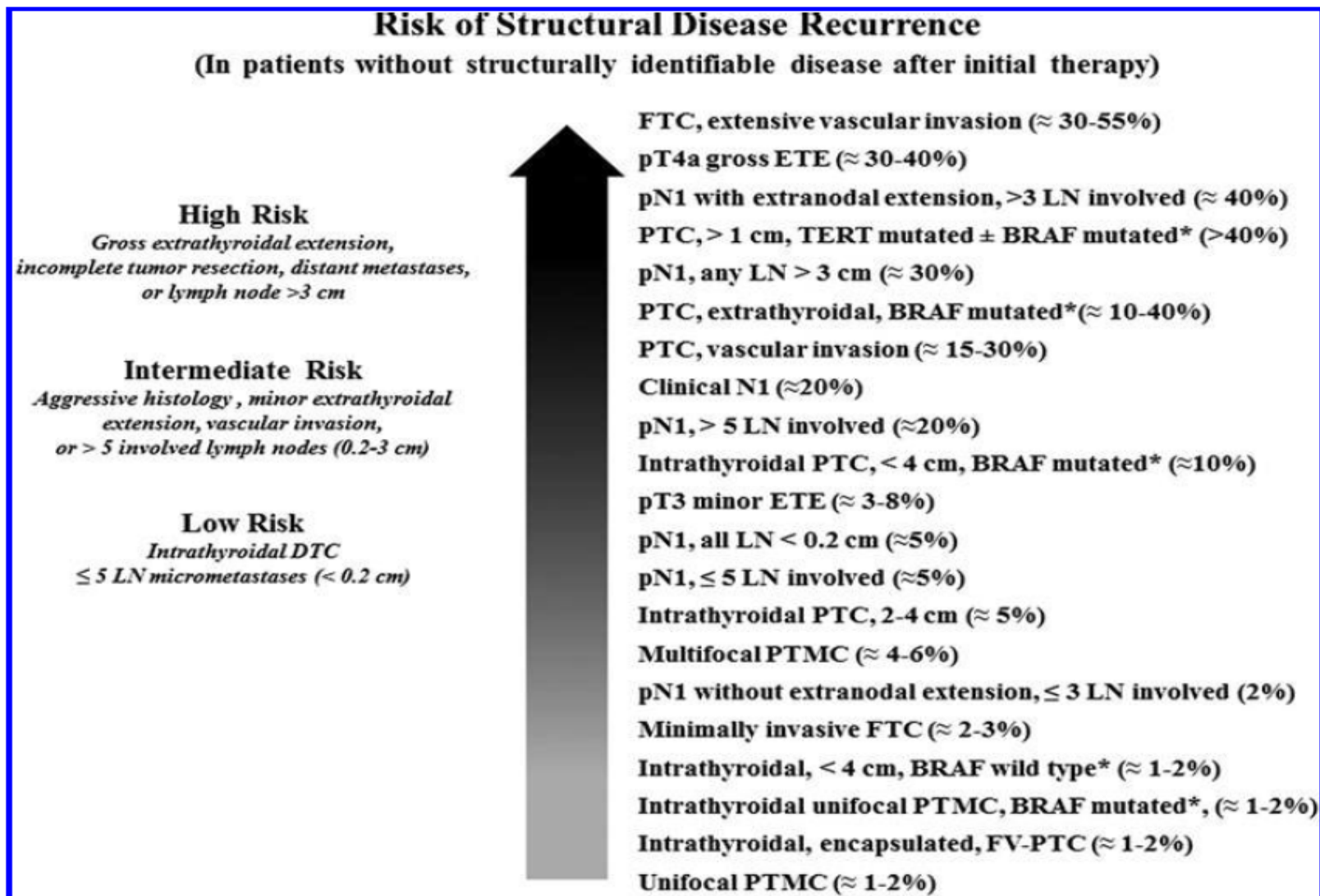


TABLE 11. ATA 2009 RISK STRATIFICATION SYSTEM WITH PROPOSED MODIFICATIONS

ATA low risk	<p>Papillary thyroid cancer (with all of the following):</p> <ul style="list-style-type: none"> • No local or distant metastases; • All macroscopic tumor has been resected • No tumor invasion of loco-regional tissues or structures • The tumor does not have aggressive histology (e.g., tall cell, hobnail variant, columnar cell carcinoma) • If ^{131}I is given, there are no RAI-avid metastatic foci outside the thyroid bed on the first posttreatment whole-body RAI scan • No vascular invasion • Clinical N0 or ≤ 5 pathologic N1 micrometastases (< 0.2 cm in largest dimension)^a <p>Intrathyroidal, encapsulated follicular variant of papillary thyroid cancer^a Intrathyroidal, well differentiated follicular thyroid cancer with capsular invasion and no or minimal (< 4 foci) vascular invasion^a Intrathyroidal, papillary microcarcinoma, unifocal or multifocal, including <i>BRAF</i>^{V600E} mutated (if known)^a</p>
ATA intermediate risk	<p>Microscopic invasion of tumor into the perithyroidal soft tissues RAI-avid metastatic foci in the neck on the first posttreatment whole-body RAI scan Aggressive histology (e.g., tall cell, hobnail variant, columnar cell carcinoma) Papillary thyroid cancer with vascular invasion Clinical N1 or > 5 pathologic N1 with all involved lymph nodes < 3 cm in largest dimension^a Multifocal papillary microcarcinoma with ETE and <i>BRAF</i>^{V600E} mutated (if known)^a</p>
ATA high risk	<p>Macroscopic invasion of tumor into the perithyroidal soft tissues (gross ETE) Incomplete tumor resection Distant metastases Postoperative serum thyroglobulin suggestive of distant metastases Pathologic N1 with any metastatic lymph node ≥ 3 cm in largest dimension^a Follicular thyroid cancer with extensive vascular invasion (> 4 foci of vascular invasion)^a</p>



ATA Initial Risk Stratification System





Indication to RAI Remnant Ablation



ATA low-risk

T1a-b, No-Nx, M0-Mx

Not generally recommended.

However, consideration of specific features could lead to consider the RAI remnant ablation in individual patients.

ATA intermediate or low-to-intermediate risk

T1-2, N1a-b, M0-Mx

Should be considered, particularly in patients with adverse features such as advanced age, larger tumors, macroscopic or clinically evident lymph nodes or presence of extranodal extension, or aggressive histology or vascular invasion.



Roma, 8-11 novembre 2018

Indication to RAI Remnant Ablation



ITALIAN CHAPTER

ATA high or intermediate-to-high risk

T3-4, any N, any M

RAI ablation is routinely recommended.

Tutti d'accordo?



Roma, 8-11 novembre 2018



ITALIAN CHAPTER

Eur J Nucl Med Mol Imaging
DOI 10.1007/s00259-016-3327-3



EDITORIAL

Why the European Association of Nuclear Medicine has declined to endorse the 2015 American Thyroid Association management guidelines for adult patients with thyroid nodules and differentiated thyroid cancer

Frederik A. Verburg¹ • Cumali Aktolun² • Arturo Chiti^{3,4} • Savvas Frangos⁵ •
Luca Giovanella⁶ • Martha Hoffmann⁷ • Ioannis Iakovou⁸ • Jasna Mihailovic⁹ •
Bernd J. Krause¹⁰ • Werner Langsteiger¹¹ • Markus Luster¹² • on behalf of the EANM
and the EANM Thyroid Committee

“There are currently **no prospective, controlled studies** available that precisely indicate **which patients with low-risk DTC may or may not benefit** from postoperative ¹³¹I therapy”.



INVITED PERSPECTIVE

Controversies on the Use of Radioiodine in Thyroid Cancer: We Need More and Better Data

Daniel A. Pryma

Division of Nuclear Medicine & Clinical Molecular Imaging, Department of Radiology, Perelman School of Medicine at the University of Pennsylvania, Philadelphia, Pennsylvania

- **There is a lack of randomized controlled trials**
- **More than 16 different staging systems are used to define “risk”**
- **Definition of “low risk” varies across studies**
- **Few studies include assessment of postoperative disease status**
- **Few data are specific to the “adjuvant treatment” cohort**
- **Histologic heterogeneity exists in differentiated thyroid cancer**
- **Likelihood of RAI avidity is not considered**
- **Event rates are often small**
- **Events can occur decades after diagnosis**
- **Preoperative imaging has improved over time**
- **Methods for detecting recurrent disease have improved over time**



Estimabl 2

- Studio francese di non inferiorità
- Pts. a basso rischio ATA
- Chirurgia + RAI vs. sola chirurgia
- Endpoint primario: DFS a 3 anni

IoN study

- Studio inglese di non inferiorità
- Pts. a basso rischio e a rischio intermedio ATA
- Chirurgia + RAI vs. sola chirurgia
- Endpoint primario: DFS a 5 anni



Item 10



Selection of the most appropriate activity of radioiodine for remnant ablation

- In patients with **low-risk or intermediate-risk** thyroid cancer, a low administered activity of radioiodine (**30-50 mCi**) for remnant ablation is generally favored being low activities as effective as high activities in obtaining complete ablation.



Roma, 8-11 novembre 2018

Item 10



ITALIAN CHAPTER

- Higher administered activities (**100 mCi or more**) should be considered for patients at **high risk** of persistent/recurrent disease, when the administration is intended in terms of **adjuvant therapy** or for patients submitted to **less than a total** or near-total **thyroidectomy**.




Roma, 8-11 novembre 2018



ITALIAN CHAPTER

Thank you for the attention





Roma, 8-11 novembre 2018

LG Italiane 2018 per il carcinoma differenziato tiroideo



Il follow-up



Roma, 8-11 novembre 2018

ONGOING RISK ASSESSMENT IN THYROID CANCER



ITALIAN CHAPTER

THYROID
Volume 20, Number 12, 2010
© Mary Ann Liebert, Inc.
DOI: 10.1089/thy.2010.0178

THYROID CANCER AND NODULES

Estimating Risk of Recurrence in Differentiated Thyroid Cancer After Total Thyroidectomy and Radioactive Iodine Remnant Ablation: Using Response to Therapy Variables to Modify the Initial Risk Estimates Predicted by the New American Thyroid Association Staging System

R. Michael Tuttle,¹ Hernan Tala,¹ Jatin Shah,² Rebecca Leboeuf,¹ Ronald Ghossein,³
Mithat Gonen,⁴ Matvey Brokhin,¹ Gal Omry,¹ James A. Fagin,¹ and Ashok Shaha²

The initial recurrence risk estimates should be modified to
incorporate the response to initial therapy

Risk estimates should be further modified during follow-up, as a
function of the clinical course of the disease



Roma, 8-11 novembre 2018

Teresa
Cytology TIR3B

Total thyroidectomy + 131I pT1N0



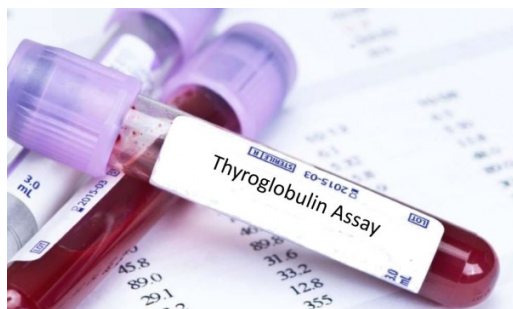ITALIAN CHAPTER

First follow up visit

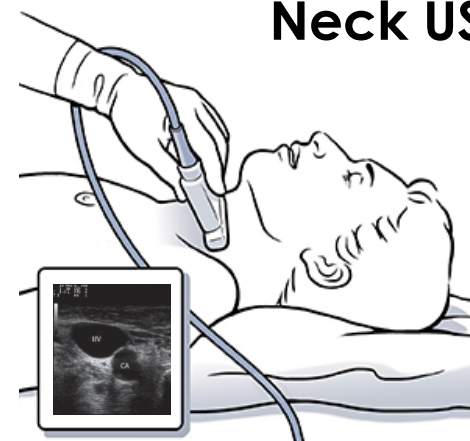


6-12 months after initial treatment
Evaluation of the RESPONSE

sensitive Tg or rhTSH
stimulated Tg + AbTg



Neck US





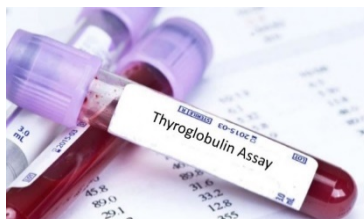Response to initial therapy



Excellent response

Basal Tg <0.2 ng/ml or rhTSH Tg <1 ng/ml

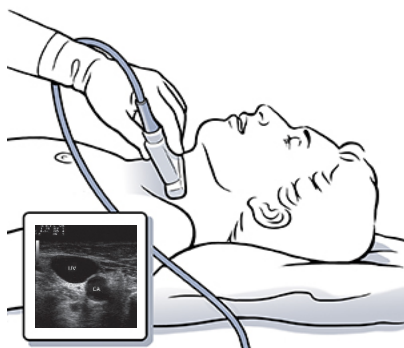
Negative or non-specific structural or functional imaging findings



Biochemical incomplete response

Detectable basal or stimulated Tg or rising anti-Tg antibody levels

Negative imaging



Structural incomplete response

Evidence of disease at structural or functional imaging, with any Tg level, with or without anti-Tg antibodies



Roma, 8-11 novembre 2018

Follow-up of patients with excellent response to initial therapy



ITALIAN CHAPTER



Excellent response

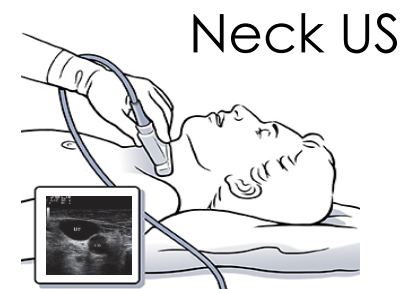
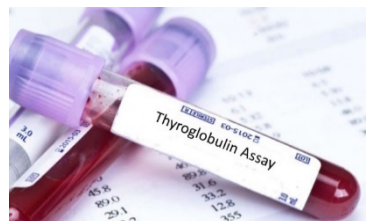Basal Tg <0.2 ng/ml or rhTSH Tg <1 ng/ml

Negative or non-specific structural or functional imaging findings

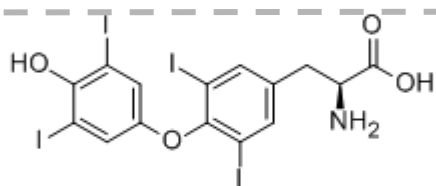


Follow up visits every 12-24 months

sensitive Tg (<0.2 ng/ml), Ab Tg on L-T4



Neck US



TSH levels in the low normal range → 0.5-2 mUI/L

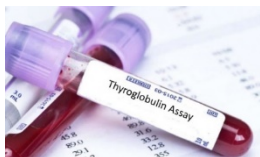

Roma, 8-11 novembre 2018

Follow-up of patients with persistent biochemical disease



ITALIAN CHAPTER



Biochemical incomplete response

Detectable basal or stimulated Tg or rising anti-Tg antibody levels

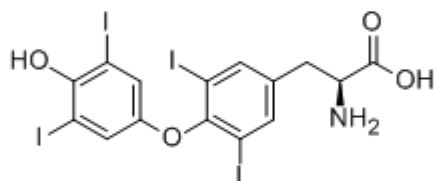
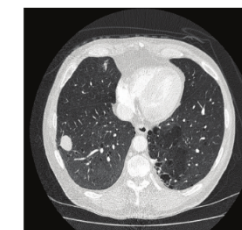
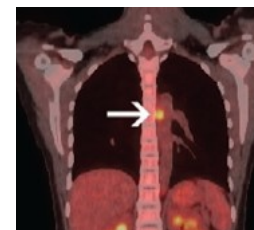Negative imaging



Follow up visits every 6-12 months

Tg doubling time <12 months

additional morphological examinations



**Moderate (0.1-0.5 mU/l) or complete (<0.1 mU/l)
TSH suppression**

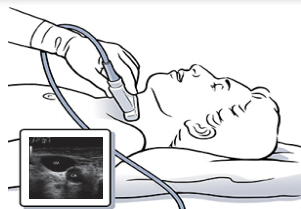


Roma, 8-11 novembre 2018

Follow-up evaluation after initial treatment (surgery + ^{131}I)

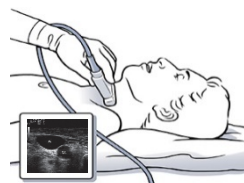


ITALIAN CHAPTER



Structural incomplete response

Evidence of disease at structural or functional imaging, with any Tg level, with or without anti-Tg antibodies



Suspicious neck lesions

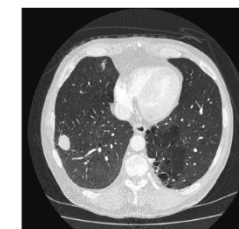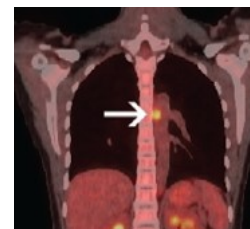patient at high risk of persistent disease

Functional (^{131}I WBS, ^{18}F FDG PET) and/or cross-sectional (CT, MR) imaging

surveillance

FNA cytology
FNATg

if FNA results would change the management





Roma, 8-11 novembre 2018

Follow-up of patients with persistent structural disease



ITALIAN CHAPTER

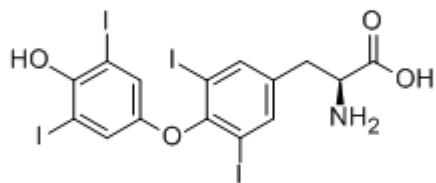
Tumors with low tumor burden, and/or small metastatic lymph-nodes can be followed without additional therapy



active surveillance and periodic morphological exams to assess the status of disease and to evaluate the need and the appropriateness of treatment

Localized or single metastases may require a local treatment (surgery/EBRT/other options)

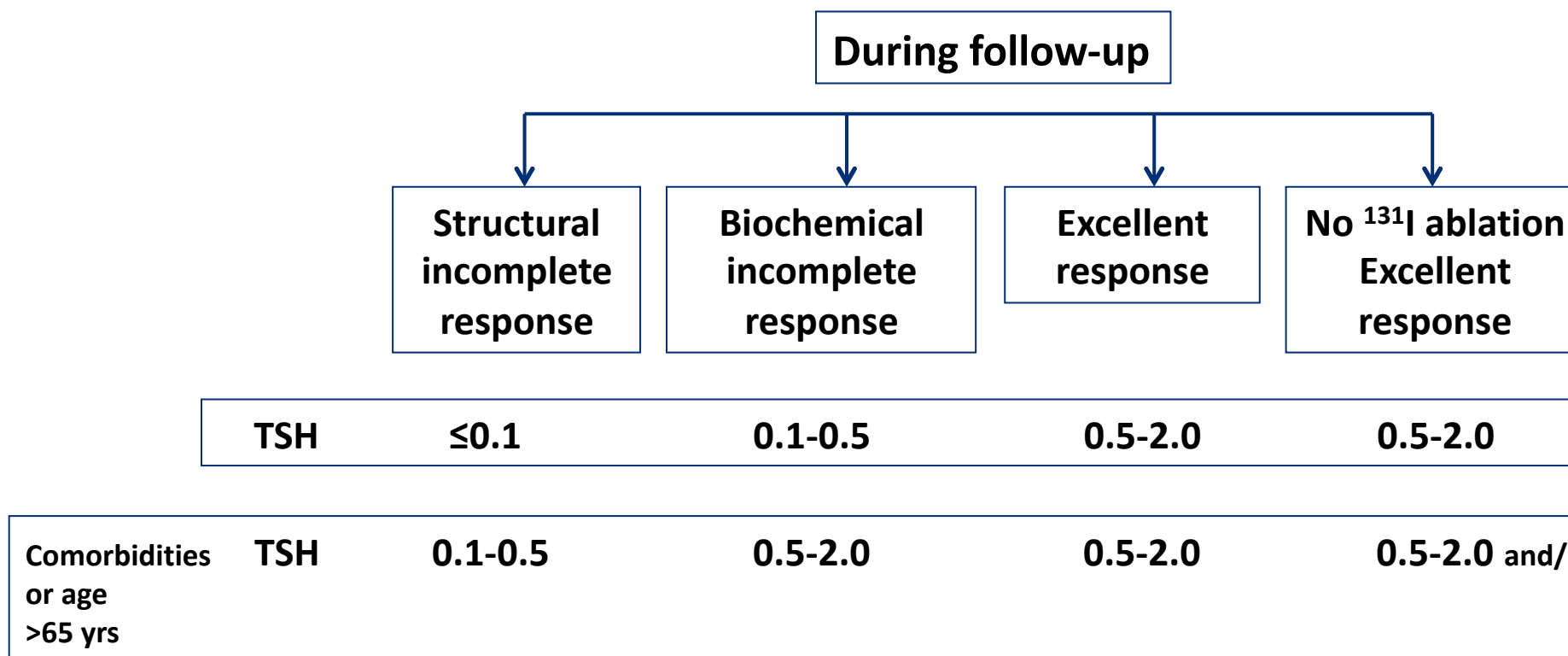
In patients with persistent disease after a cumulative activity of more than 600 mCi of ^{131}I , an alternative therapy (e.g. TKI) should be considered



TSH suppression (<0.1 mU/l)



Goal TSH levels during follow-up





Roma, 8-11 novembre 2018

Teresa
Cytology TIR3B

Total thyroidectomy + 131I pT1N0



ITALIAN CHAPTER



Follow up visit



2 years after surgery

Apparentemente guarita

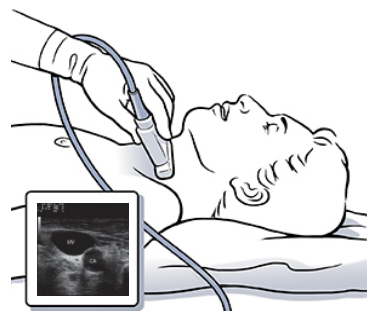
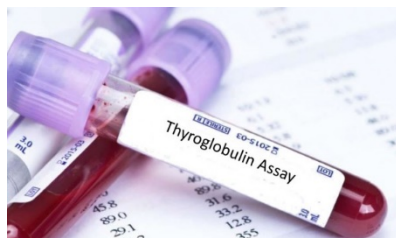Prossima visita:

6 mesi?

12 mesi?

18 mesi?

Undetectable Tg levels
Negative AbTg





Roma, 8-11 novembre 2018

Teresa

Total thyroidectomy + 131I pT1N0



ITALIAN CHAPTER

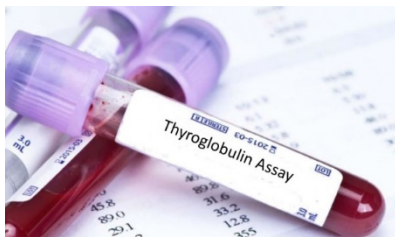

Follow up visit

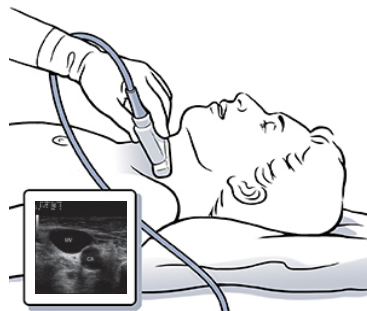


2 years after surgery

Undetectable Tg levels
Negative AbTg



Negative neck US



Apparentemente guarita
Prossima visita:
Centro di II livello?
Specialista?
MMG?



Roma, 8-11 novembre 2018

Giulia

Lobo-isthmectomy pT1N0



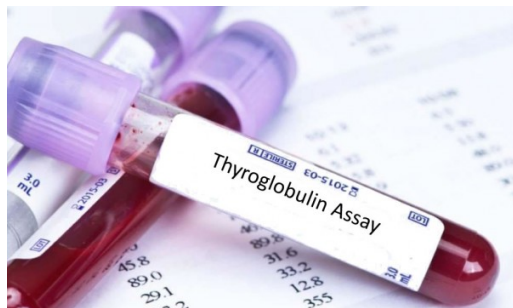ITALIAN CHAPTER

First follow up visit

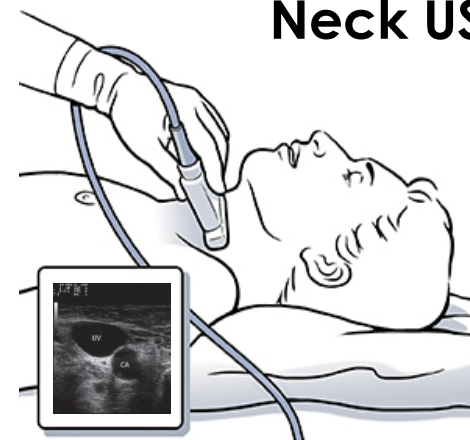


3-6 months after initial treatment
Evaluation of the RESPONSE
Then periodically

Tg and Ab Tg



Neck US





Lobo-isthmectomy pT1N0



Specific cut-off levels of Tg to distinguish normal residual thyroid tissue from persistent thyroid cancer are unknown

Table 1. Response to Therapy Assessment Definitions Based on Initial Therapy

	TT Without RAI Ablation	Lobectomy
Excellent response: No clinical, biochemical or structural evidence of disease	Nonstimulated Tg < 0.2 ng/mL or stimulated Tg < 2 ng/mL and undetectable TgAb and negative imaging	Stable, nonstimulated Tg < 30 ng/mL and undetectable TgAb and negative imaging
Biochemical incomplete response: Abnormally elevated serum Tg or increasing TgAb levels in the absence of localizable disease	Nonstimulated Tg > 5 ng/mL or stimulated Tg > 10 ng/mL or increasing Tg values over time with similar TSH levels or increasing TgAb levels and negative imaging	Nonstimulated Tg > 30 ng/mL or increasing Tg values over time with similar TSH levels or increasing TgAb levels and negative imaging
Structural incomplete response: Persistent or newly identified locoregional or distant metastases with or without abnormal Tg or TgAb	Structural or functional evidence of disease regardless of Tg or TgAb	Structural or functional evidence of disease regardless of Tg or TgAb
Indeterminate response: Nonspecific biochemical or structural findings which cannot be confidently classified as either benign or malignant	Nonspecific findings on imaging studies or faint uptake in thyroid bed on RAI scanning or nonstimulated Tg 0.2–5 ng/mL or stimulated Tg 2–10 ng/mL, or TgAb levels stable or declining in the absence of structural or functional disease	Nonspecific findings on imaging studies or TgAb levels stable or declining in the absence of structural or functional disease

Momesso et al., 2016

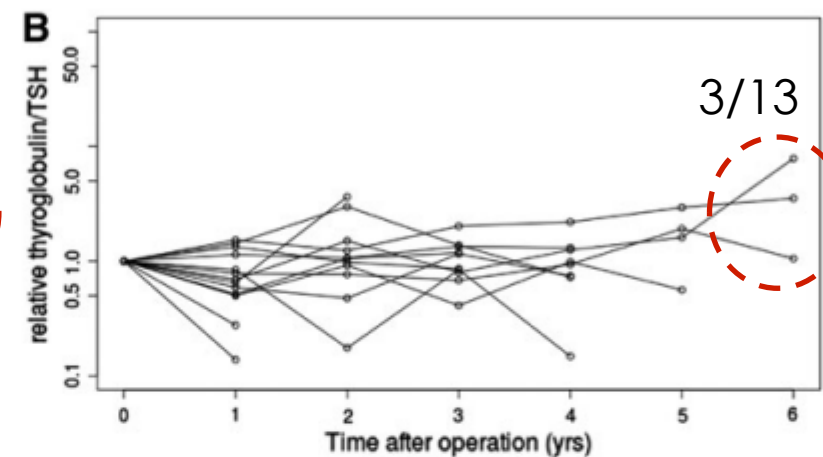
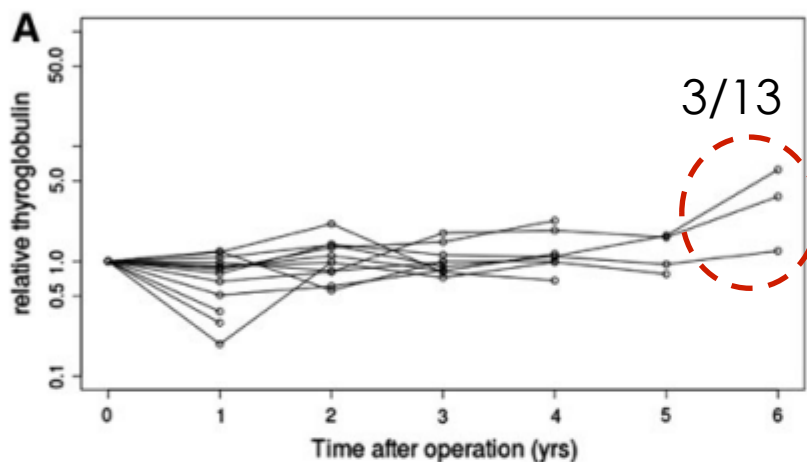
Rising non-stimulated Tg are the strongest predictor of recurrent/persistent structurally evident disease. The presence/absence and/or the trend of TgAb levels cannot be considered in the follow-up of patients submitted to lobectomy,



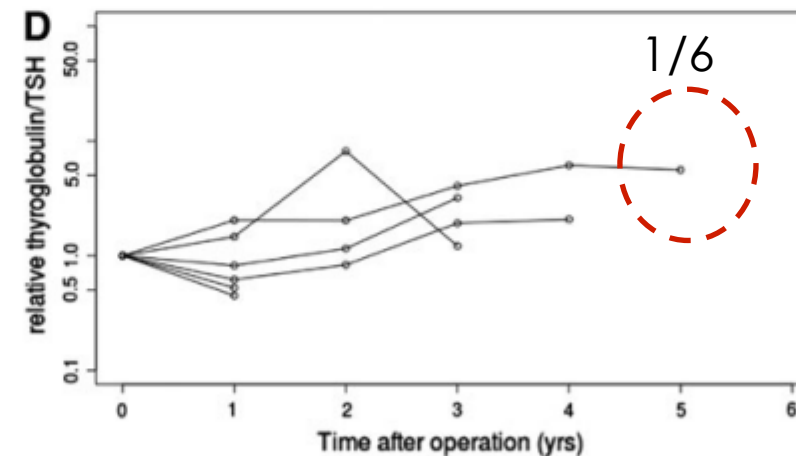
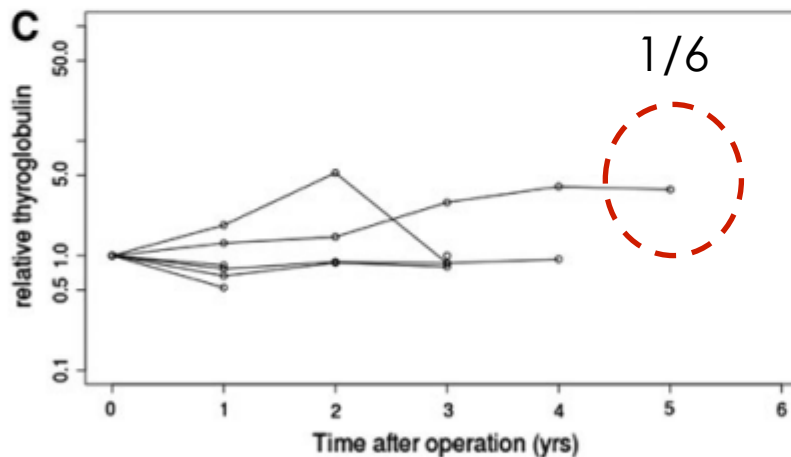
Tg and Tg/TSH levels after lobo-isthmectomy



contralateral lobe recurrences



recurrent disease in cervical LNs





Roma, 8-11 novembre 2018

Response to initial therapy

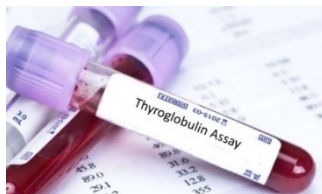

ITALIAN CHAPTER



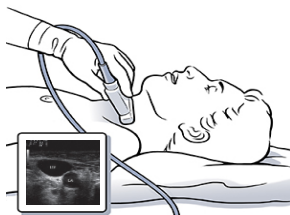
Excellent response

Low, stable basal Tg levels
Negative or non-specific structural or functional imaging findings



Biochemical incomplete response

Elevated non-stimulated Tg levels or Tg levels increasing over time
Negative imaging



Structural incomplete response

Evidence of disease at structural or functional imaging, regardless of serum Tg levels



Indeterminate response

Nonspecific findings on US and /or Tg trend not assessable, positive serum Tg Ab



[B43] Early management of DTC after initial therapy

[B44] What is the appropriate degree of initial TSH suppression?

■ **RECOMMENDATION 59**

E) For low risk patients who have undergone lobectomy, TSH may be maintained in the mid to lower reference range (0.5 – 2 mU/L) while continuing surveillance for recurrence.

Thyroid hormone therapy may not be needed if patients can maintain their serum TSH in this target range. (**Weak recommendation, Low-quality evidence**)

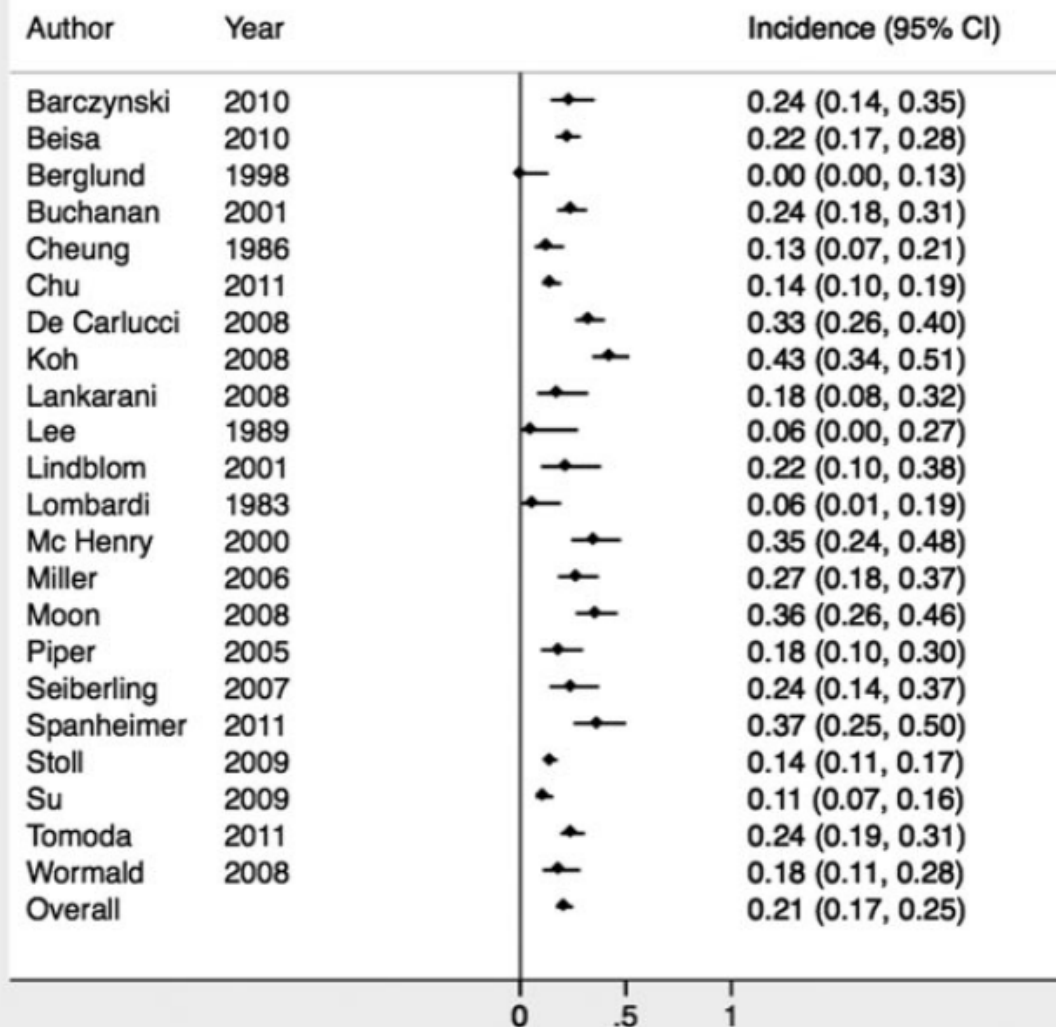


Roma, 8-11 novembre 2018

One in five patients will develop hypothyroidism after hemithyroidectomy

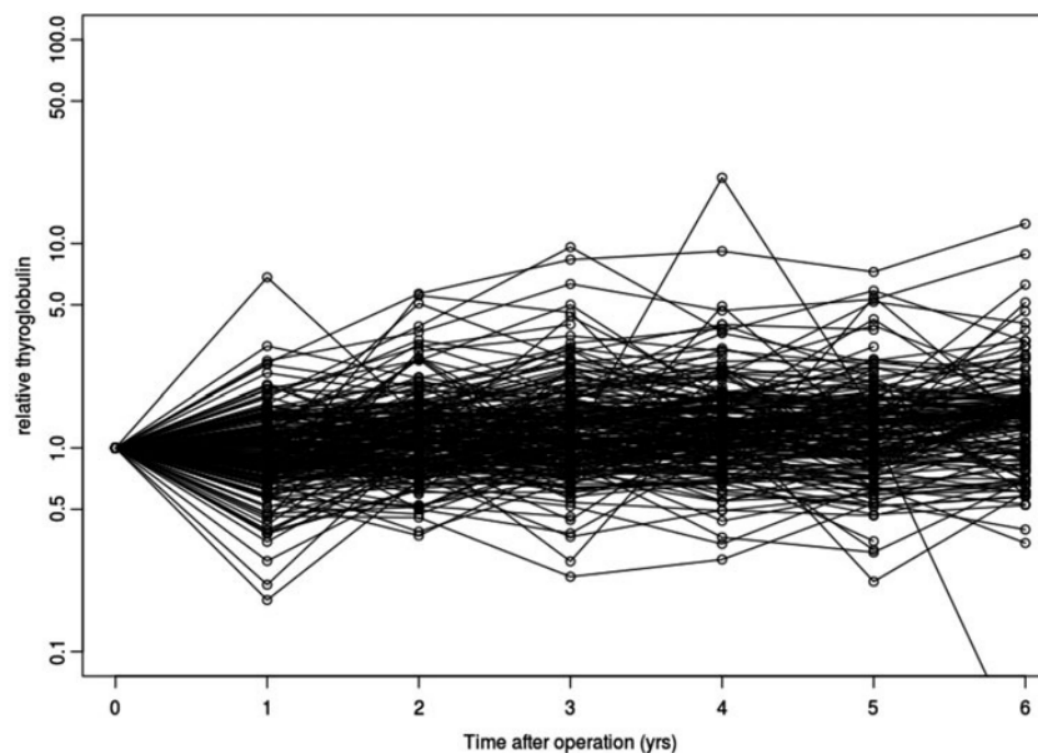


ITALIAN CHAPTER





Patients with TSH levels in the reference range (0.4–4.5 mIU/L) without thyroid hormone replacement therapy, after lobectomy



serum Tg levels increased about 10% annually ($p < 0.001$)



Italian consensus on diagnosis and treatment of differentiated thyroid cancer: joint statements of six Italian societies

F. Pacini¹ · F. Basolo² · R. Bellantone³ · G. Boni⁴ · M. A. Cannizzaro⁵ · M. De Palma⁶ · C. Durante⁷ · R. Elisei⁸ · G. Fadda⁹ · A. Frasoldati¹⁰ · L. Fugazzola^{11,12} · R. Guglielmi¹³ · C. P. Lombardi³ · P. Miccoli² · E. Papini¹³ · G. Pellegriti¹⁴ · L. Pezzullo¹⁵ · A. Pontecorvi¹⁶ · M. Salvatori¹⁷ · E. Seregni¹⁸ · P. Vitti⁸

Item 23: L-Thyroxine therapy after total thyroidectomy or lobo-isthmectomy

Recommendation statement

Degree of TSH suppression after initial treatment

The degree of initial TSH suppression depends on the risk classification after initial treatment. Age and comorbidities should also be considered.

Degree of TSH suppression during follow-up [1]

The degree of TSH suppression depends on the ongoing risk classification. Age and comorbidities should also be considered.

Note: In patients treated by lobectomy and living in an iodine deficient country, L-thyroxine treatment may be considered to reduce the TSH-induced thyroid nodular hyperplasia of the residual lobe, considering, age, TSH levels and ultrasound feature of the remaining lobe.



Roma, 8-11 novembre 2018

LG Italiane 2018 per il carcinoma differenziato tiroideo



ITALIAN CHAPTER



THMs



Roma, 8-11 novembre 2018

The time of “one treatment fits all” has definitely come and gone



ITALIAN CHAPTER





Roma, 8-11 novembre 2018

La gestione del carcinoma tiroideo differenziato nel 2018: THMs



ITALIAN CHAPTER



- L'obiettivo delle linee guida ATA 2015 è stato quello di contrastare overdiagnosis e overtreatment. Non mancano tuttavia segnali di una possibile oscillazione del pendolo in una direzione opposta nei prossimi anni.
- È certamente necessario sottolineare l'importanza della chirurgia conservativa e considerare l'opzione della "sorveglianza attiva" in casi selezionati di pazienti con PMC; dobbiamo al tempo stesso essere consapevoli che una quota non trascurabile dei nostri pazienti potrebbe avere beneficio dalla tiroidectomia totale e dalla successiva terapia ablativa.
- Abbiamo bisogno di maggiori dati sulla rilevanza prognostica dei marcatori molecolari ed istologici per migliorare l'accuratezza delle nostre decisioni cliniche.



Roma, 8-11 novembre 2018

Active surveillance for PTMC: Italian consensus statement



ITALIAN CHAPTER



Recommendation statement

- (a) Even if surgery is the treatment of choice, “no immediate intervention” and active surveillance may be considered for very low-risk PTMC in the following setting:
1. patients at high surgical risk;
 2. patients who refuse surgical treatment;
 3. patients willing to enter into controlled clinical trials.
- (b) A personal decision making is recommended as well as an accurate discussion with the patient to explain pro and cons of the active surveillance vs. surgical treatment.
- (c) A careful clinical and cytological evaluation of risk factors for aggressive behavior or recurrence of PTMC is recommended.



Roma, 8-11 novembre 2018

PMTC candidate to active surveillance



ITALIAN CHAPTER



- **Ideal candidate:** an older patient with a solitary PMC with well-defined nodule margins, not adjacent to the thyroid capsule and confined to the thyroid parenchyma.
- **Appropriate candidate:** younger patients with multifocal disease, adjacent to the thyroid capsule at noncritical locations, a potentially more aggressive molecular phenotype, or other US findings likely to make follow-up more difficult (thyroiditis, nonspecific lymphadenopathy, or other benign-appearing nodules).
- **Inappropriate candidate:** patients with tumors in critical subcapsular locations (adjacent to the recurrent laryngeal nerve or trachea), and evidence of spread outside the thyroid by either direct extension or metastases, or evidence of disease progression.

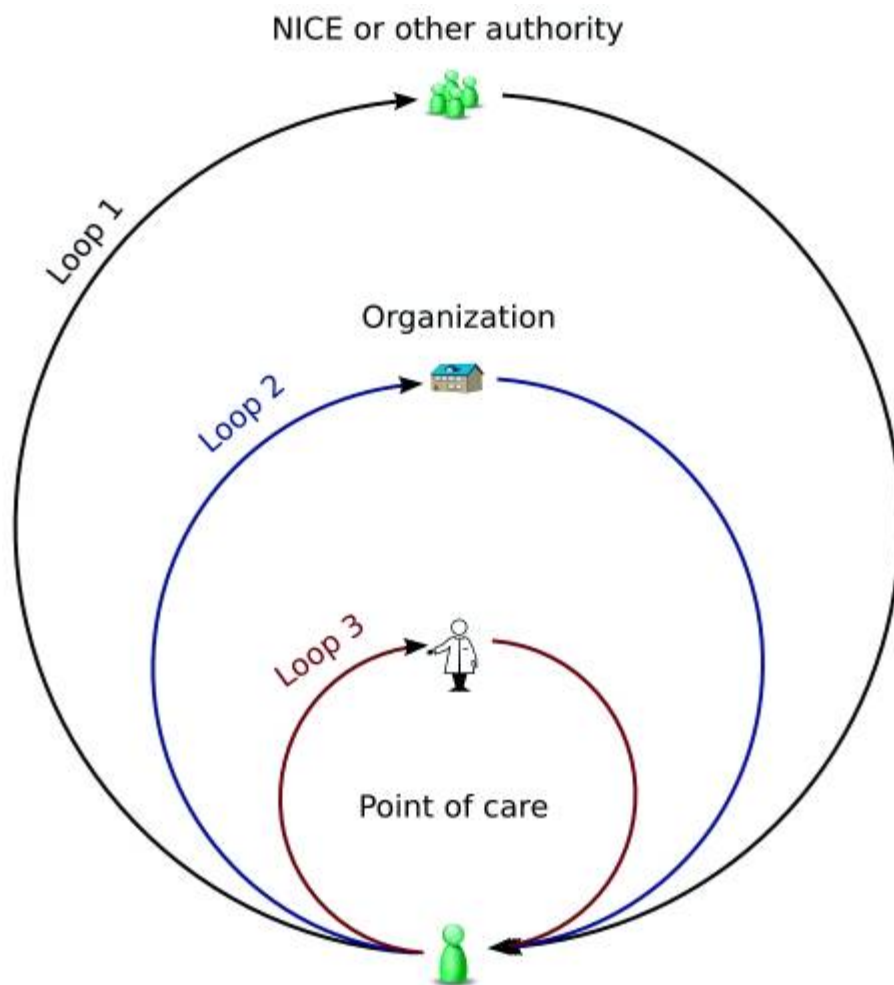


Roma, 8-11 novembre 2018

From practice guidelines to clinical decision support: closing the loop



ITALIAN CHAPTER



I PDTA rappresentano l'adattamento delle raccomandazioni delle LG al contesto locale definendo:

- **procedure (*how*)**
- **professionisti (*who*)**
- **setting (*where*)**
- **tempistiche (*when*)**

Fox et al. J R Soc Med 2009: 102: 464–473.



Roma, 8-11 novembre 2018

Grazie per la vostra attenzione!



ITALIAN CHAPTER



Nadir Bonazzi fotografia