



Roma, 9-12 novembre 2017

# Patient 1: Inapparent

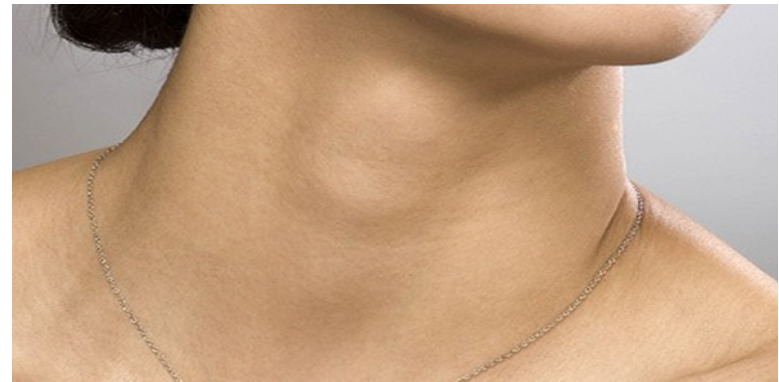
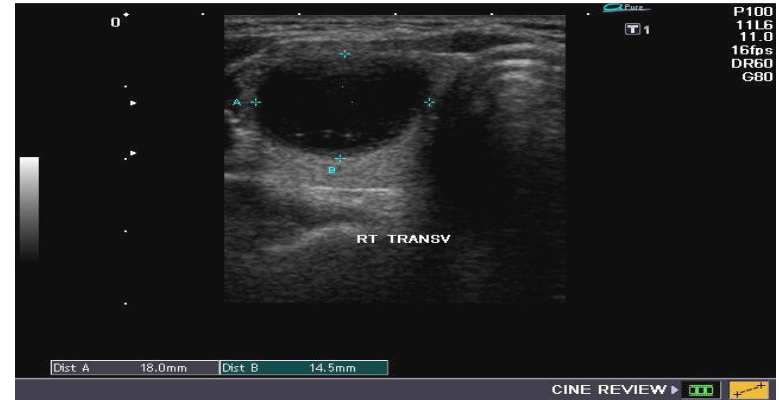
ITALIAN CHAPTER

Daniela V, 35 years  
Ill-defined local pressure symptoms (?)

Neck US : «Cystic lesion,  
18 x 14 x 16 mm, right thyroid lobe»

TSH 2.1 (0.2 – 4.0 mU/L)  
TPOAb 11 (< 35 U/mL)





# What is your current approach?

- Follow-up
- UG-FNA
- Medical treatment
- PEI
- Thermoablation
- 131-I
- Surgery



Roma, 9-12 novembre 2011



ITALIAN CHAPTER

# Patient 2 (the same one, after 1 year)

Daniela V, 36 years

One year ago, percutaneous drainage : «Thy 1C»

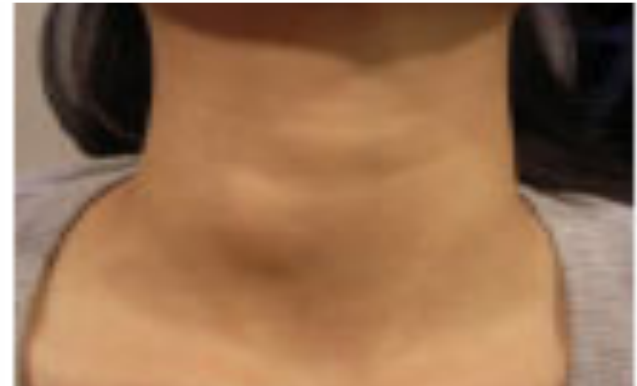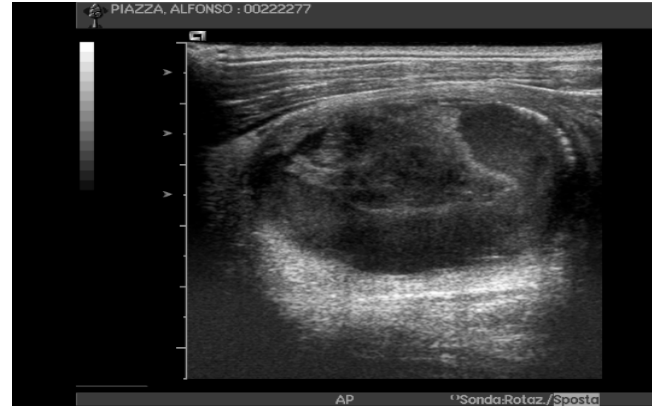
Nearly asymptomatic until one month ago, then cervical pain and dysphagia.

Thyroid US:

«Cystic lesion, 27 x 23 x 29 mm, right thyroid lobe»

TSH 2.0 (0.2 – 4.0 mU/L)

TPOAb 14 (< 35 U/mL)





# What is your current approach?

- Follow-up
- UG-FNA
- Medical treatment
- PEI
- Thermoablation
- 131-I
- Surgery



Roma, 9-12 novembre 2017

# Patient 3: «the busy one»



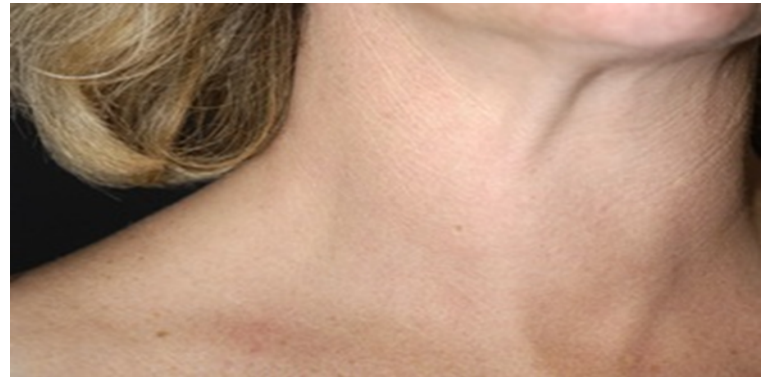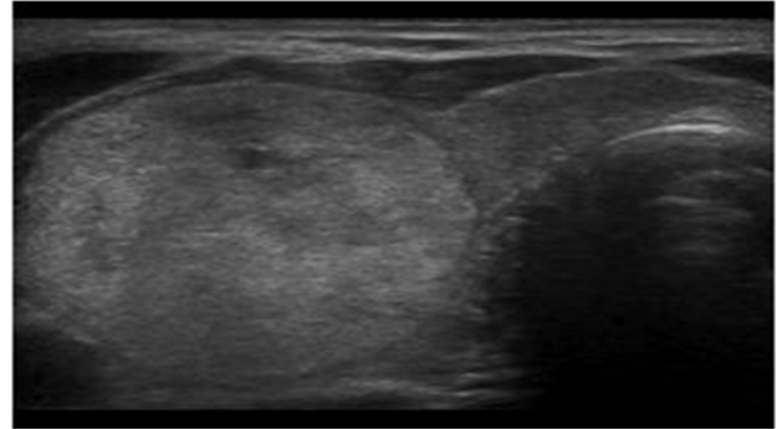
ITALIAN CHAPTER

Giovanna S, 56 years  
Thyroid nodule since 5 years.  
Previous exam (2011): nodule 32 x 29 x 30 mm right lobe

No medical treatment  
Slight pressure symptoms

US: «isoechoic nodule with halo, right thyroid lobe, 40 x 34 x 35 mm».

UG-FNA: «TIR 2»  
TSH 0.95 (0.20 – 4.0 mU/L).





# What is your current approach?

- Follow-up
- UG-FNA
- Medical treatment
- PEI
- Thermoablation
- 131-I
- Surgery



Roma, 9-12 novembre 2017

# Patient 4: the «patient by chance»

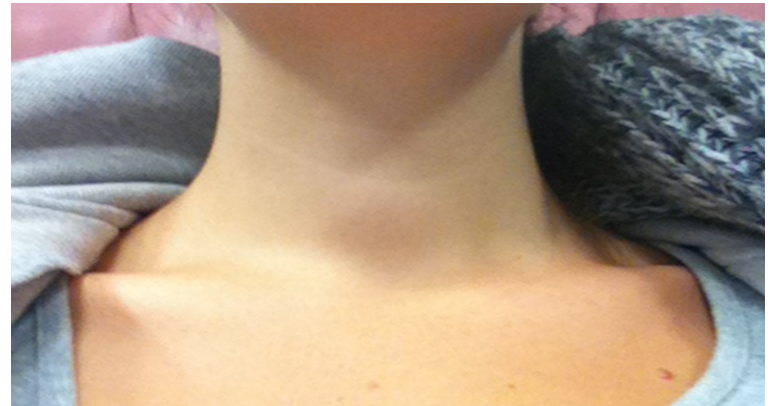
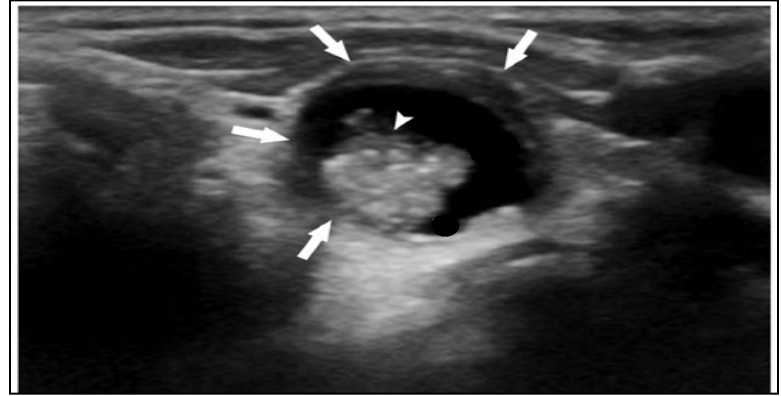
ITALIAN CHAPTER

Katia G, 17 years  
Small cervical lump (observed while she was making up)  
No neck pain  
The father pushed her to the doctor.

Thyroid US:  
«Cystic lesion, 13 x 12 x 13 mm, right lobe, an internal hub»

TSH 2.4 (0.2 – 4.0 mU/L)  
TPOAb 52 (< 35 U/L).





# What is your current approach?

- Follow-up
- UG-FNA
- Medical treatment
- PEI
- Thermoablation
- 131-I
- Surgery





Roma, 9-12 novembre 2017

# Patient 5: «glad for her weight»

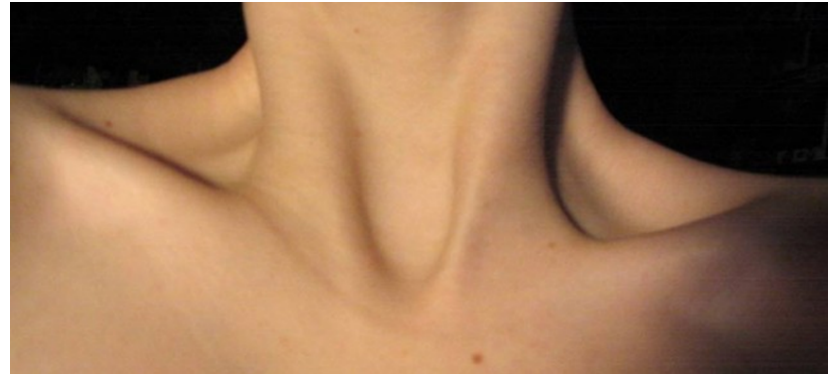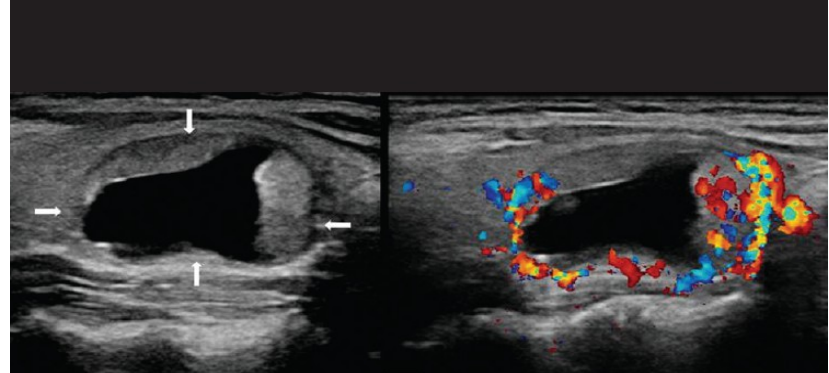


ITALIAN CHAPTER



Rebecca F, 29 years  
Excellent weight loss with hypocaloric diet.  
Occasionally, accelerated heart rate.  
No cervical complaints.

Thyroid US:  
«Partially cystic lesion, 13 x 9 x 12 mm, right lobe; strong vascular signals»  
TSH 0.05 (0.2 – 4.0 mU/L)  
FT4 17.5 (5 – 18 ng/mL).





# What is your current approach?

- Follow-up
- UG-FNA
- Medical treatment
- PEI
- Thermoablation
- 131-I
- Surgery



Roma, 9-12 novembre 2017

# Patient 6: «quite inattentive»



ITALIAN CHAPTER

Giovanni G, 36 years

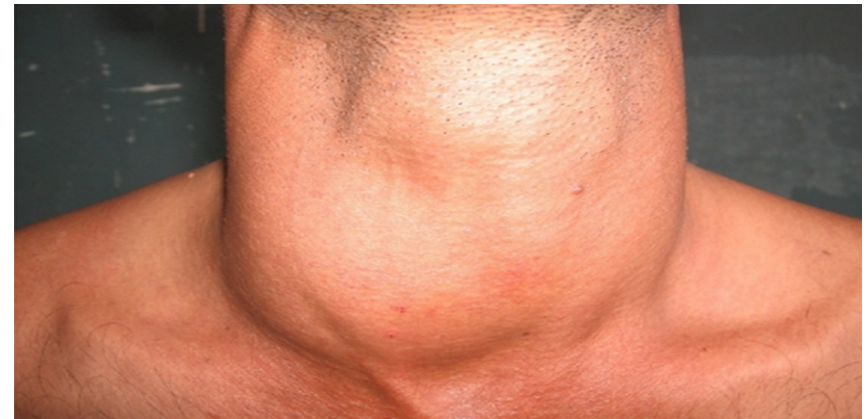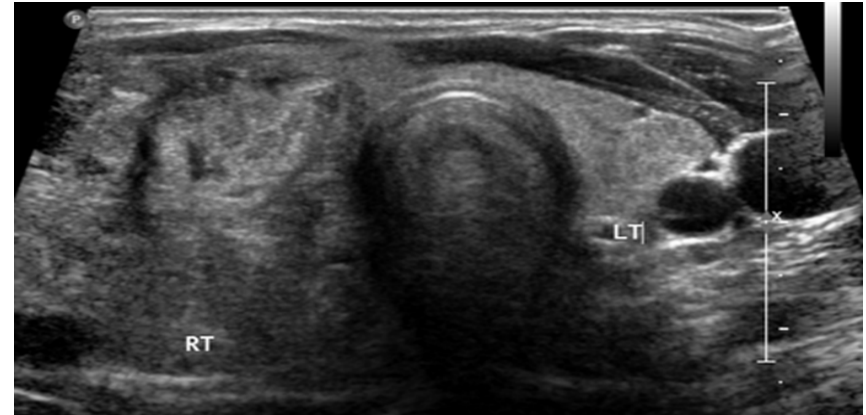
Thyroid «problems» since year 2005

Local pressure symptoms since 2015,  
but «he did not care».

US: «inhomogeneous nodule, right  
thyroid lobe, 50 x 31 x 38 mm».

UG-FNA: «Thy 2»

TSH 0.65 (0.20 – 4.0 mU/L).





# What is your current approach?

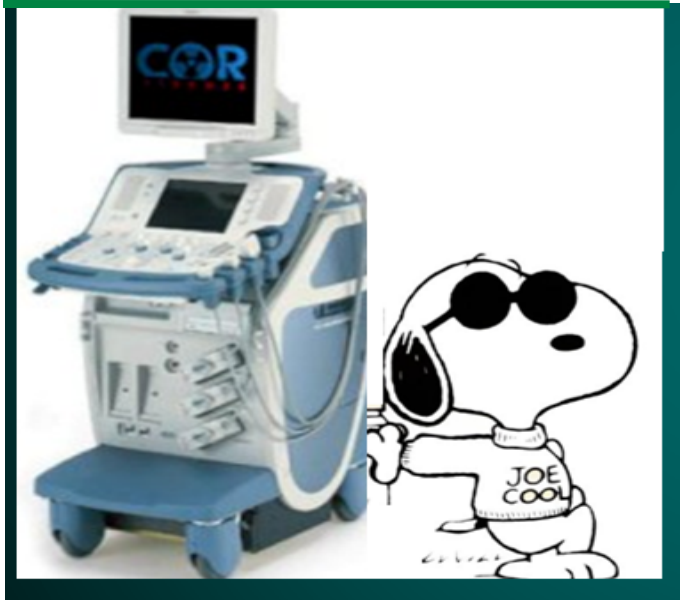- Follow-up
- UG-FNA
- Medical treatment
- PEI
- Thermoablation
- 131-I
- Surgery



Roma, 9-12 novembre 2017



ITALIAN CHAPTER



**Thank You-  
Ready for  
Comments**



Roma, 9-12 novembre 2017



ITALIAN CHAPTER



**Take Care:  
Complications are  
rare but may be  
relevant**

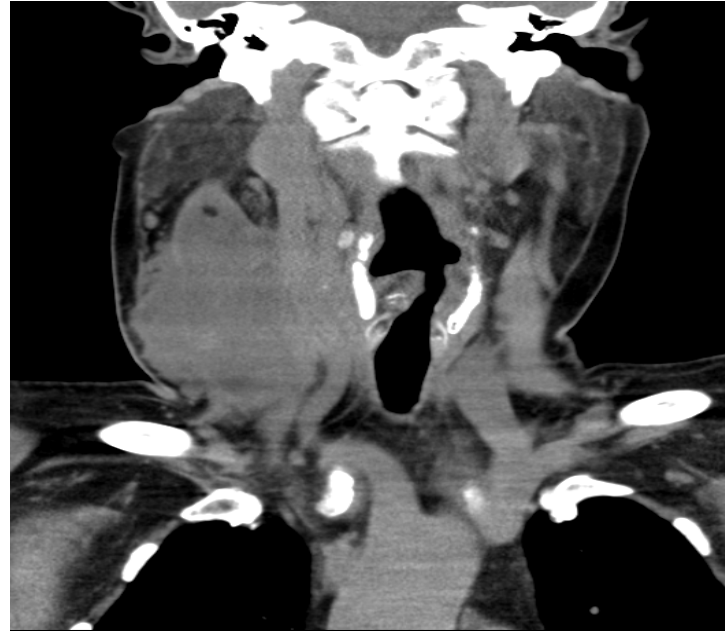
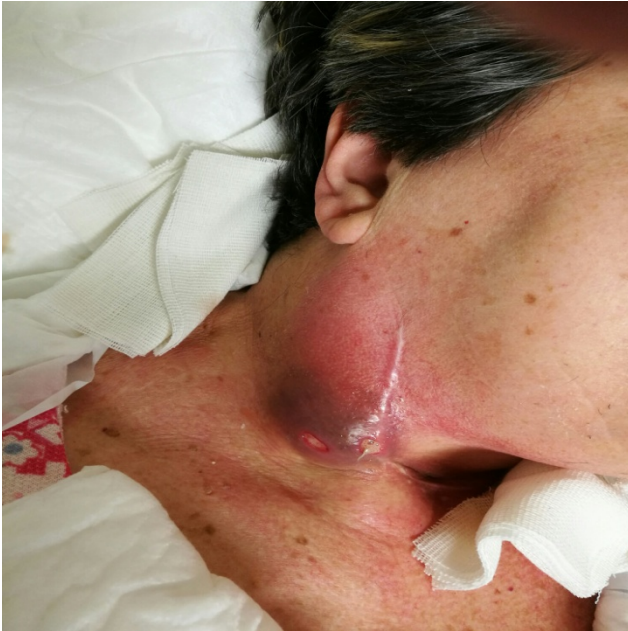# COMPLICATIONS OF LAT FOR UNRESECTABLE CANCER



ITALIAN CHAPTER



Roma, 9-12 novembre 2017



Neck abscess treated with drainage and parenteral antibiotics

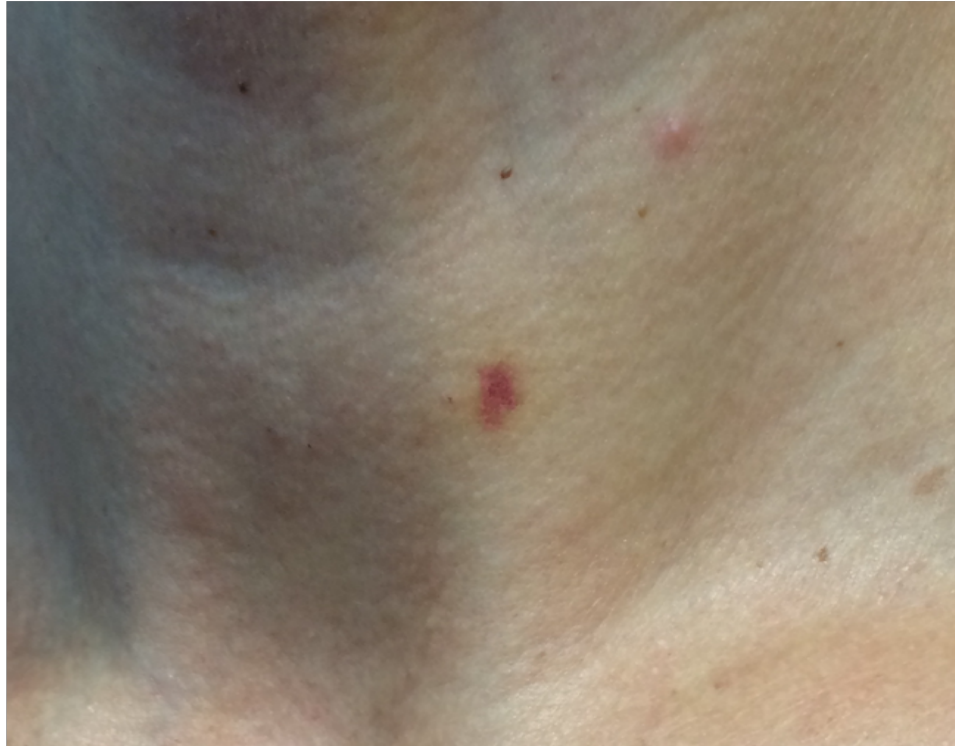

Roma, 9-12 novembre 2017

# Skin burn after RFA



ITALIAN CHAPTER







# HIFU Complications



ITALIAN CHAPTER

Roma, 9-12 novembre 2017

**Same patient after 24 hours: large area of oedema of soft tissues of the neck**

